

## CORRELATION OF THE INITIAL BONE HEIGHT TO THE MIDDLE FACIAL HEIGHT AND THE MAXILLARY SINUS VOLUME: A RETROSPECTIVE STUDY

Mark Bou Chaaya<sup>1</sup> | Gabriel Menassa<sup>2</sup> | Nabil Ghosn<sup>3</sup> | Joyce Nicolas<sup>1</sup> | Nada Naaman<sup>1,4</sup>

**Abstract:** This study aims to measure and establish a correlation between the initial bone height (IBH) at the dentate posterior maxillary sextants to the middle facial height (MFH) and the maxillary sinus volume (SV). Thirty CBCTs split evenly between males and females were retrospectively selected and processed to measure the SV and the IBH from the first premolar to the second molar. A clinical measurement was performed on each patient to evaluate the MFH. A significant positive correlation was found between MFH and SV. No significant correlation was found between the IBH of the first premolar and the SV or MFH on both sides. The results showed a significant negative correlation between the IBH of the other teeth examined and the SV on both sides. A significant negative correlation was found between the MFH and the IBH of the second premolar, first molar, and second molar of each side. It can be concluded that the maxillary SV increases with the MFH, and the IBH decreases when the SV and the MFH increase except for the first premolar. The clinical relevance of this study lies in the capability of the general practitioner to estimate the IBH in the posterior dentate maxilla by measuring the MFH. Patients with a risk of having a low IBH can be advised, in the case of an extracted tooth, to consider ridge preservation techniques or implant therapy as soon as possible to avoid future complex surgical interventions.

**Keywords:** CBCT, initial bone height, middle facial height, sinus volume

---

**Corresponding Author:**

Mark Abou Chaya. E-mail: bouchaaya.mark@gmail.com

**Conflicts of interest:**

The authors declare no conflicts of interest.

1- Department of Periodontology, Faculty of Dental Medicine, Saint Joseph University, Beirut Lebanon. Rue de Damas B.P. 11-5076 - Riad El Solh Beyrouth 1107 2180.

2- Head of Department of Periodontology, Faculty of Dental Medicine, Saint Joseph University, Beirut Lebanon. Rue de Damas B.P. 11-5076 - Riad El Solh Beyrouth 1107 2180.

3- Department of Radiology, Faculty of Dental Medicine, Saint Joseph University, Beirut Lebanon. Rue de Damas B.P. 11-5076 - Riad El Solh Beyrouth 1107 2180.

4- Dean, College of Dentistry, American University of Iraq-Baghdad. Airport Road, Baghdad-Iraq, Building Number 43

bouchaaya.mark@gmail.com

menassag@gmail.com

nabilghosn@gmail.com

joyce.j.nicolas@gmail.com

nadanaaman@gmail.com

## ***CORRÉLATION DE LA HAUTEUR OSSEUSE INITIALE, À LA HAUTEUR DE L'ÉTAGE FACIAL MOYEN ET AU VOLUME DU SINUS MAXILLAIRE: UNE ÉTUDE RÉTROSPECTIVE***

### **Résumé**

Le but de cette étude est de mesurer et d'établir une corrélation entre la hauteur osseuse initiale (HOI) au niveau des sextants maxillaires postérieurs dentés, la hauteur de l'étage moyen de la face (HEM) et le volume du sinus maxillaire (VS). Trente CBCTs (15 mâles et 15 femelles) ont été rétrospectivement sélectionnés et analysés afin de mesurer le VS et la HOI allant de la première prémolaire jusqu'à la deuxième molaire. Une mesure clinique a été réalisée sur chaque patient afin d'évaluer la HEM. Une corrélation positive et significative a été trouvée entre HEM et VS. La corrélation entre la HOI de la première prémolaire et le VS et la HEM n'était pas significative pour les deux côtés. Les résultats ont démontré une corrélation négative et significative entre la HOI des autres dents examinées et le VS des deux côtés. En plus, la corrélation négative entre la HOI de ces dernières et la HEM était statistiquement significative. En conclusion, le VS augmente avec le HEM et la HOI diminue (à l'exception de la première prémolaire) quand le VS et la HEM augmentent. Cette étude a été réalisée pour que l'omnipraticien soit capable d'estimer la HOI au maxillaire postérieur en mesurant la HEM. Par conséquent, les patients avec un risque élevé d'avoir une HOI diminuée, peuvent être conseillés d'avoir une des techniques de préservation de crêtes après une extraction d'une dent au maxillaire postérieur, ou de la remplacer par un implant le plus tôt possible afin d'éviter des interventions chirurgicales complexes au futur.

**Mots-clés:** CBCT, hauteur osseuse initiale, étage facial moyen, volume sinusien.

## Introduction

For a long time, tooth loss was a major issue for most patients, as it might affect the masticatory function and esthetics. With the beginning of modern dentistry, replacing missing teeth was strictly prosthetic using fixed or removable dentures. Following the introduction of the osseointegration concept of titanium implants, a wider diversity of therapeutic solutions was available to treat different clinical cases. Nevertheless, vertical and horizontal bone resorption always occurs after teeth extraction due to a remodeling process [1,2]. Healing of the extraction sockets is usually uneventful. Consequently, the alveolar defect will only be partially restored. A systematic review showed that after extraction, the alveolar ridges undergo a reduction of 3.79 mm in width and 1.24 mm in height at 6 months [3]. The greatest amount of bone loss occurs mainly in the facial aspect of the horizontal dimension of the ridge. Also, the vertical ridge height loss is more pronounced on the buccal aspect. As a result, the residual ridge is narrower and shorter with a relocation to a more palatal position.

Furthermore, after tooth extraction in the posterior sextants of the maxilla, bone height loss is associated with maxillary sinus pneumatization (a normal physiologic process that results in an increase in sinus volume over time). According to Wolff's law, this type of atrophy takes place and is intensified by positive air pressure in the sinus cavity [4]. Farina et al. showed in a comparative study between dentate and edentulous sites a maxillary sinus floor apical displacement of 0.8, 2.5, 1.5, and 1.3 mm of the inferior sinus border at the first premolar, second premolar, first molar, and second molar sites respectively. Thus, sinus pneumatization may account for up to 46 % of the variation in the residual bone height after extraction in the posterior maxilla [5]. This process may further decrease the total volume of available bone necessary

for implant placement.

Many edentulous patients may require bone regeneration techniques in the posterior maxilla to make the implant therapy possible and reach satisfactory outcomes. A broad spectrum of surgical solutions is now available to regenerate the proper amount of bone necessary for implant placement. These procedures range from guided bone regeneration to sinus floor elevation and block grafting [6–11] graft consolidation requires adequate angiogenesis and migration of cells involved in osteogenesis and bone remodeling. It is speculated that these biologic events are greatly determined by the dimensions of the maxillary sinus cavity. Hence, the purpose of this study is to assess the influence of the distance from the lateral to the medial wall of the maxillary sinus on the outcomes of sinus augmentation procedures.

**METHODS:** A total of 25 patients in need of sinus augmentation were recruited for the study. After initial examination, customized radiographic and surgical guides were fabricated and a cone-beam computerized tomography scan was obtained per patient. The bucco-palatal distance (BPD). On the other hand, all of these solutions are often associated with a variable rate of complications, prolonged therapy time, increased morbidity, and high costs [12–14] diameter, and location of the PSA and its relationship to the alveolar ridge and to study the prevalence of the sinus pathology and septum using computerized tomography (CT).

This study aims to establish a correlation between:

1. The middle facial height (MFH, distance between the glabella and the sub-nasal point) and the maxillary sinus volume (SV).
2. The maxillary sinus volume (SV) and the initial bone height (IBH, distance between the sinus floor and the alveolar crest).
3. The middle facial height (MFH) and the initial bone height (IBH).

To our knowledge, this is the first study to establish these correlations using soft tissue landmarks to measure the MFH.

We hypothesize that the maxillary SV increases with the MFH, the IBH decreases when the maxillary SV increases, and the IBH decreases when the MFH increases. Once this hypothesis is confirmed, the general practitioner can estimate the initial bone height in the posterior maxilla by measuring the middle facial height of the patient. Thus, a patient having higher dimensions of the MFH should consider ridge preservation techniques or implant therapy as soon as possible, in case of an extracted tooth at the maxillary posterior sextants, to avoid future complex grafting procedures due to a lower IBH.

## Materials and methods

The study protocol was approved by the "Ethics Committee" (2017 - 46).

### Study design and population

The patients were retrospectively selected among those referred for a cone beam computed tomography (CBCT) to the Faculty of dental medicine at Saint Joseph University of Beirut, Lebanon. All the scans were acquired with NewTom™ VGi (Silvestrini, Verona, Italy) according to the following protocol: a pitch of 1:1, a focal spot of 0.3 mm, a field of view of 15 x 15 cm, and an effective radiation dose of 99 micro Sv. The CBCTs were post-processed with NNT viewer™ (NewTom, Verona, Italy) software. When more than one data was found for the same patient, the most recent one was selected. As a result, each patient provided one CBCT on which the volumetric and linear measurements were taken on both the right and left sides. Clinical measurements were then taken to evaluate the MFH.

A total of 1200 CBCTs were screened from the database of the radiology department from January 2013 to July 2018 to obtain 30

CBCTs split evenly between males and females. To be included in the study, every patient must have the following inclusion criteria:

- Middle Eastern Caucasian.
- Dentate sextants in the posterior maxilla (from the first premolar to the second molar).
- All patients had to be between 20 and 30 years old.

Any patient having one or more of the following criteria was excluded from the analysis:

- Periodontal disease.
- Endodontic or periapical lesions in the posterior maxilla.
- Maxillary sinus disease: any patient having radiographic evidence of pathologic membrane thickening and/or other sinus pathologies was excluded from the study.
- Orthodontic treatment and maxillofacial surgery.
- Oral breathers.

### Processing of the CBCTs

#### *Volumetric measurements*

Once a subject had met all the criteria necessary for this analysis, the acquired DICOM file was exported from NNT viewer™ (NewTom, Verona, Italy) to Blue Sky Plan 4™ (Grayslake, IL, USA). The method used in our study to measure the maxillary sinus volume is a semi-automated computer-assisted segmentation technique.

The radiographic threshold was modified to make the maxillary airways visible (Figure 1). All the structures surrounding the maxillary sinuses were cut manually (Figure 2), and the sinus outline was later adjusted on each slice of the scan (0.5 mm slices) to ensure a more accurate definition of the total SV (Figure 3). The 3D models of the right and left maxillary sinuses were then exported to Autodesk Meshmixer™ (San Francisco, CA, USA) to obtain a complete representation of the sinuses after sealing all the communicating foramina with the surrounding anatomical structures (e.g., nasal cavities). At this stage, the sinus volume was automatically generated (Figure 4).

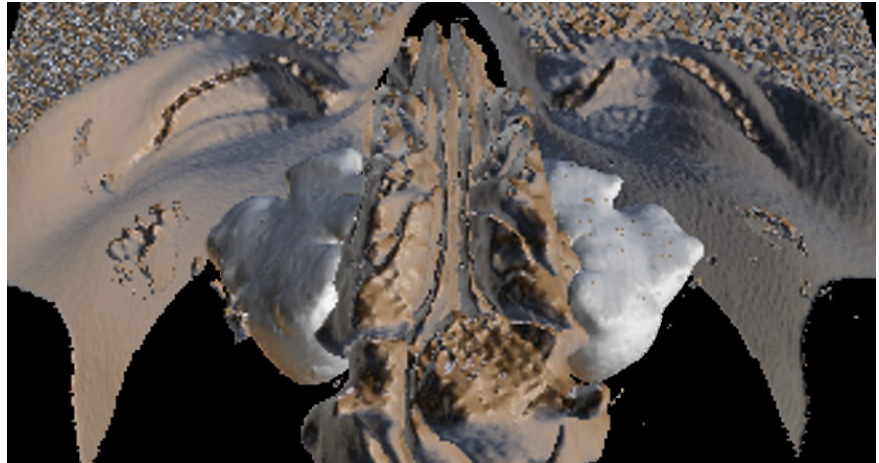


Figure 1. Three-dimensional reconstruction of the maxillary sinuses and the surrounding structures.

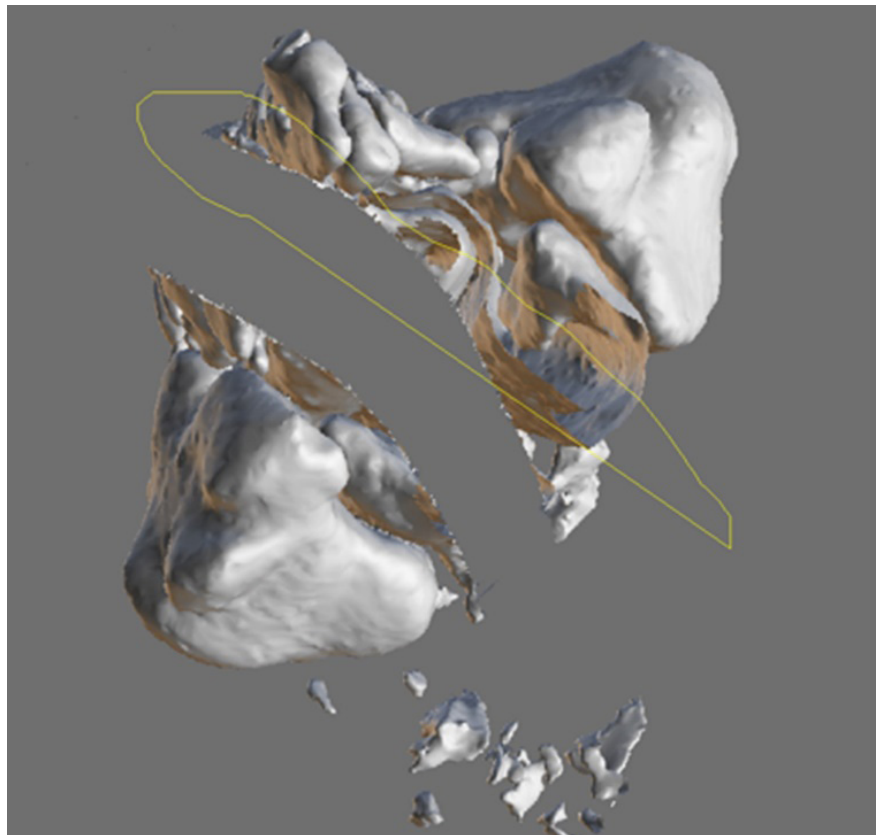


Figure 2. Manual cutting of the anatomical structures surrounding the maxillary sinuses.

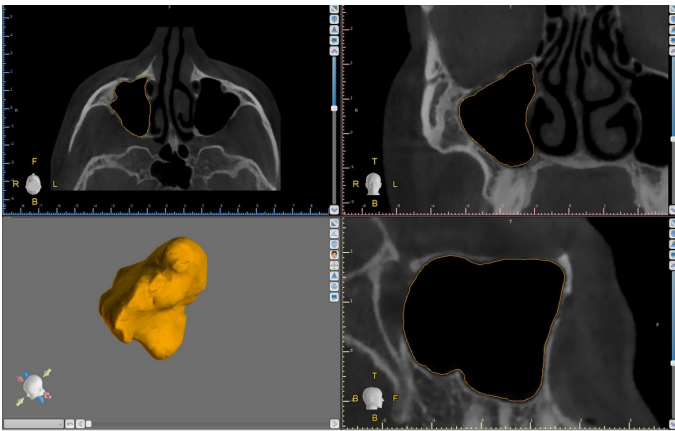


Figure 3. Manual adjustment of the maxillary sinus outline.

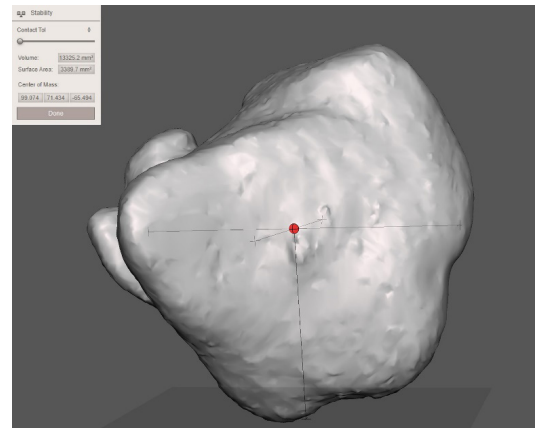


Figure 4. Three-dimensional representation of a maxillary sinus on Autodesk MeshmixerTM.

*Linear measurements*

A panoramic curve was drawn on the level of the cemento-enamel junction of the maxillary teeth and passing by the middle of each tooth in a palatal-buccal direction (Figure 5). The slice used to measure the IBH was

defined as a cut perpendicular to the horizontal scan plane and passing by the middle of the crown of each tooth in a mesio-distal direction (Figure 6). On this cut, a line was drawn joining the peaks of the buccal and palatal alveolar crests. The IBH was measured

from the most caudal point of the inferior sinus border to a horizontal line passing by the middle of the line previously drawn (Figure 7). This procedure was repeated on each tooth, from the first premolar to the second molar on the right and left sides.

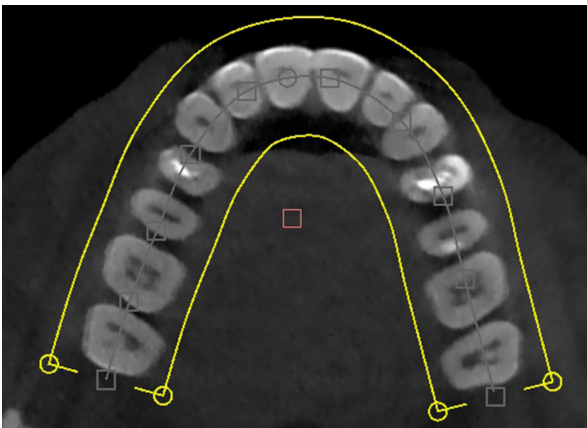


Figure 5. A CBCT slice showing the drawing of the panoramic curve passing by the middle of each maxillary tooth.




Figure 6. A three-dimensional reconstruction of the maxillary sinuses and surrounding structures showing a slice used for the measurement of IBH (vertical, yellow) perpendicular to the scan plane (horizontal, blue).

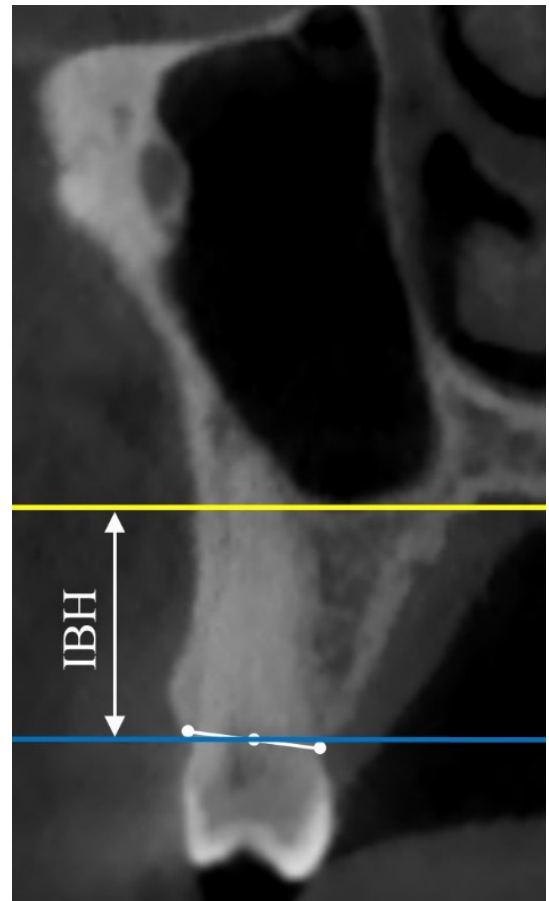


Figure 7. A cross-sectional cut showing the distance between the inferior border of the maxillary sinus (yellow line) and the alveolar crest (blue line).

### Clinical measurements

The patients were asked for a visit to record the soft tissue measurements.

The MFH was measured on each patient using two anthropometrical landmarks:

- Glabella (Gb): the most prominent point of the forehead on profile.
- Subnasal point (Sn): junction of the inferior portion of the nasal septum and the upper lip.

One observer took the measurements using an electronic caliper (MBC).

### Statistical analysis

The statistical package software for social sciences (SPSS for Windows, Chicago, IL, USA, version 25.0) was used for the statistical analysis of the data. The alpha error was set at  $p$ -value  $< 0.05$ . Frequency and percentage were utilized to describe categorical variables. Mean and standard deviation was used for continuous variables.

The normality distribution of continuous variables was verified using Kolmogorov-Smirnov tests. Parametric tests were performed for variables normally distributed. Non-parametric tests were executed when variables were not normally distributed.

- The association between continuous variables was performed using the Pearson product-moment correlation coefficient; preliminary analysis was performed to ensure no violation of the assumptions of normality, linearity, and homoscedasticity. When assumptions are violated, the Spearman correlation coefficient was calculated to test this relationship.
- Linear regression equations were obtained to predict the IBH (y) according to MFH (x) for the second premolar, first molar, and second molar of both the right and left sides.

## Results

### Description of the study population and the measurements variables

Thirty patients, 15 males, and 15 females, aged  $24.23 \pm 3$  years

(range: 20 – 30 years) were retrospectively selected for the study. The mean, standard deviation, minimum and maximum values of MFH, IBH, and SV are illustrated in tables 1, 2, 3, and 4.

Table 1. Descriptive parameters of the middle facial height.

	N	Minimum	Maximum	Mean	Standard deviation
<b>MFH (mm)</b>	30	57	78	66.23	0.54

Table 2. Descriptive parameters of the maxillary sinus volume.

	N	Minimum	Maximum	Mean	Standard deviation
<b>SV (cm<sup>3</sup>)</b>	60	12.82	16.87	14.73	1.49

Table 3. Descriptive parameters of the initial bone height in the right maxilla.

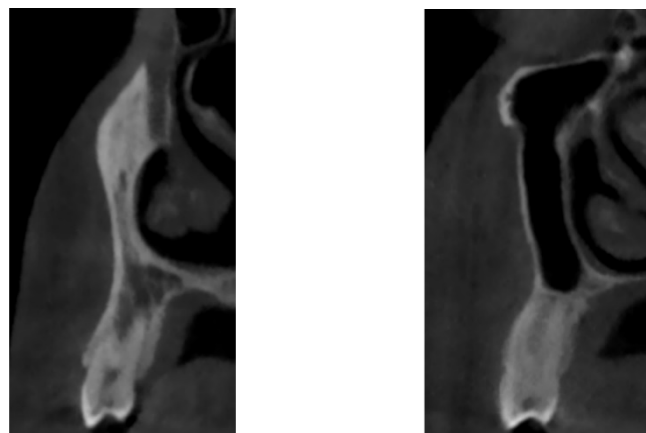
IBH (mm)	N	Minimum	Maximum	Mean	Standard deviation
1 <sup>st</sup> Premolar	16 <sup>1</sup>	11.8	19.1	14.78	2.12
2 <sup>nd</sup> Premolar	30	11.8	16.1	13.81	1.26
1 <sup>st</sup> Molar	30	8.3	13.2	10.37	1.36
2 <sup>nd</sup> Molar	30	8.9	15.0	11.40	1.64

<sup>1</sup>Sixteen out of 30 right first premolars were included in the statistical analysis. The other 14 were excluded because the maxillary sinus outline did not appear on the CT slice previously determined to measure the IBH on each tooth (Figure 8).

Table 4. Descriptive parameters of the initial bone height in the left maxilla.

IBH (mm)	N	Minimum	Maximum	Mean	Standard deviation
1 <sup>st</sup> Premolar	16 <sup>1</sup>	11.9	18.4	14.20	2
2 <sup>nd</sup> Premolar	30	11.5	15.7	13.64	1.20
1 <sup>st</sup> Molar	30	8.2	13.3	10.35	1.40
2 <sup>nd</sup> Molar	30	9.5	15.0	11.79	1.42

<sup>1</sup>Sixteen out of 30 left first premolars were included in the statistical analysis. The other 14 were excluded because the maxillary sinus outline did not appear on the CT slice previously determined to measure the IBH on each tooth (Figure 8).



(a) (b)

Figure 8. (a) A cross-sectional cut of a maxillary first premolar not showing the maxillary sinus outline; (b) A cross-sectional cut of a maxillary first premolar showing the maxillary sinus outline

### Correlation between middle facial height and sinus volume

Our data showed a significant correlation between MFH and SV (Table 5), either with the left SVs ( $r = 0.839$ ;  $-p\text{-value} < 0.001$ ) or with the right SVs ( $r = 0.861$ ;  $-p\text{-value} < 0.001$ ). The SVs increased with the MFH.

### Correlation between sinus volume and initial bone height

#### Right maxilla

No significant correlation was found between SV and IBH for the first premolars ( $r = -0.408$ ;  $-p\text{-value} = 0.166$ ). However, a negative correlation was found between the right SVs and IBH for the second premolars ( $r = -0.785$ ;  $-p\text{-value} < 0.001$ ), the first molars ( $r = -0.799$ ;  $-p\text{-value} < 0.001$ ), and the second molars ( $r = -0.754$ ;  $-p\text{-value} < 0.001$ ). In the right maxilla, the IBH decreases when the SV increases (Table 6).

#### Left maxilla

No significant correlation was found between left SV and IBH for the first premolars ( $r = -0.223$ ;  $-p\text{-value} = 0.407$ ). Nevertheless, a negative correlation was found between the left SVs and IBH for the second premolars ( $r = -0.739$ ;  $-p\text{-value} < 0.001$ ), the first molars ( $r = -0.647$ ;  $-p\text{-value} < 0.001$ ), and the second molars ( $r = -0.707$ ;  $-p\text{-value} < 0.001$ ). For the left maxilla, the IBH decreases when the SV increases (Table 7).

### Correlation between MFH and IBH

No significant correlation was found between MFH and IBH of the first right premolar ( $r = -0.360$ ;  $-p\text{-value} = 0.130$ ) and the first left premolar ( $r = -0.320$ ;  $-p\text{-value} = 0.102$ ). However, in the right maxilla, a negative correlation was found between MFH and IBH of the second premolar ( $r = -0.655$ ;  $-p\text{-value} < 0.001$ ), the first molar ( $r = -0.678$ ;  $-p\text{-value} < 0.001$ ), and the second molar ( $r = -0.689$ ;  $-p\text{-value} < 0.001$ ), as shown in table 8. In addition, in the left maxilla, a negative correlation was found between MFH and IBH

Table 5. Correlation between maxillary sinus volume and middle facial height.

	N	Correlation coefficient	$r^2$	-p-value
<b>Right maxilla</b>	30	.861	.741	.000
<b>Left Maxilla</b>	30	.839	.704	.000

Table 6. Correlation between sinus volume and initial bone height in the right maxilla.

	N	Correlation coefficient	$r^2$	-p-value
1 <sup>st</sup> Premolar	16	-.223	.050	.407
2 <sup>nd</sup> Premolar	30	-.739	.546	.000
1 <sup>st</sup> Molar	30	-.647	.419	.000
2 <sup>nd</sup> Molar	30	-.707	.500	.000

Table 7. Correlation between sinus volume and initial bone height in the left maxilla.

	N	Correlation coefficient	$r^2$	-p-value
1 <sup>st</sup> Premolar	16	-.408	.166	.117
2 <sup>nd</sup> Premolar	30	-.785	.614	.000
1 <sup>st</sup> Molar	30	-.799	.638	.000
2 <sup>nd</sup> Molar	30	-.754	.569	.000

Table 8. Correlation between middle facial height and initial bone height in the right maxilla.

	N	Correlation coefficient	$r^2$	-p-value
1 <sup>st</sup> Premolar	16	-.360	.130	.171
2 <sup>nd</sup> Premolar	30	-.652	.425	.000
1 <sup>st</sup> Molar	30	-.662	.438	.000
2 <sup>nd</sup> Molar	30	-.677	.458	.000

Table 9. Correlation between middle facial height and initial bone height in the left maxilla.

	N	Correlation coefficient	$r^2$	-p-value
1 <sup>st</sup> Premolar	16	-.320	.102	.299
2 <sup>nd</sup> Premolar	30	-.644	.415	.000
1 <sup>st</sup> Molar	30	-.500	.236	.000
2 <sup>nd</sup> Molar	30	-.532	.283	.002

of the second premolar ( $r = -0.655$ ;  $-p\text{-value} < 0.001$ ), the first molar ( $r = -0.506$ ;  $-p\text{-value} < 0.001$ ), and the second molar ( $r = -0.569$ ;  $-p\text{-val-}$

$ue < 0.001$ ), as shown in table 9. As a result, the IBH decreases when the MFH increases.

The linear regression equations between MFH (x) and IBH (y) for the second premolar, the first molar, and left sides are shown in figures 9,10,11,12,13 and 14 respectively.

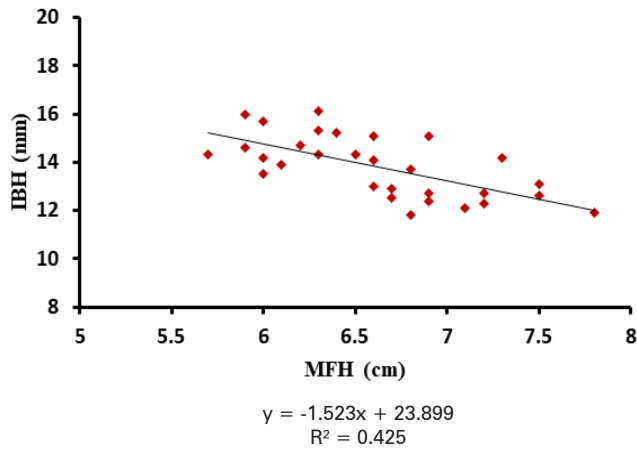


Figure 9. Linear regression equation between MFH (x) and IBH (y) for the second right premolar.

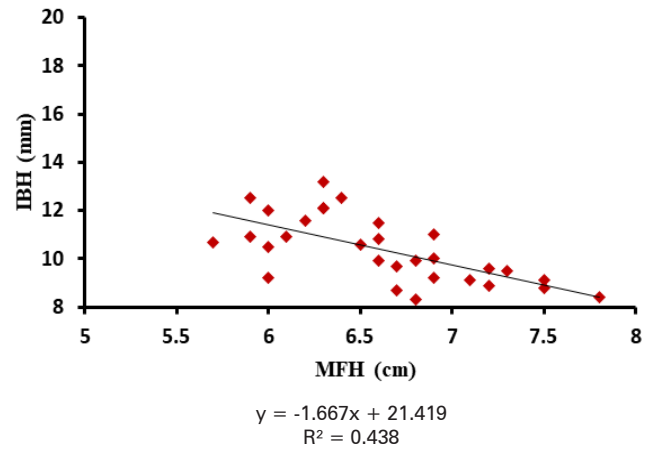


Figure 10. Linear regression equation between MFH (x) and IBH (y) for the first right molar.

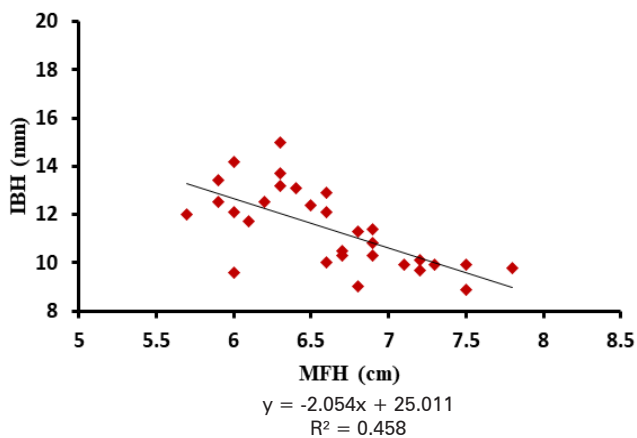


Figure 11. Linear regression equation between MFH (x) and IBH (y) for the second right molar.

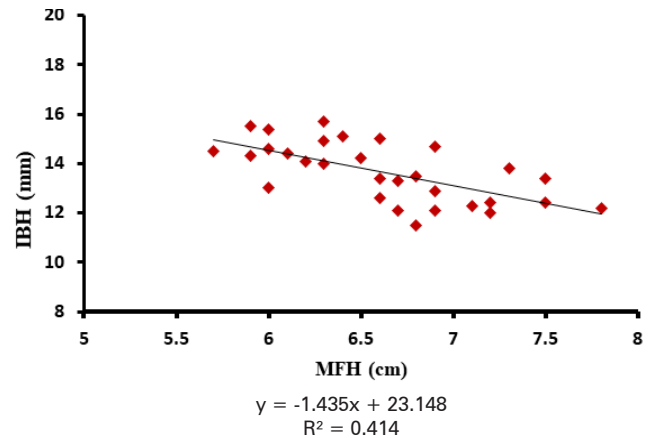


Figure 12. Linear regression equation between MFH (x) and IBH (y) for the second left premolar.

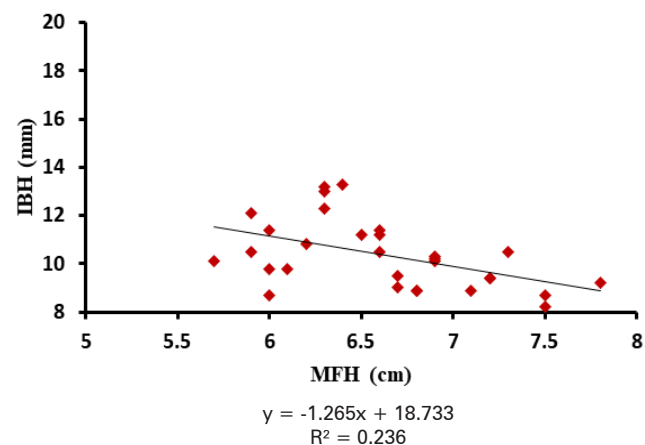


Figure 13. Linear regression equation between MFH (x) and IBH (y) for the first left molar.

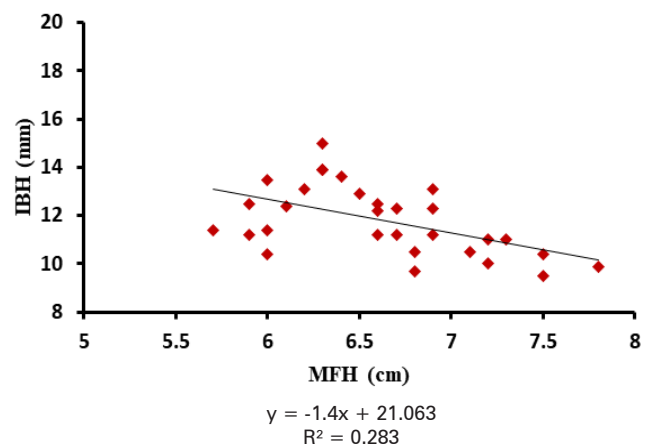


Figure 14. Linear regression equation between MFH (x) and IBH (y) for the second left molar.



## Discussion

The purpose of this study is to try to establish a correlation between the middle facial height (MFH) and the sinus volume (SV), SV, and the initial bone height (IBH), and therefore between MFH and IBH. Thirty fully dentate patients split evenly between males and females were retrospectively selected. CBCT scans were analyzed in terms of SV and IBH at the posterior maxillary sextants. Clinical soft tissue measurements were then performed on each subject to determine the MFH. The purpose of our study lies in the capability to estimate the IBH in the posterior maxillary sextants using a simple clinical facial measurement. As a result, a patient with a bigger risk of having a reduced IBH should be advised to consider, in case of an extracted tooth in the posterior maxilla, ridge preservation techniques, or implant placement as soon as possible to avoid future complex grafting surgeries.

### Middle facial height

As it is widely known, facial measurements are strongly correlated with race and ethnicity [15]. Farkas et al. conducted a multinational study of facial morphology in various ethnic groups. They also found that most of the facial dimensions are correlated with race. Moreover, the authors used the distance between the soft tissue nasion and the sub-nasal point to measure the height of the anterior middle face. In a middle eastern group (n=180), the mean MFH for males and females respectively were as follows: 6.2 cm and 5.8 cm (Iranians), 5.4 cm and 4.7 cm (Egyptians), and 5.8 cm and 5.5 cm (Turkish) [16]. These measurements seem to be slightly inferior to the ones found in our study. This could be explained by the different selections of the first anthropometrical landmark in each protocol.

### Sinus volume

There are several other factors affecting the maxillary SV besides

the skeletal size of the maxillary bone such as the patient's age. Sahlstrand-Johnson et al. found a mean SV of 14.4 cm<sup>3</sup>, 16.6 cm<sup>3</sup>, and 15.2 cm<sup>3</sup> when the ages ranged between 18-33, 34-49, and 50-65 years respectively [17] as we showed that acoustic streaming could be generated in nonpurulent sinus secretions and helped to distinguish it from mucopurulent sinus secretions. In order to continue this development of a clinically applicable Doppler equipment, we need to determine different dimensions of the paranasal sinuses, especially the thickness of the anterior wall of the maxillary sinus (at the canine fossa. Jun et al. found that the development of the maxillary sinus continued up until the third decade in males and the second decade in females, and thereafter its size decreased [18]. Cohen et al. showed a mean SV of 14.81 and 11.82 cm<sup>3</sup> for subjects under and over 65 years respectively [19]. The subjects recruited in our study had an age range between 20 to 30 years in an attempt to eliminate the bias caused by the age factor when it comes to measuring maxillary SV.

In addition, oral breathing seems to affect the SV as well. A study showed that oral breathers for more than 5 years have significantly lower maxillary sinus volumes than nasal breathers [20]. Again, all patients having oral breathing were excluded from the analysis.

There are many methods mentioned in the literature to measure the volume of the paranasal sinus cavities. These different protocols lead to variable and inconsistent results that normally depend on the accuracy and reproducibility of each technique used. Early cadaveric studies reported a mean SV of 11.3 cm<sup>3</sup> [21], while others conducted on lateral cephalograms revealed a mean of 13.07 cm<sup>3</sup> [22]. Emirzeoglu et al., in contrast, found a mean of 18 cm<sup>3</sup> by applying the Cavalieri principle on consecutive slices of the CT scans [23]. Studies using computer-assisted segmentation showed

a mean of 13.07 cm<sup>3</sup> [24] and 15.7 cm<sup>3</sup> [17] as we showed that acoustic streaming could be generated in nonpurulent sinus secretions and helped to distinguish it from mucopurulent sinus secretions. In order to continue this development of a clinically applicable Doppler equipment, we need to determine different dimensions of the paranasal sinuses, especially the thickness of the anterior wall of the maxillary sinus (at the canine fossa which seem consistent with our findings.

Currently, computer-assisted segmentation is set to be the gold standard for measuring and analyzing maxillo-facial airways [19].

### Initial bone height

A part of our study was designed to measure the IBH in the maxillary posterior sextants from the first premolar to the second molar. The maxillary sinus was radiographically visible in 53% of the first premolar sites. The IBH showed a significant decrease from the first premolar to molar sites. The first premolar had the highest mean of IBH followed by the second premolar, the second molar, and finally the first molar for both the right and left sides.

These findings are consistent with the results shown by Farina et al. after analyzing the ridge dimensions of the posterior maxilla before and after tooth loss using computerized tomography data [5].

All the patients included in our study did not have any kind of periodontal disease or endodontic/periapical lesions. As it is widely known, periodontitis is associated with alveolar bone loss which will affect the measurement of the IBH. In addition, endodontic and periapical lesions might cause alveolar and/or periapical bone loss that can interfere with or misplace the inferior border of the maxillary sinus and consequently, the measurement of the IBH becomes inaccurate [25] bone height (BH).

### Correlation between middle facial height and sinus volume

In our study, statistical analysis of the data showed a significant positive correlation between MFH and SV, which means that the maxillary sinus tends to increase in volume when the MFH increases. This can be explained by the fact that most of the sinus's mass is located in the skeletal part of the skull corresponding to the middle face measured between the two soft tissue reference points previously determined. This morphometric correlation between facial soft tissue anthropometrical landmarks and the skeletal pattern is widely described by many authors [26,27]. As a result, we found that the sinus volume seems to vary with the linear vertical measurement of the anterior middle face. Nevertheless, maxillary sinuses are three-dimensional air cavities in the maxillary bone. Thus, the horizontal and anteroposterior dimensions of the latter seem to also affect its volume. A study conducted across 15 populations of Asian origin concluded that the maxillary sinus volume is bigger in subjects having a larger facial skeleton [28]. Other authors also concluded, using skeletal landmarks, that larger maxillary sinuses are correlated with greater maxillary and zygomatic heights [29] minimizing the impact of climatic-related changes in nasal cavity breadth on surrounding skeletal structures. However, a recent study among modern human crania has identified that, in addition to nasal cavity breadth, sinus morphology also tracks lateral facial form, especially anterior-posterior positioning of the zygomatics. Here, we expand upon this previous study to further investigate these covariation patterns by employing three samples with distinct combinations of nasal and zygomatic morphologies: Northern Asians ( $n = 28$ ).

To our knowledge, this is the first study to evaluate the correlation between the vertical dimension of the middle face, using soft tissue landmarks, and the maxillary SV.

### Correlation between sinus volume and initial bone height

Our second aim was to evaluate the correlation between SV and IBH. For both right and left sinuses, no significant correlation was found between these two entities for the first premolar.

Thirty-two out of 60 first premolars, were included in the statistical analysis. The other 28 first premolars were excluded because the maxillary sinus outline did not appear on the CT slice previously determined to measure the IBH on each tooth. As a result, about 53% of all first premolars were examined which seems consistent with the results found in another study (50%) using the same protocol to measure the alveolar bone height in the posterior maxillary sextants [5]. In addition, some of the first premolars included in the analysis presented much higher levels of IBH than the rest of the teeth examined. These two reasons may be the cause for the insignificant correlation found between the IBH of maxillary first premolars and the SV. In contrast, a significant negative correlation was found between SV and the IBH of the second premolar, first molar, and second molar on both the right and left sides.

### Correlation between middle facial height and initial bone height

Our results showed a significant negative correlation between the MFH and the IBH of the second premolar, first molar, and second molar on both sides. Again, the weak correlation between the MFH and the IBH of the first premolar can be explained by the same reasons described previously.

To our knowledge; this is the first study to establish a correlation between the IBH at the posterior maxillary sextants and the MFH in dentate patients using soft tissue landmarks. Recently, Kuc et al. conducted a study on 25 healthy edentulous Caucasian individuals and analyzed the alveolar ridge atrophy and its correlation with facial morphology. The

residual bone height was measured on a telerradiograph from different points of the alveolar ridge to a line joining the anterior and posterior nasal spines. A significant negative correlation was found between the residual bone height at the edentulous posterior maxillary and the distance between Gb and Sn [30].

The linear regression equations between MFH (x) and IBH (y) should be interpreted carefully due to the limitations of our study ( $n=30$ ). Future research should be conducted on a larger number of patients, preferably from the same race to obtain equations that can be applied in the daily practice of the general practitioner.

## Conclusion

After analyzing the results of our study, we can conclude that the maxillary SV increases with the MFH, and the IBH decreases when the SV and the MFH increase. The clinical relevance of this study lies in the capability of the general practitioner to estimate the IBH in the posterior dentate maxilla by taking a simple facial measurement (MFH). Thus, patients with higher dimensions of the MFH tend to have bigger maxillary SVs, which in turn translates into a lower IBH at the posterior maxillary dentate sextants. As a result, these patients should be advised, if a posterior tooth is to be extracted, to consider ridge preservation techniques or implant placement as soon as possible to avoid major future grafting oral surgeries. Future research is necessary to establish a threshold of the MFH, above which patients are considered with a high risk of having low IBH.

## Funding

This research received no external funding.

## References

- Schropp, L.; Wenzel, A.; Kostopoulos, L.; Karring, T. Bone Healing and Soft Tissue Contour Changes Following Single-Tooth Extraction: A Clinical and Radiographic 12-Month Prospective Study. *Int. J. Periodontics Restorative Dent.*, 2003, 23 (4), 313–323.
- Pietrokovski, J.; Starinsky, R.; Arensburg, B.; Kaffe, I. Morphologic Characteristics of Bony Edentulous Jaws. *J. Prosthodont. Off. J. Am. Coll. Prosthodont.*, 2007, 16 (2), 141–147. <https://doi.org/10.1111/j.1532-849X.2007.00165.x>.
- Tan, W. L.; Wong, T. L. T.; Wong, M. C. M.; Lang, N. P. A Systematic Review of Post-Extraction Alveolar Hard and Soft Tissue Dimensional Changes in Humans. *Clin. Oral Implants Res.*, 2012, 23 Suppl 5, 1–21. <https://doi.org/10.1111/j.1600-0501.2011.02375.x>.
- Frost, H. M. Wolff's Law and Bone's Structural Adaptations to Mechanical Usage: An Overview for Clinicians. *Angle Orthod.*, 1994, 64 (3), 175–188. [https://doi.org/10.1043/0003-3219\(1994\)064<0175:WLABSA>2.0.CO;2](https://doi.org/10.1043/0003-3219(1994)064<0175:WLABSA>2.0.CO;2).
- Farina, R.; Pramstraller, M.; Franceschetti, G.; Pramstraller, C.; Trombelli, L. Alveolar Ridge Dimensions in Maxillary Posterior Sextants: A Retrospective Comparative Study of Dentate and Edentulous Sites Using Computerized Tomography Data. *Clin. Oral Implants Res.*, 2011, 22 (10), 1138–1144. <https://doi.org/10.1111/j.1600-0501.2010.02087.x>.
- Avila, G.; Wang, H.-L.; Galindo-Moreno, P.; Misch, C. E.; Bagramian, R. A.; Rudek, I.; Benavides, E.; Moreno-Riestra, I.; Braun, T.; Neiva, R. The Influence of the Bucco-Palatal Distance on Sinus Augmentation Outcomes. *J. Periodontol.*, 2010, 81 (7), 1041–1050. <https://doi.org/10.1902/jop.2010.090686>.
- Corbella, S.; Taschieri, S.; Weinstein, R.; Del Fabbro, M. Histomorphometric Outcomes after Lateral Sinus Floor Elevation Procedure: A Systematic Review of the Literature and Meta-Analysis. *Clin. Oral Implants Res.*, 2016, 27 (9), 1106–1122. <https://doi.org/10.1111/clr.12702>.
- Stacchi, C.; Lombardi, T.; Ottonelli, R.; Berton, F.; Perinetti, G.; Traini, T. New Bone Formation after Transcrestal Sinus Floor Elevation Was Influenced by Sinus Cavity Dimensions: A Prospective Histologic and Histomorphometric Study. *Clin. Oral Implants Res.*, 2018, 29 (5), 465–479. <https://doi.org/10.1111/clr.13144>.
- Beretta, M.; Cicciù, M.; Poli, P. P.; Rancitelli, D.; Bassi, G.; Grossi, G. B.; Maiorana, C. A Retrospective Evaluation of 192 Implants Placed in Augmented Bone: Long-Term Follow-Up Study. *J. Oral Implantol.*, 2015, 41 (6), 669–674. <https://doi.org/10.1563/aaid-joi-D-14-00123>.
- Orsini, G.; Stacchi, C.; Visintini, E.; Di Iorio, D.; Putignano, A.; Breschi, L.; Di Lenarda, R. Clinical and Histologic Evaluation of Fresh Frozen Human Bone Grafts for Horizontal Reconstruction of Maxillary Alveolar Ridges. *Int. J. Periodontics Restorative Dent.*, 2011, 31 (5), 535–544.
- Monje, A.; Pikos, M. A.; Chan, H.-L.; Suarez, F.; Gargallo-Albiol, J.; Hernández-Alfaro, F.; Galindo-Moreno, P.; Wang, H.-L. On the Feasibility of Utilizing Allogeneic Bone Blocks for Atrophic Maxillary Augmentation. *BioMed Res. Int.*, 2014, 2014, 814578. <https://doi.org/10.1155/2014/814578>.
- Güncü, G. N.; Yildirim, Y. D.; Wang, H.-L.; Tözüm, T. F. Location of Posterior Superior Alveolar Artery and Evaluation of Maxillary Sinus Anatomy with Computerized Tomography: A Clinical Study. *Clin. Oral Implants Res.*, 2011, 22 (10), 1164–1167. <https://doi.org/10.1111/j.1600-0501.2010.02071.x>.
- Stacchi, C.; Andolsek, F.; Berton, F.; Perinetti, G.; Navarra, C. O.; Di Lenarda, R. Intraoperative Complications During Sinus Floor Elevation with Lateral Approach: A Systematic Review. *Int. J. Oral Maxillofac. Implants*, 2017, 32 (3), e107–e118. <https://doi.org/10.11607/jomi.4884>.
- Esposito, M.; Felice, P.; Worthington, H. V. Interventions for Replacing Missing Teeth: Augmentation Procedures of the Maxillary Sinus. *Cochrane Database Syst. Rev.*, 2014, No. 5, CD008397. <https://doi.org/10.1002/14651858.CD008397.pub2>.
- Alam, M. K.; Mohd Noor, N. F.; Basri, R.; Yew, T. F.; Wen, T. H. Multiracial Facial Golden Ratio and Evaluation of Facial Appearance. *PloS One*, 2015, 10 (11), e0142914. <https://doi.org/10.1371/journal.pone.0142914>.
- Farkas, L. G.; Katic, M. J.; Forrest, C. R.; Alt, K. W.; Bagic, I.; Baltadjiev, G.; Cunha, E.; Cvicelová, M.; Davies, S.; Erasmus, I.; et al. International Anthropometric Study of Facial Morphology in Various Ethnic Groups/Races. *J. Craniofac. Surg.*, 2005, 16 (4), 615–646. <https://doi.org/10.1097/01.scs.0000171847.58031.9e>.
- Sahlstrand-Johnson, P.; Jannert, M.; Strömbeck, A.; Abul-Kasim, K. Computed Tomography Measurements of Different Dimensions of Maxillary and Frontal Sinuses. *BMC Med. Imaging*, 2011, 11, 8. <https://doi.org/10.1186/1471-2342-11-8>.
- Jun, B.-C.; Song, S.-W.; Park, C.-S.; Lee, D.-H.; Cho, K.-J.; Cho, J.-H. The Analysis of Maxillary Sinus Aeration According to Aging Process; Volume Assessment by 3-Dimensional Reconstruction by High-Resolution CT Scanning. *Otolaryngol.--Head*

- Neck Surg. Off. J. Am. Acad. Otolaryngol.-Head Neck Surg.*, 2005, 132 (3), 429–434. <https://doi.org/10.1016/j.otohns.2004.11.012>.
19. Cohen, O.; Warman, M.; Fried, M.; Shoffel-Havakuk, H.; Adi, M.; Halperin, D.; Lahav, Y. Volumetric Analysis of the Maxillary, Sphenoid and Frontal Sinuses: A Comparative Computerized Tomography Based Study. *Auris. Nasus. Larynx*, 2018, 45 (1), 96–102. <https://doi.org/10.1016/j.anl.2017.03.003>.
  20. Agacayak, K. S.; Gulsun, B.; Koparal, M.; Atalay, Y.; Aksoy, O.; Adiguzel, O. Alterations in Maxillary Sinus Volume among Oral and Nasal Breathers. *Med. Sci. Monit. Int. Med. J. Exp. Clin. Res.*, 2015, 21, 18–26. <https://doi.org/10.12659/MSM.891371>.
  21. Uchida, Y.; Goto, M.; Katsuki, T.; Akiyoshi, T. A Cadaveric Study of Maxillary Sinus Size as an Aid in Bone Grafting of the Maxillary Sinus Floor. *J. Oral Maxillofac. Surg. Off. J. Am. Assoc. Oral Maxillofac. Surg.*, 1998, 56 (10), 1158–1163. [https://doi.org/10.1016/s0278-2391\(98\)90761-3](https://doi.org/10.1016/s0278-2391(98)90761-3).
  22. Endo, T.; Abe, R.; Kuroki, H.; Kojima, K.; Oka, K.; Shimooka, S. Cephalometric Evaluation of Maxillary Sinus Sizes in Different Malocclusion Classes. *Odontology*, 2010, 98 (1), 65–72. <https://doi.org/10.1007/s10266-009-0108-5>.
  23. Emirzeoglu, M.; Sahin, B.; Bilgic, S.; Celebi, M.; Uzun, A. Volumetric Evaluation of the Paranasal Sinuses in Normal Subjects Using Computer Tomography Images: A Stereological Study. *Auris. Nasus. Larynx*, 2007, 34 (2), 191–195. <https://doi.org/10.1016/j.anl.2006.09.003>.
  24. Sánchez Fernández, J. M.; Anta Escuredo, J. A.; Sánchez Del Rey, A.; Santaolalla Montoya, F. Morphometric Study of the Paranasal Sinuses in Normal and Pathological Conditions. *Acta Otolaryngol. (Stockh.)*, 2000, 120 (2), 273–278. <https://doi.org/10.1080/000164800750001080>.
  25. Pramstraller, M.; Farina, R.; Franceschetti, G.; Pramstraller, C.; Trombelli, L. Ridge Dimensions of the Edentulous Posterior Maxilla: A Retrospective Analysis of a Cohort of 127 Patients Using Computerized Tomography Data. *Clin. Oral Implants Res.*, 2011, 22 (1), 54–61. <https://doi.org/10.1111/j.1600-0501.2010.01984.x>.
  26. Halazonetis, D. J. Morphometric Correlation between Facial Soft-Tissue Profile Shape and Skeletal Pattern in Children and Adolescents. *Am. J. Orthod. Dentofac. Orthop. Off. Publ. Am. Assoc. Orthod. Its Const. Soc. Am. Board Orthod.*, 2007, 132 (4), 450–457. <https://doi.org/10.1016/j.ajodo.2005.10.033>.
  27. Zedníková Malá, P.; Krajíček, V.; Velemínská, J. How Tight Is the Relationship between the Skeletal and Soft-Tissue Facial Profile: A Geometric Morphometric Analysis of the Facial Outline. *Forensic Sci. Int.*, 2018, 292, 212–223. <https://doi.org/10.1016/j.forsci-int.2018.09.014>.
  28. Evteev, A. A.; Grosheva, A. N. Nasal Cavity and Maxillary Sinuses Form Variation among Modern Humans of Asian Descent. *Am. J. Phys. Anthropol.*, 2019, 169 (3), 513–525. <https://doi.org/10.1002/ajpa.23841>.
  29. Maddux, S. D.; Butaric, L. N. Zygomaticomaxillary Morphology and Maxillary Sinus Form and Function: How Spatial Constraints Influence Pneumatization Patterns among Modern Humans. *Anat. Rec. Hoboken NJ* 2007, 2017, 300 (1), 209–225. <https://doi.org/10.1002/ar.23447>.
  30. Kuć, J.; Sierpińska, T.; Gołębowska, M. Alveolar Ridge Atrophy Related to Facial Morphology in Edentulous Patients. *Clin. Interv. Aging*, 2017, 12, 1481–1494. <https://doi.org/10.2147/CIA.S140791>.