

# A NOVEL 3D EVALUATION OF THE CORRELATION BETWEEN THE CONDYLAR POSITION AND ANGLE CLASSIFICATION IN A LEBANESE POPULATION: A PILOT STUDY

Carine Haddad<sup>1</sup> | Amine Zoghbi<sup>2</sup> | Nabil Ghosn<sup>3</sup> | Abboud Youssef<sup>4</sup> | Camille Haddad<sup>5</sup>

## Abstract

**Introduction:** The temporomandibular joint (TMJ) is one of the most complex joints. Its morphology varies between individuals, and even between the left and right sides. Several studies have found a significant relation between certain occlusal features and joint morphology. Cone-beam computed tomography (CBCT) imaging is currently the most widely adopted modality for the examination of the TMJ.

**Objective:** This study aimed to compare the joint space in a Lebanese cohort with different Angle classification using CBCT.

**Methodology:** We retrospectively analyzed CBCT images performed at the Saint Joseph University of Beirut in Lebanon, over a period of 1 year, between 2021 and 2022. Four clearance values were selected, representing the minimum distance between the temporal bone and the mandibular condyle that defines the joint space: 0.5 mm, 1 mm, 1.5 mm, and 2 mm. For each value chosen, we looked for the presence or not of a visible surface. This surface corresponds to the area of the condyle with a distance from the condyle to the temporal bone less than or equal to the chosen value.

**Results:** Twenty-nine patients aged between 12 and 60 years old were included; 12 (41%) were males and 17 (59%) females. We classified 48 CBCT images (23 on the right side and 25 on the left side) into three groups according to Angle's classification: class I (n=14), class II (n=29), and class III (n=5). For a distance of [0-1.5 mm] corresponded a surface of 0 mm<sup>2</sup>. For the interval between [1.5-2 mm] corresponded a surface of 18,8 mm<sup>2</sup> for class I subjects, 16,6 mm<sup>2</sup> for class II, and 30,5 mm<sup>2</sup> for class III. The results showed no statistically significant differences between the articular spaces and the different types of occlusion.

**Conclusion:** The three-dimensional evaluation of the condylar position by CBCT showed that there are no significant differences between the joint spaces and the different types of occlusion according to Angle's classification.

**Keywords:** condylar position; Angle classification; occlusion; CBCT.

---

## Corresponding author:

Dr Carine Haddad. Email: carine.haddad1@net.usj.edu.lb

## Conflicts of interest:

The authors declare no conflicts of interest.

1. Department of Fixed Prosthodontics and Occlusion, Faculty of Dental Medicine, Saint Joseph University of Beirut, Beirut, Lebanon. carine.haddad1@net.usj.edu.lb
2. Head of Department of Fixed Prosthodontics and Occlusion, Faculty of Dental Medicine, Saint Joseph University of Beirut,, Beirut, Lebanon. amine.el-zoghby@usj.edu.lb
3. Craniofacial Research Laboratory, faculty of Dental Medicine, Saint Joseph University of Beirut, Beirut, Lebanon. nabil.ghosn@usj.edu.lb
4. Department of Fixed Prosthodontics and Occlusion, Faculty of Dental Medicine, Saint Joseph University of Beirut, Beirut, Lebanon. abboudyoussef95@gmail.com
5. Department of Fixed Prosthodontics and Occlusion, Faculty of Dental Medicine, Saint Joseph University of Beirut, Beirut, Lebanon. camhaddad@gmail.com

## **ANALYSE TRIDIMENSIONNELLE DE LA POSITION CONDYLIENNE PAR TOMOGRAPHIE SELON LES DIFFÉRENTES CLASSES D'ANGLE DANS UNE POPULATION LIBANAISE: UNE ÉTUDE PILOTE**

### **Résumé**

**Introduction** : L'articulation temporo-mandibulaire (ATM) est l'une des articulations les plus complexes. Sa morphologie varie selon les individus, et même entre les côtés gauche et droit. Plusieurs études ont démontré une relation significative entre certaines caractéristiques occlusales et la morphologie articulaire. La tomodynamométrie à faisceau conique (CBCT) est actuellement la modalité la plus largement adoptée pour l'examen de l'ATM.

**Objectif** : Cette étude vise à comparer, dans une cohorte Libanaise, l'espace interarticulaire avec les différentes classes d'Angle en utilisant le CBCT.

**Méthodologie** : Une analyse rétrospective a été menée sur des images CBCT réalisées à l'Université Saint Joseph de Beyrouth sur une période de 1 an, entre 2021 et 2022. Quatre valeurs de clairance ont été sélectionnées, représentant la distance minimale entre l'os temporal et le condyle mandibulaire qui définit l'espace interarticulaire : 0,5 mm, 1 mm, 1,5 mm et 2 mm. Pour chaque valeur choisie, nous avons recherché la présence ou non d'une surface visible. Cette surface correspond à la zone du condyle ayant une distance du condyle à l'os temporal inférieure ou égale à la valeur choisie.

**Résultats** : Vingt-neuf patients âgés de 12 à 60 ans ont été inclus ; 12 (41 %) étaient des hommes et 17 (59 %) des femmes. Les 48 images CBCT (23 du côté droit et 25 du côté gauche) ont été réparties en trois groupes selon la classification d'Angle : classe I (n = 14), classe II (n = 29) et classe III (n = 5). Pour une distance de [0 mm ; 0,5 mm ; 1mm et 1,5mm] correspondent des surfaces de valeurs nulles. Pour un intervalle compris entre [1,5 – 2mm] correspond une surface de 18,8 mm<sup>2</sup> pour les sujets de classe I, 16,6 mm<sup>2</sup> pour les sujets de classe II, et 30,5 mm<sup>2</sup> pour les sujets de classe III. Les résultats n'ont pas montré de corrélation statistiquement significative entre l'espace interarticulaire et les différentes classes d'Angle.

**Conclusion** : L'évaluation tridimensionnelle de la position condylienne par CBCT a montré qu'il n'existe pas de corrélation entre les espaces interarticulaires et les différentes classes d'Angle.

**Mots clés** : position condylienne ; classification d'Angle ; occlusion ; CBCT ; tomodynamométrie.

## Introduction

The temporomandibular joint (TMJ) is a bilateral synovial joint covered by a fibrocartilage that contains both collagens type I and II, linking the mandible to the base of the skull [1] [2]. It is one of the most complex joints due to its anatomical, histological and biomechanical characteristics. Its morphology varies between individuals, and even between the left and right sides.[3] Indeed, condylar shape and position can be influenced by several factors, including age, sex, occlusion, physiological adaptations and para-functional hyperactivity that results in the increase in intensity and time of the forces applied to the condyle [4] [5]. The impact of dental relationships on static and functional occlusion is well established, but their influence on joint morphology is still not fully understood. Angle's classification has been widely used since its introduction in 1899 by Edward Angle to classify these relationships.[6] Angle proposed a classification in which he divided the different types of malocclusion into three separate categories or classes: class I or neutroocclusion, class II or distoocclusion, and class III or mesioocclusion [6].

Several studies have found a significant relation between certain occlusal features and joint morphology [7]. For example, they found that condyles had a more anterior, posterior or superior position in various occlusal relationships [8]. This condylar positioning or displacement may exist in certain occlusions and can produce alterations in the TMJ. However, other studies have not demonstrated these correlations [9]. Hence the importance of studying the repercussions of these different types of occlusions on the joint space and their etiological role in the development of joint compression caused by the narrowing of the joint space in certain types of occlusions, which could in some cases cause pain and lead the patient to seek medical attention [10].

Indeed, the morphological characteristics of TMJ in association with malocclusions have been studied with different imaging modalities. The superposition of neighboring structures has always compromised the visualization of TMJ, which is why computed tomography (CT) imaging allows a clearer visualization of the areas surrounding the TMJ [11]. In addition, cone-beam computed tomography systems (CBCT) imaging provides multi-planar images in the axial, sagittal and coronal anatomical planes. These reconstructed sections also allow a better evaluation of the position of the condyle in the glenoid fossa [12]. Therefore, CBCT imaging is currently the most widely adopted modality for the examination of the TMJ [13].

Hence the interest of this study, which is the first in Lebanon to evaluate by CBCT the three-dimensional measurements of the joint space of the TMJ and to study the impact of the different types of occlusions on the joint space and their etiological role in the development of joint compression.

## Materials and Methods

### Study design and patient population

This is a retrospective study conducted at the Saint Joseph University of Beirut in Lebanon, over a period of 1 year, between June 2021 and June 2022. 48 CBCTs for 29 patients were selected from the radiology department. The patients were divided into 3 groups according to the Angle classification: class I, class II, or class III. Pediatric and adult patients were included in this study. They had complete permanent dentition, normal oral posture and virtue, did not have coarse asymmetry, nor a history of temporomandibular pathology, no pain or deterioration at the opening, no pain on palpation, no history of surgery, no rheumatological diseases and no history of orthodontic treat-

ment. These criteria were assessed through a questionnaire and clinical examination.

### CBCT Analysis

Image analysis consists of segmentation, reconstruction and 3D measurement of images using the 2-software 3D slicer and autodesk meshmixer. CBCT images saved in DICOM (Digital Imaging and Communications in Medicine) format defines a medical image format that can be used for data exchange with a quality that meets clinical needs, and will be imported to the 3D slicer software. This was followed by a segmentation of the mandibular condyle and the temporal bone from the rest. After segmenting the condyle and temporal of the rest of the bone bases using the 3D slicer software, the joint area will be calculated directly by the autodesk mesh-mixer software using "stability tool" and its value will be expressed in mm [2]. Hidden areas are converted into a 3D model (Fig. 1).

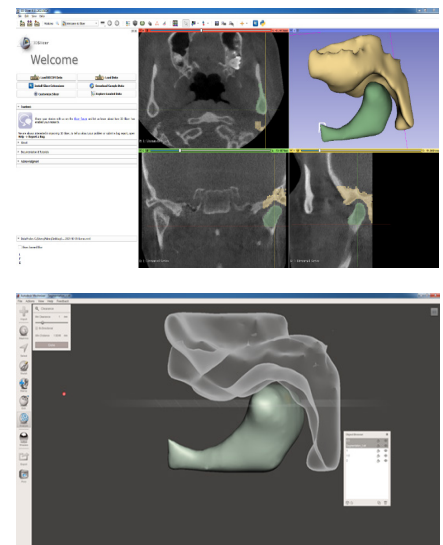


Fig. 1: Image analysis using the 2-software 3D slicer and autodesk meshmixer

Four clearance values were selected, representing the minimum distance between the temporal bone and the mandibular condyle that defines the joint space: 0.5 mm, 1 mm, 1.5 mm, and 2 mm. For each value chosen, we looked for the presence or not of an articular surface. The measurements of each image were carried out by two independent researchers to ensure reproducibility and fidelity of the measurements (Fig. 2).

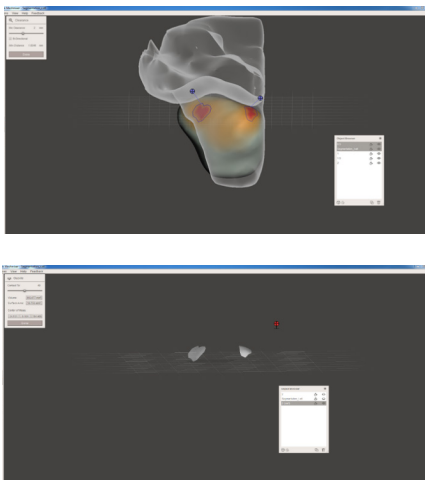


Fig. 2: Measurements of each image

### Statistical analysis

Continuous variables will be represented by their medians and intervals, and categorical variables by the numbers and percentages of each category. The “Wilcoxon rank-sum” test will be used to study the relationship between categorical and ordinal variables and the  $\chi^2$  test for two categorical variables. The significance threshold will be set for  $P < 0.05$ . The statistical analysis will be performed using the software IBM SPSS Statistics version 25.0

### Ethical statement

The ethical approval for this study was obtained by the ethics committee of the Saint Joseph University of Beirut and the study was conducted in accordance with the Declaration of Helsinki and Good Clinical Practice guidelines.

## Results

### Patient characteristics

29 patients were included in this analysis, with a median age of 17 years (range, 9 to 60 years). 17 (57%) were females and 12 (43%) were males. A total of 48 CBCT images were analyzed: 23 (48%) from the right side and 25 (52%) from the left side. The types of malocclusion were distributed according to the Angle classification as follow: 14 images in class I (group 1), 29 images in class II (group 2), and 5 images in class III (group 3). No significant differences were observed between baseline characteristics in the 3 different groups (Table 1) and between left and right side (Table 2).

Characteristics	Classe I N=14	Classe II N=29	Classe III N=5	P
Sex, n (%)				
Female	6 (67)	9 (56)	2 (50)	0.8
Male	3 (33)	7 (44)	2 (50)	
Median age (range), years	20 (12-57)	15 (9-60)	18 (16-41)	0.6
Side, n (%)				
Right	7 (50)	14 (48)	2 (40)	0.9
Left	7 (50)	15 (52)	3 (60)	
]0-0.5 mm], n (%)	2 (14)	5 (17)	0	0.6
Median surface (range), mm <sup>2</sup>	0 (0-0)	0 (0-0)	0 (0-0)	1.0
]0.5-1 mm], n (%)	0	1 (4)	0	0.7
Median surface (range), mm <sup>2</sup>	0 (0-0)	0 (0-0)	0 (0-0)	1.0
]1-1.5 mm], n (%)	4 (29)	7 (24)	2 (40)	0.8
Median surface (range), mm <sup>2</sup>	0 (0-12.53)	0 (0-216.25)	0 (0-9.58)	0.7
]1.5-2 mm], n (%)	6 (43)	11 (38)	3 (60)	0.7
Median surface (range), mm <sup>2</sup>	18.77 (0-62.33)	16.64 (0-96.46)	30.47 (9.13-49.99)	0.9
>2 mm, n (%)	2 (14)	5 (17)	0	0.6
Median minimal distance (range), mm	1.52 (0.146-2.04)	1.54 (0.004-2.55)	1.73 (1.0-1.89)	1.0

(difference is significant when  $p < 0.05$ ).

Table 1: Baseline characteristics according to the Angle classification. N, number of CBCT images.

Characteristics	Left side (N=26)	Right side (N=23)	P
Median age (range), years	18 (9-60)	16 (9-60)	0.6
Class, n (%)			
Class I	7 (27)	7 (30)	0.9
Class II	15 (58)	14 (61)	
Class III	3 (12)	2 (9)	
[0-0.5 mm], n (%)	3 (12)	4 (17)	0.7
Median surface (range), mm <sup>2</sup>	0 (0-0)	0 (0-0)	1
]0.5-1 mm], n (%)	1 (4)	0	1
Median surface (range), mm <sup>2</sup>	0 (0-0)	0 (0-0)	1
]1-1.5 mm], n (%)	7 (27)	6 (26)	1
Median surface (range), mm <sup>2</sup>	0 (0-22.19)	0 (0-216.25)	0.3
]1.5-2 mm], n (%)	11 (42)	9 (39)	1
Median surface (range), mm <sup>2</sup>	17.69 (0-87.34)	18.81 (0-96.46)	0.8
>2 mm, n (%)	4 (15)	4 (17)	1
Median minimal distance (range), mm	1.56 (0.03-2.55)	1.54 (0.004-19.82)	0.8

(difference is significant when  $p < 0.05$ ).

Table 2: Baseline characteristics according to laterality.

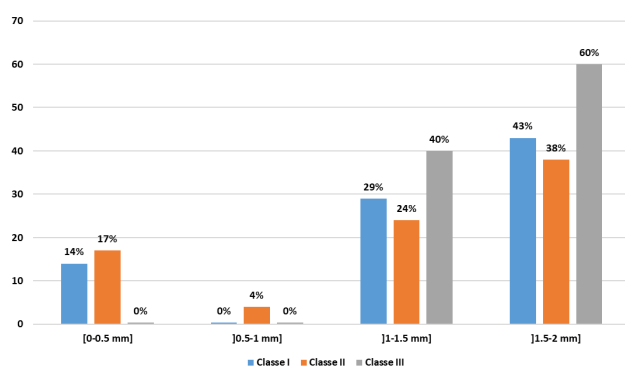
### Dental classification

For a distance between [0 mm-0.5 mm], the percentage of patients in class I was 14%, 17% in class II and no patients in class III. For a distance between ]0.5 mm-1 mm], the percentage of patients was 4% in class II, while no patient belonged to classes I and III. For a distance between ]1 mm-1.5 mm], patients were divided into 29% in class I, 24% in class II, and 40% in class III.

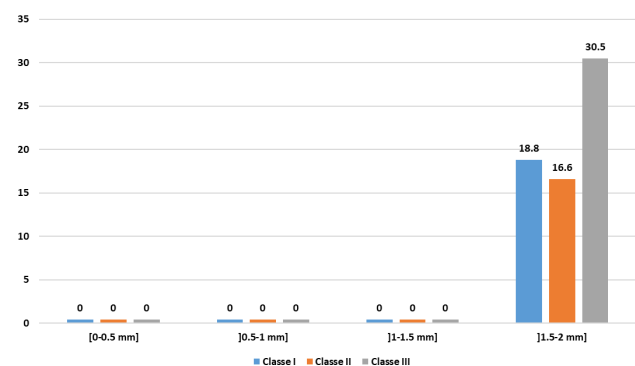
For a distance between ]1.5 mm-2 mm], patients were distributed between 43% in class I, 38% in class II, and 60% in class III (Fig. 3A).

In addition, we analyzed the differences between the joint spaces of the different Angle classes. For a distance of [0 mm;0.5 mm;1mm and 1.5mm] corresponds surfaces of zero values which means that no dental class has a joint space of less than 1.5 mm. In addition,

for the interval between [1.5mm-2 mm], class III has a surface area greater (30.5mm) than that of class I (18.8mm), greater than class II (16.6mm) ( $P > 0.005$ ). In addition, according to the results mentioned in the table 1, the minimum value to which a joint space corresponds is 1.52 mm in class I patients; 1.54 mm in class II patients and 1.73 mm in class III patients ( $P = 0.96$ ) (Fig. 3B).



3A



3B

Fig. 3: Dental classification. (A), Distribution of patients in each class by distance, and (B), Surface in each class by distance

## Discussion

This study is the first to assess the interarticular space of the TMJ in a Lebanese population with different occlusions, by comparing the articular surface in a three-dimensional fashion, in asymptomatic patients belonging to the different classes of Angle. It was conducted to better understand the impact of occlusion on the joint space and the possibility of causing joint diseases.

In fact, understanding the morphology of the TMJ and its relative position in the different classes of Angle (I, II and III) remains a challenge. Understanding the spatial variations of the normal condyle-glenoid cavity could enable clinicians to potentially identify the onset of degenerative joint disease and to establish a better treatment planning where higher than normal values are indicated [11].

Among the morphological structures of TMJ, the position of the mandibular condyle remains the fundamental factor in the diagnosis of joint diseases. Many researchers have proposed that the eccentric position of the condyle in the glenoid fossa is associated with temporomandibular disorders (TMD) [14], while others have questioned its clinical significance due to the wide variations in the condyle position [15].

Dental occlusion is considered to be a primary factor promoting the development of a joint problem after the condylar position. The relationship between dental occlusion and TMD remains an area of debate.[16] Many dentists still believe that occlusion is a primary factor triggering TMD, despite the fact that most current literature conclude otherwise. Indeed, while the community of experts in orofacial pain seems to have adopted a biopsychosocial model of TMD, professionals focusing on the study and restoration of dental occlusion (i.e.orthodontists, prosthodontists, restorative dentists) are historically less inclined to accept concepts that diminish the importance of occlusal dogmas [17].

This study will be a useful reference to redefine the notion of interarticular compression. Detailed measurements of the interarticular space of TMJ in three-dimensional planes of space in different occlusions and their interpretations will contribute to understand joint compressions of TMJ. According to the results obtained in our study, class III patients have the largest surface area (30.47 mm<sup>2</sup>) between the different groups for an interval of ]1.5mm;2mm] which means that patients with this type of malocclusion have a higher risk of developing joint compressions. However, the results did not reach statistical significance; therefore, no firm conclusions could be drawn regarding the correlation between occlusion and joint space and consequently the risk of developing joint disease (including joint compression). Similar to our study, Prabhat et al demonstrated that no difference was found between the condylar process and joint morphology in individuals with normal occlusion class I and malocclusion class II division 1 angle [18].

Similarly, no difference in the surface extent was seen between the left and right sides, with a median value of 0 versus 0 mm<sup>2</sup> ( $P=1$ ) for the interval ]0-0,5 mm], 0 versus 0 mm<sup>2</sup> ( $P=1$ ) for the interval ]0.5-1 mm], 0 versus 0 mm<sup>2</sup> ( $P=0.28$ ) for the interval ]1-1.5 mm], and 17.69 versus 18.81 mm<sup>2</sup> ( $P=0.78$ ) for the interval ]1.5-2 m]. These results are similar to those of Rodriguez et al. who demonstrated that there is no significant difference between the right and left sides for the anterior, upper, and posterior joint sides [9].

On the other hand, our study showed that the minimum distance between the mandibular condyle and the temporal fossa is 1.52 mm for class I patients, 1.54 mm for class II patients and 1.73 mm for class III patients, concluding that the joint space, depending on the results obtained, has a minimum distance equal to or greater than 1.52 mm. Therefore, this value can be considered as the minimum reference value for a joint space.

Our results showed that in the 3 types of malocclusions (class I, II and III), the condyles showed a non-symmetrical centralization in the glenoid fossa on the left or right side of the samples. Miranda et al., and Ricketts also demonstrated that the condyles were not positioned symmetrically when the condyle-fossa relationship was evaluated by measurements of the anterior, upper and posterior articular spaces [11] [17]. This is in line with findings from our analysis where we did not find a large concentration of dimensions less than 1.5 mm<sup>2</sup> in a particular place. Thus, we can conclude that there is a three-dimensional variation of the condylar position because of the anatomical variation, and therefore there is not a particular area statistically who has majored to really say that the mesial, the superior or the inferior has the most number of cases.

Finally, there are some limitations to our study. First, the sample size is small in particular with class III which precludes drawing definitive conclusions and generalizing our findings. Second, the age-range of our cohort (9 to 60 years) is relatively wide and comprises pediatric patients and as well as younger and older patients. Future studies with large sample size and a similar proportion of patients in each category are warranted.

## Conclusion

In conclusion, the three-dimensional evaluation of the condylar position showed that there are no significant differences between articular spaces and different types of occlusions as well as for the right and left joints. The signs and symptoms of DCM are little related to the occlusal relationship and are rather related to a biopsychosocial model. The TMJs of Lebanese subjects are characterized by a non-symmetrical centralization of the condyles in the glenoid fossa on the left or right side of the samples between the different classes of Angle. This study could be considered as reference data for upcoming research in Lebanese population.

## References

1. A. Whyte, R. Boeddinghaus, A. Bartley, and R. Vijayaendra, "Imaging of the temporomandibular joint," *Clin. Radiol.*, vol. 76, no. 1, p. 76.e21-76.e35, Jan. 2021, doi: 10.1016/j.crad.2020.06.020.
2. C. Haddad, S. M. Sayegh, A. El Zoghbi, G. Lawand, and L. Nasr, "The Prevalence and Predicting Factors of Temporomandibular Disorders in COVID-19 Infection: A Cross-Sectional Study," *Cureus*, vol. 14, no. 8, p. e28167, Aug. 2022, doi: 10.7759/cureus.28167.
3. J. Song, M. Cheng, Y. Qian, and F. Chu, "Cone-beam CT evaluation of temporomandibular joint in permanent dentition according to Angle's classification," *Oral Radiol.*, vol. 36, no. 3, pp. 261–266, Jul. 2020, doi: 10.1007/s11282-019-00403-3.
4. M. Lin, Y. Xu, H. Wu, H. Zhang, S. Wang, and K. Qi, "Comparative cone-beam computed tomography evaluation of temporomandibular joint position and morphology in female patients with skeletal class II malocclusion," *J. Int. Med. Res.*, vol. 48, no. 2, p. 300060519892388, Feb. 2020, doi: 10.1177/0300060519892388.
5. A. Youssef, J. Hobeiche, A. El Zoghbi, R. Mortada, and Z. Salameh, "Bruxism and implant: where are we? A systematic review," *Bull. Natl. Res. Cent.*, vol. 46, no. 1, pp. 1–9, 2022.
6. S. Campbell and G. Goldstein, "Angle's Classification - A Prosthodontic Consideration: Best Evidence Consensus Statement," *J. Prosthodont. Off. J. Am. Coll. Prosthodont.*, Dec. 2020, doi: 10.1111/jopr.13307.
7. A. E. Zoghby, J.-P. Re, and C. Perez, "Functional harmony between the sagittal condylar path inclination and the anterior guidance inclination," *Int. J. Stomatol. Occlusion Med.*, vol. 2, no. 3, pp. 131–136, 2009.
8. J.-M. Chae *et al.*, "Evaluation of condyle-fossa relationships in adolescents with various skeletal patterns using cone-beam computed tomography," *Angle Orthod.*, vol. 90, no. 2, pp. 224–232, Mar. 2020, doi: 10.2319/052919-369.1.
9. A. F. Rodrigues, M. R. Fraga, and R. W. F. Vitral, "Computed tomography evaluation of the temporomandibular joint in Class II Division 1 and Class III malocclusion patients: condylar symmetry and condyle-fossa relationship," *Am. J. Orthod. Dentofac. Orthop. Off. Publ. Am. Assoc. Orthod. Its Const. Soc. Am. Board Orthod.*, vol. 136, no. 2, pp. 199–206, Aug. 2009, doi: 10.1016/j.ajodo.2007.07.033.
10. C. Marty, "La classe II division 2 est-elle un facteur de risque dans la dysfonction craniomandibulaire?," p. 80.
11. J. M. Arieta-Miranda, M. Silva-Valencia, C. Flores-Mir, N. A. Paredes-Sampen, and L. E. Arriola-Guillen, "Spatial analysis of condyle position according to sagittal skeletal relationship, assessed by cone beam computed tomography," *Prog. Orthod.*, vol. 14, p. 36, Oct. 2013, doi: 10.1186/2196-1042-14-36.
12. S. Barghan, S. Tetradis, and S. Mallya, "Application of cone beam computed tomography for assessment of the temporomandibular joints," *Aust. Dent. J.*, vol. 57 Suppl 1, pp. 109–118, Mar. 2012, doi: 10.1111/j.1834-7819.2011.01663.x.
13. R. Abboud and J. Hobeiche, "Rôle du cone beam dans le diagnostic des pathologies des articulations temporo-mandibulaires. Présentation de trois cas cliniques," *Int. Arab J. Dent.*, vol. 3, no. 3, p. 3, 2012.
14. A. El Zoghbi, M. Halimi, J. Hobeiche, and C. Haddad, "Effect of occlusal splints on posture balance in patients with temporomandibular joint disorder: A prospective study," *J Contemp Dent Pr.*, vol. 22, pp. 615–619, 2021.
15. M. Imanimoghaddam, A. S. Madani, P. Mahdavi, A. Bagherpour, M. Darijani, and H. Ebrahimnejad, "Evaluation of condylar positions in patients with temporomandibular disorders: A cone-beam computed tomographic study," *Imaging Sci. Dent.*, vol. 46, no. 2, pp. 127–131, Jun. 2016, doi: 10.5624/isd.2016.46.2.127.
16. N. Boscato, G. G. Nascimento, F. R. M. Leite, B. L. Horta, P. Svensson, and F. F. Demarco, "Role of occlusal factors on probable bruxism and orofacial pain: Data from the 1982 Pelotas birth cohort study," *J. Dent.*, vol. 113, p. 103788, Oct. 2021, doi: 10.1016/j.jdent.2021.103788.
17. D. Manfredini, L. Lombardo, and G. Siciliani, "Temporomandibular disorders and dental occlusion. A systematic review of association studies: end of an era?," *J. Oral Rehabil.*, vol. 44, no. 11, pp. 908–923, Nov. 2017, doi: 10.1111/joor.12531.
18. K. C. Prabhat, S. Kumar Verma, S. Maheshwari, I. Ahmad, and M. Tariq, "Computed Tomography Evaluation of Craniomandibular Articulation in Class II Division 1 Malocclusion and Class I Normal Occlusion Subjects in North Indian Population," *ISRNDent.*, vol. 2012, p. 312-331, 2012, doi: 10.5402/2012/312031.