

## INTEREST OF ATTACHMENT USE IN THE TREATMENT OF A LARGE EDENTULOUS RIDGE: A CLINICAL REPORT

Ines Saadellaoui\* | Yosra Mabrouk\*\* | Lamia Mansour\*\*\* | Mounir Trabelsi\*\*\*\*

### Abstract

The oral rehabilitation of a large edentulous ridge is complicated by mechanical and esthetic problems. The use of an axial attachment as a complementary retention device has many benefits on the prosthetic balance and the esthetically integration of the prosthesis. To manage this procedure successfully, the rigorous study of the prosthetic space and the mastering of the implementations' steps are necessary. The purpose of this work was to present through a clinical case the various steps of the realization of a metallic framework removable partial denture with an axial attachment and to underline the contribution of this device in the case of a large edentulous ridge.

**Key words:** Metallic framework removable partial denture; Axial attachment; Partial edentulism

IAJD 2022;13(1): 30-35.

## INTÉRÊT DE L'UTILISATION DES ATTACHEMENTS DANS LE TRAITEMENT DES GRANDES CRÊTES ÉDENTÉES : A PROPOS D'UN CAS CLINIQUE

### Résumé

La réhabilitation prothétique d'un édentement partiel de grande étendue est compliquée par des problèmes mécaniques et esthétiques. L'utilisation d'un attachement axial comme dispositif de rétention complémentaire présente de nombreux avantages sur l'équilibre prothétique et l'intégration esthétique de la prothèse. Pour bien mener cette procédure, l'étude rigoureuse de l'espace prothétique et la maîtrise des étapes de mise en œuvre sont nécessaires. L'objectif de ce travail était de présenter à travers un cas clinique les différentes étapes de la réalisation d'une prothèse partielle amovible à châssis métallique avec un attachement axial et de souligner l'apport de ce dispositif dans le cas d'un édentement de grande étendue.

**Mots clés :** Prothèse partielle amovible à châssis métallique ; Attachement axial; Édentement partiel

IAJD 2022;13(1): 30-35.

\* DDS, resident dentist, removable prosthetics department, ABCDF laboratory, faculty of dental medicine, university of Monastir, Tunisia  
E-mail: saadellaouiines5@gmail.com

\*\* DDS, associate professor, removable prosthetics department, ABCDF laboratory, faculty of dental medicine, university of Monastir, Tunisia  
E-mail: mabroukyosra@gmail.com

\*\*\* DDS, professor, removable prosthetics department, ABCDF laboratory, faculty of dental medicine, university of Monastir, Tunisia  
E-mail: mansourlamia64@yahoo.fr

\*\*\*\* DDS, PhD, ABCDF laboratory, faculty of dental medicine, university of Monastir, Tunisia  
E-mail: mounir.trabelsi@fmdm.rnu.tn

## INTRODUCTION

The prosthetic rehabilitation of edentulous patients induces many biomechanical and esthetic problems especially for a large edentulous ridge. In one hand, the difference in compressibility between mucosa and teeth generates rocking motions, which may be factors for discomfort for patients [1]. On the other hand, in the anterior region, the visibility of clasps has an unsightly aspect that makes them unaesthetic [2].

The attachment can be used to substitute the vestibular arm of the anterior clasps. Using these devices with residual roots has a various advantages. It improves considerably their esthetic and masticatory effectiveness. It contributes to the conservation of the alveolar bone and proprioception. In addition, the use of this retention device has improved prosthetic balance in a large edentulous ridge and it reduces the clasp's visibility, which guarantees the good integration of the removable prosthesis [3].

The aim of this paper is to present through a clinical case the different steps of the realization of a metallic framework removable partial denture with an axial attachment and to underline the contribution of this device in the case of a large edentulous ridge.

## CASE PRESENTATION

A fifty-seven year old patient, in a good general health, comes in consultation in the prosthetic department of the university dental clinic of Monastir in Tunisia, for an oral rehabilitation with functional and esthetic requests.

### Clinical examination:

The examination of the maxillary arch revealed a large edentulism which is bordered by 14, 23 and 28 (Fig. 1). The mandibular arch was completely toothed (Fig. 2).

The missing teeth were 15, 16, 17, 18, 24, 25, 26 and 27. The 28 was decayed with an exposed pulp. Two crowns with vestibular inlays on 13 and 14. The prosthetic joint was judged

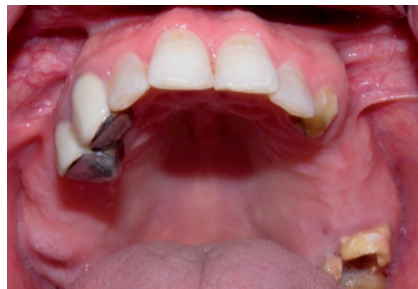

Fig. 1: Endo-oral view of the maxillary arch

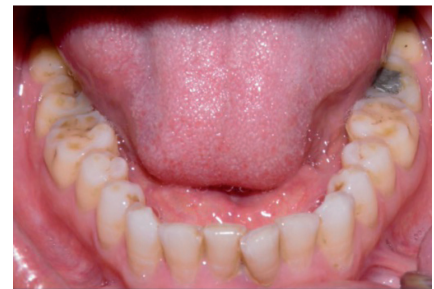

Fig. 2: Endo-oral view of the mandibular arch

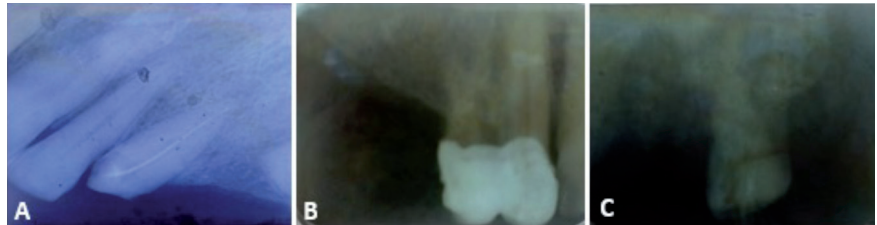

Fig. 3: Radiological examination of the abutment teeth

A. Retro alveolar X-Ray of 23; B. Retro alveolar X-Ray of 13 and 14; C. Retro alveolar X-Ray of 28

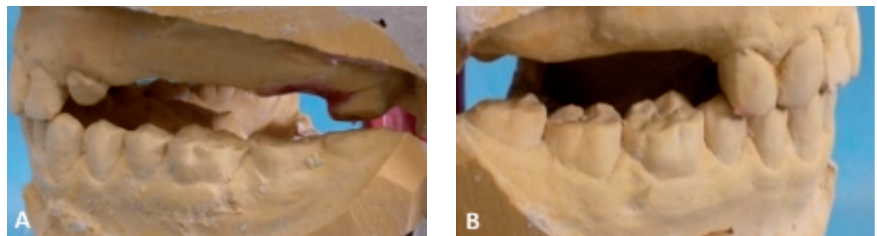


Fig. 4: Analysis of study casts mounted in articulator at centric relation and correct OVD

A: Left lateral view; B: Right lateral view

hermetic. The 23 is a dilapidated tooth. The examination of the bone mucosa surfaces revealed a firm and adherent fibro mucosa with no undercuts. When smiling, the patient only releases the six anterior maxillary teeth.

### Radiological examination:

The radiological examination revealed a Radiological crown radiological root ratio less than 1 for all teeth except 28 which has a Radiological crown radiological root ratio equal to 1 and a periodontal enlargement (Fig. 3 A;B;C).

### Mounting of study casts on articulator:

The prosthetic usable occlusal height was judged sufficient (Fig. 4 A; B).

### Prosthetic decision:

Different types of supra radicular axial attachments are used responding to various clinical situations. We can classify them into two types of axial intra-radicular attachments:

- Rigid attachments, which only allow an axial movement. It transmits all of the forces received by the PPA to the load-bearing teeth of the axial attachment. These attachments are mainly used when looking for a dental support.

- Hinged link attachments, which allow a non-rigid connection. The shape of the matrix leaves a space around the patrice reducing the stresses on the bearing teeth by making the fibro-mucosa participate in the prosthetic support.

A metallic framework removable partial denture (RPD) with

supra-radicular attachment was indicated. An axial device was chosen to be connected with the left canine residual root (Rhein 83). The used system presents two parts: female and male. The female part incorporate two components: a plastic sheath and a burn-out housing (Fig. 5).

### The prosthetic project analysis and simulation:

The casts were analyzed on the dental surveyor in order to determine the adequate insertion axis. This axis was marked with graphite mine in the casts' base to be found by the laboratory technician. It will be used to insert the attachment. Before starting prosthetic procedures, a therapeutic plan was simulated with wax on diagnostic casts, this simulation allowed prevision of esthetic and functional aspects of prosthetic outcome and facilitated its explanation to the patient. A tooth mounting on wax is produced and a key is made with high viscosity silicone to visualize the available prosthetic space to incorporate the assembly of the complementary retention system.

One the decision is confirmed, it was exposed to the patient to have his consent.

The conception of the framework was made according to biomechanical and esthetic considerations. At the maxillary, the design of the metal framework's components was carried out respecting the axis of rotation. The clasps were chosen and strategically placed in accordance with the edentulism's configuration (Fig. 6).

An endodontic treatment of 28 was realized for prosthetic reasons.

## Prosthetic treatment

### Preparation of the pillar root

To receive the axial device, the residual root of the 23 should be prepared. The dental crown was sectioned 2mm under the gingival level. The occlusal preparation of the cervical plate followed the gingival scallop profile. A chamfer peripheral preparation was done. Two-thirds of the root height

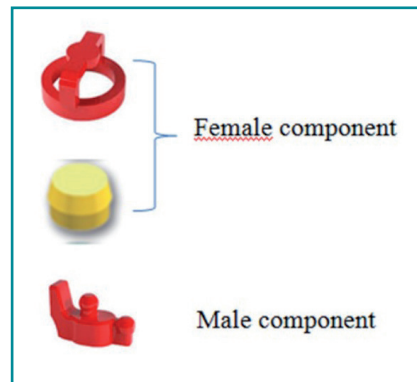


Fig. 5: The components of RHEIN 83 axial attachment

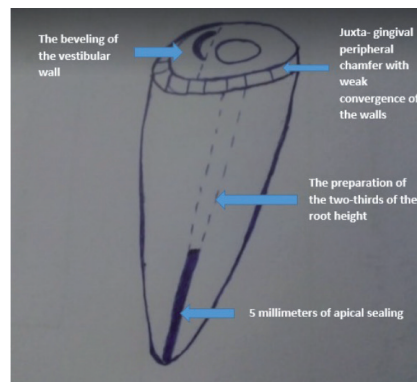


Fig. 7: The Richmond cervical plate

were prepared to receive the radicular anchorage. A minimum of 3 to 5 millimeter of the apical sealing should be maintained. The occlusal design of the cervical plate was prepared according to Richmond recommendations: the buccal wall is beveled while the palatal wall is straight. The buccal wall has a notch, which prevents the rotation of the cope (Fig. 7). The peripheral preparation of 28 was realized in order to receive a metallic crown.

### Global impression

An impression of the preparations is made using a commercial tray and a high and low viscosity silicone according to the simultaneous double mixing technique (Fig. 8). With the obtained casts, the record of the patient occlusion was done at centric relation and a correct occlusion vertical dimension (OVD).

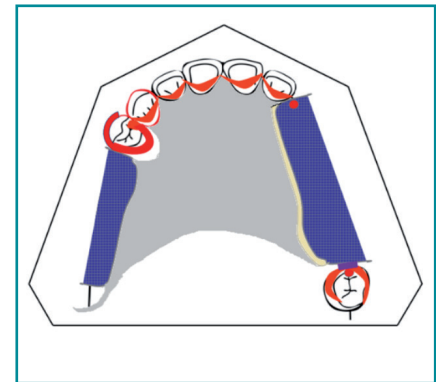


Fig. 6: The maxillary framework layout

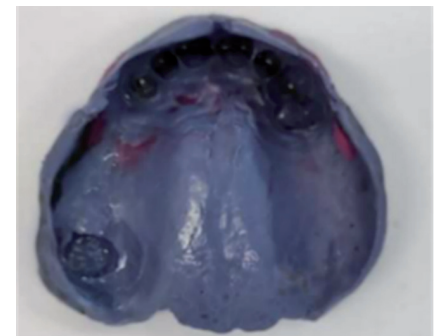


Fig. 8: Global impression

### Attachment fixation

The fixing of the male part of the axial attachment on sub-root coping is made in the laboratory, through specific instruments mounted on the dental surveyor (Fig. 9 A). The validation of the attachment choice and position was done using the fabricated silicone key (Fig. 9 B). The obtained wax model was set into the cylinder then we proceed to the casting (Fig. 9 C; D).

The coping fitted with attachment is checked on the cast using the silicone key and then validated in the mouth (Fig. 10 A; B; C).

The fixing of the male part of the axial attachment; B. The verification of the available prosthetic space; C. The sub-root coping fitted with the male part; D. The male part overcomes the root post cope after casting

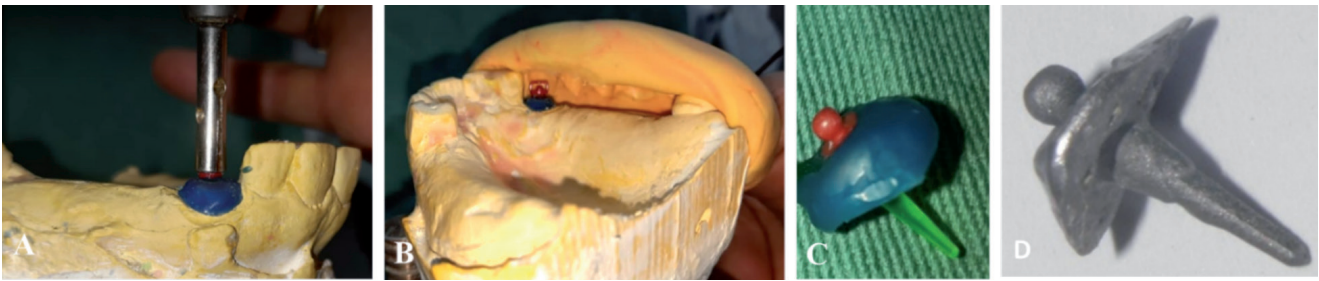


Fig. 9: Laboratory steps

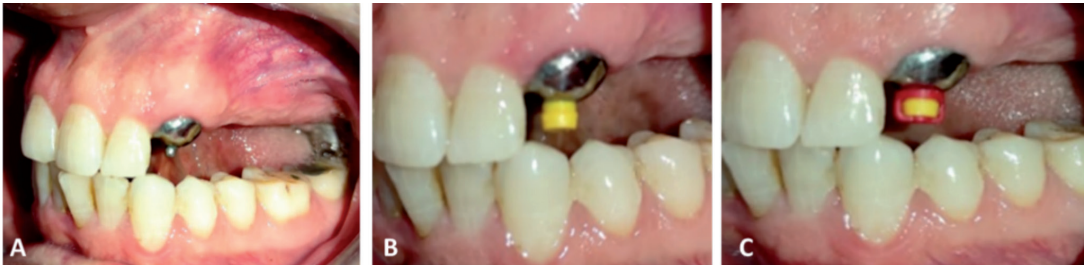

Fig. 10: Validation of the axial attachment in the mouth  
A, B and C. The different components of the axial attachment are tested in the mouth

### Final impression

The metallic crown is sealed on the 28 and a full impression of the bone mucosa support surfaces is made using individual tray, which is elaborated on the cast developed after the primary impression and a medium viscosity polyether. Consequently, the coping fitted with attachment is integrated in the impression (Fig. 11).

### The realization of the metallic framework RPD

In the laboratory, the metallic framework removable partial denture is realized in different steps (Fig. 12 A, B). After that, it is validated in mouth and the jaw relationship at centric relation-OVD correct is recorded. The color of the artificial teeth is chosen and a tooth mounting on wax is realized.

After the validation of the tooth mounting in the mouth, the resin of the prosthesis is cured. The coping fitted with axial attachment is sealed on dental root (Fig. 13). The metallic framework RPD is integrated in the mouth. During this step, the intrados of the removable partial denture is recessed in front of the attachment. Occlusion is controlled and equilibration is carried out.

The female part of the axial attachment is integrated in the prosthetic intrados using chemical curing resin under occlusal pressure (Fig.14 A; B; C).

The prosthetic final result was satisfying in esthetic and functional level and the patient was very pleased with the result (fig. 15).

Placing the female part of the axial attachment; B. Putting the resin into the RPD intrados; C. RPD with the female part of the RHEIN 83 axial attachment

## DISCUSSION

In case of a large edentulous ridge, the Prosthetic rehabilitation by a metallic frame removable partial prosthesis requires its integration in a correct occlusal context taking into account esthetic as well as biomechanical factors necessary for prosthetic balance. It is important to analyze the distribution of the abutment teeth and the rotation axis.

The edentulous with large extensions are characterized by the obliquity of the rotation axis, which generates a rotational movement with harmful forces for the bone mucosa support surfaces as well as the abutment teeth [4].

The use of resilient attachment allows at least a vertical translation and a distal rotation which certainly have a benefit effect on the distribution of masticatory forces between hard tissues and soft tissues [4, 5].

The success of the attachment's implementation is based on different points:

The mounting of study casts on articulator analysis, which allows the evaluation of the available prosthetic space and the choice of the attachment's volume; the prosthetic project simulation, which is a key step in the prosthetic management. It allows the testing of the decision feasibility and it facilitates the prosthetic project explanation for the patient; the dental surveyor analysis which is an important step in order to choose the insertion axis and to fix the male part of attachment using different instruments.

In our case, the use of the axial attachment helps to preserve the alveolar bone and the proprioception from a biological point of view. Mechanically, it improves a prosthetic balance in the large edentulous ridge. Esthetically, it reduces the clasp's visibility [3, 6, 7].

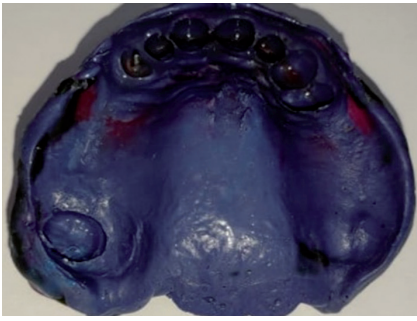

Fig. 11: Final impression

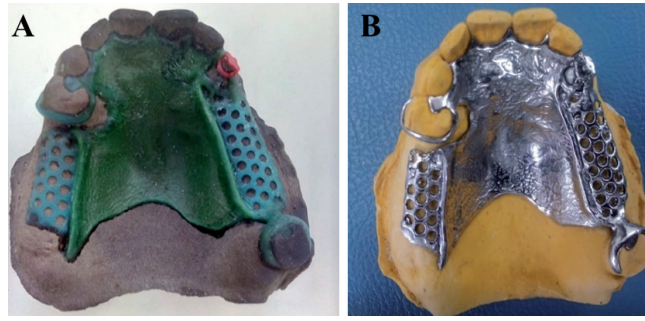
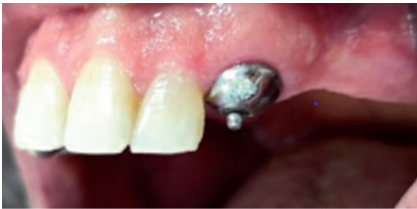Fig. 12: Realization of the RPD framework in the laboratory  
A. Sculpture of wax pattern; B. Metallic framework

Fig. 13: The sealing of the axial attachment

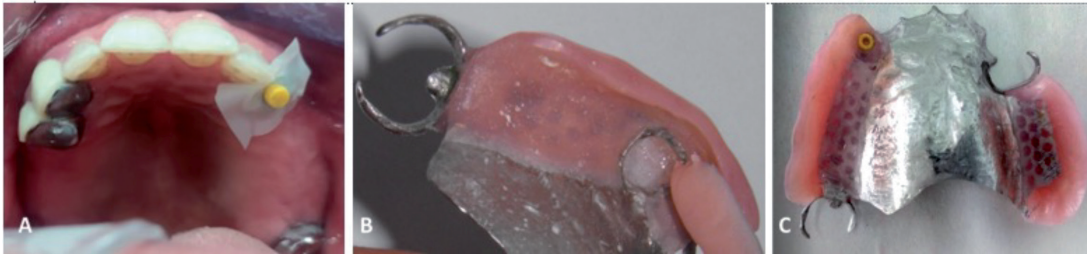

Fig. 14: The incorporation of the female part of the axial attachment into the maxillary RPD intrados

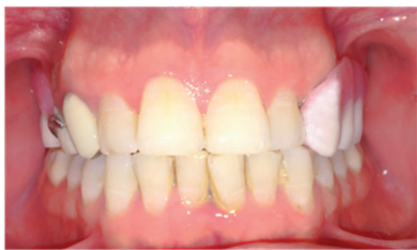

Fig. 15: Esthetic and functional integration of the removable partial denture

The treatment longevity depends on the patient's occlusal context, the constraints on attachments, the motivation of the patient and the periodic check-ups.

Vermeulen (1984) conducted longitudinal studies on patients with PAP, treated in a dental school, with resin partial dentures, with partial dentures having a metal frame and hooks, and 183 with PAP with attachments of which 40% were ball attachments. The average lifespan of resin partial dentures was 3 years, approximately 10 years for partial dentures with a metal frame and hooks, and 8 years for PAP with attachments. Vermeulen noted technical problems in about 50% of prostheses with attachment. Because the study dealt with different types

of attachments, it is difficult to draw more precise conclusions [8].

## CONCLUSIONS

The integration of an axial attachment to the metallic framework removable partial denture is a therapeutic choice to manage both mechanical and esthetic factors in the case of edentulous with large extension. However, the success of the treatment implies a preliminary and rigorous study of the prosthetic case and a mastery of the stages of prosthetic implementation.

## References

1. Bouraoui S, Mansour L, Trabelsi M, Chater N. Exploitation of natural and artificial roots in removable prosthesis: clinical cases. *AJDI*, [S.l.], n. 5, nov. 2016; 23-35. ISSN 2509-2057. Available at: <https://revues.imist.ma/index.php/AJDI/article/view/6799/4074>. Accessed September 28, 2021
2. Benyahia H, Fajri L, Rohkssi H, Merzouk N, Berrada S. La prothèse composite dans la gestion esthétique et biomécanique d'un édentement unilatéral de grande étendue. *Stratégie prothétique* mai-juin 2016, Vol 16, n°3 :177-184
3. Fajri L, Hamzaoui S, Berzouk N, Elmohtarim B. Removable partial prosthesis from analysis to realization. *AJDI*, [S.l.], n. 19, june 2021. ISSN 2509-2057. Available at: <https://revues.imist.ma/index.php/AJDI/article/view/26174/13759>. Accessed September 28, 2021
4. Guetat R. La prothèse composite complexe face aux édentements terminaux [thèse]. Monastir : Faculté de médecine dentaire ; 2017
5. Fajri L, Benfdil F, El Mohtarim B, Abdedine A. Attachement axial en prothèse amovible partielle: Réalisation clinique temps par temps. *Les cahiers de prothèse* 2007;139:43-49
6. Bagui M, Fajri L, Benfdil F, El Mohtarem B, Merzouk N. La prothèse amovible partielle supra radiculaire avec attachement axial: aspects théoriques et pratiques. *Stratégie prothétique* mai-juin 2016, Vol 16, n°3:215- 223
7. Sabir S, Slaoui J, Merzouk N, Bentahar O. L'intégration d'un attachement axial à une prothèse adjointe partielle métallique : Intérêts thérapeutiques. *IAJD* 2020;11(1):24-32
8. *Durée de vie des prothèses sur attachement. Prothèse dentaire principe et stratégie thérapeutique* (Ed Masson) Available at: <https://www.dentisfuturis.com/dure-de-vie-des-protheses-sur-attachement/>. Accessed August 23, 2021