

FOLLICULAR CYST ASSOCIATED WITH A *DE NOVO* EDA MUTATION: A CASE REPORT.

Rami Abou Khalil* | Tony Yamine** | Nadim Mokbel*** | Chantal Farra**** | Carole Chakar*****

Abstract

A dentigerous /follicular cyst is an odontogenic cyst associated with the crown of a non-erupted or partially erupted tooth. The exact histogenesis of this cyst remains unknown. Multiple signaling pathways and cellular modification are involved in its formation.

The aim of this article is to report a case of a 9-year-old boy with a de novo EDA mutation, having an extreme oligodontia accompanied by the formation of a follicular cyst.

This study hypothesizes the existence of causative relation between the EDA mutation and the cyst development around the impacted tooth.

Keywords:

Dentigerous cysts; Ectodysplasin A; Non-syndromic oligodontia; Novel mutation; Tooth agenesis

IAJD 2021;12(2): 108-113.

KYSTE FOLLICULAIRE DENTAIRE ASSOCIÉ À UNE MUTATION DE NOVO DE L'EDA: A PROPOS D'UN CAS CLINIQUE

Résumé

Un kyste dentigère/folliculaire est un kyste odontogène associé à la couronne d'une dent sans éruption ou partiellement en éruption. L'histogénèse exacte de ce kyste reste inconnue. De multiples voies de signalisation et des modifications cellulaires sont impliquées dans sa formation.

Le but de cet article est de rapporter le cas d'un garçon de 9 ans porteur d'une mutation de novo de l'EDA, présentant une oligodontie extrême accompagnée de la formation d'un kyste folliculaire.

Cette étude émet l'hypothèse de l'existence d'une relation causale entre la mutation EDA et le développement du kyste autour de la dent incluse.

Mots clés : Kystes dentigères ; ectodysplasine A ; Oligodontie non syndromique ; Nouvelle mutation ; Agénésie dentaire

IAJD 2021;12(2): 108-113.

* DDS, MSc
Department of periodontology
Saint-Joseph University
Rami.cirnu@gmail.com

** Medical Genetics Unit (UGM)
Saint Joseph University
Tony.yamine@usj.edu.lb

*** DDS, MSc, PhD.
Department of periodontology
Saint-Joseph University
nadim.mokbel@gmail.com
nadim.mokbel@usj.edu.lb

**** MD,
Medical Genetics Unit (UGM)
Faculty of Medicine
Saint Joseph University
chantal.farra@usj.edu.lb

***** DDS, MSc, PhD
Department of periodontology
Saint-Joseph University
Carole.chakar@hotmail.com
Carole.chakar@usj.edu.lb

Introduction

Tooth agenesis is a common pathology in dentistry with the most severe type being Oligodontia, defined as the absence of six or more permanent teeth excluding third molars. It reportedly affects around 0.08–0.16% of the Caucasian population, and 0.1% to 0.2% of the worldwide population [1].

Tooth agenesis may occur either, as a non-syndromic familial trait, or as a sporadic finding. Non-syndromic oligodontia is found to be associated with mutations in a number of genes including *Msx1*, *PAX9*, *Wnt10A*, *Nemo*, *KRT17*, and ectodysplasin A (EDA) [2].

EDA spans over a 425 Kb segment on chromosome X q 12-13. 1, and encodes two soluble proteins, EDA1 and EDA2.

EDA1 interacts with its specific receptor (EDAR). The interaction between its death domain and the adaptor protein (EDAR-ADD) results in NF- κ B translocation into the nucleus. This induces the transcription of many essential genes responsible for initiation and differentiation of ectodermal derived tissues including skin, hair, teeth and sweat glands [3].

During odontogenesis, crown formation becomes visible throughout the cap and bell stages. It is regulated by the enamel knots with the expression of the fibroblast growth factor (FGF 3,4,9 and 20). The Placode as well as the primary and secondary enamel knots express EDAR, thus they are controlled by the EDA signaling pathway [4].

In mice, lack of functional EDA was associated with the absence of third molars or incisors indicating the role of *Eda* in the function of placodes and enamel knots [5].

This means that the signaling pathway provided by the interaction [EDA-EDAR-EDARADD-NF- κ B] is responsible for the cell migration and differentiation in the odontogenesis [3].

Additionally, the FGF plays a major role in inducing the expression of *Msx1* – a downstream component of the Bone Morphogenic Protein (BMP)

signaling pathway – that is regulated by the NF- κ B factor. Likewise, alteration of the EDA pathway in ectodermal organogenesis causes significant decrease in BMP expression, which is required for neural crest cell proliferation [6]. Therefore, EDA mutations that alter normal FGF signaling, as well as EDA-NF- κ B-BMP-MSX interactions, may lead to disturbances in teeth development.

In non-syndromic oligodontia, a mutation will cause the retaining of some receptors-signaling activity leading to a partial loss of EDA function. Suggesting that the threshold for EDA signaling in tooth development maybe higher than that of the other EDA-dependent structures such as hair, sweat glands and skin.

We herein report a child with a de novo EDA mutation, presenting with non-syndromic oligodontia and a cyst developing around an impacted tooth and no other symptoms of HED.

Case Report

Patient recruitment and phenotype analysis.

We report a case of a 9-year-old Caucasian boy (M.Z.), presented in 2016 to the private clinic. The patient had a normal physical and intellectual development.

Based on initial dental radiographs findings (Figure 1), intra-oral and clinical examination (Figure 2), and the absence of any clinical features of hypohidrotic ectodermal dysplasia (HED) – such as scant hair, missing or reduced eye brows, and absent or severely low sweating- (the patient was diagnosed with non-syndromic oligodontia of both deciduous and permanent dentition).

In the deciduous dentition, all lower teeth were absent and only laterals (#52-62) and second molars (#55-65) of the upper arch were present. In the permanent dentition, the patient was missing 23 teeth, including all lower teeth with the exception of the 1st molar (#46) which was still impacted, and all upper teeth with the exception of the 2 centrals (#11-21) and the

1st molars (#26-16). The remaining permanent teeth were normal in structure, shape and size.

Intraoral examination showed normal buccal and lingual mucosa, gingiva, palate and tongue. Hair, skin, nails were normal and the patient reported normal sweating with no history of dry mouth, heat intolerance or any respiratory tract infections. Clinical examination of the available family members (parents and 3 siblings) did not exhibit any unusual clinical findings or dental abnormalities with normal primary and permanent dentition.

Two years after the initial consultation (2018), upon a follow-up appointment, a panoramic x-ray (Figure 3) and CBCT scan (Figure 4) were conducted to evaluate tooth #46. It showed a unilocular radiolucency (width: 23mm; length: 21mm) around the crown of the lower impacted 1st molar (# 46), attached to it at the cemento-enamel junction (CEJ), with a clear external limit. The cyst was described as an odontogenic cyst (dentigerous/follicular cysts). The patient did not exhibit any signs of sensory nerve involvement, despite the close proximity between the cyst and the alveolar nerve. (Figure 4- A, B).

Two weeks later, the cyst was enucleated with the extraction of the involved tooth using piezo surgery, with no adverse effect on the alveolar nerve or signs of paresthesia (Figure 5).

Global Treatment Plan.

After radiological (panoramic and profile x-rays) and clinical analysis, a treatment plan was elaborated:

Initial treatment for the existing teeth was initiated (cleaning, oral hygiene instruction, and protection caps on the molars # 55-65).

Palatal expander appliance was mounted for the expansion of the upper arch and to open the space between centrals.

Nance palatal arch appliance was used with acrylic teeth in order to assure the patient with an acceptable esthetical and functional temporary treatment (Figure 6).

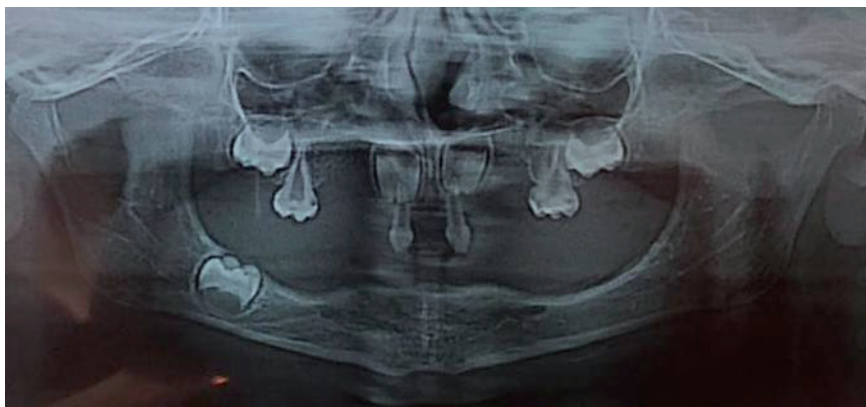


Figure 1: Initial radiographic test: Panoramic x-ray showing the teeth present in the patient mouth.

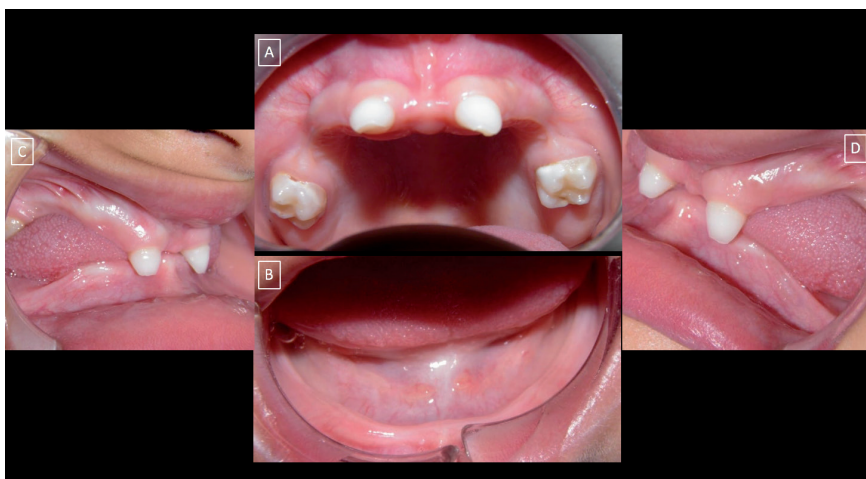


Figure 2: Intra-oral photographic images: (A) upper arch; (B) lower arch; (C-D) lateral intra-oral view.

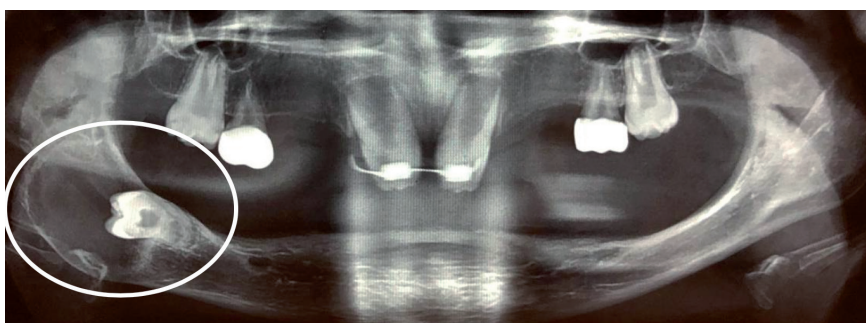


Figure 3: Panoramic x-ray of the patient in 2018: White circle showing the cystic formation around the impacted tooth.

Appliance was removed once per month for cleaning and then rebanded.

Orthodontic treatment was used to have a correct position/alignment of the upper centrals (# 11-21).

A temporary fixed acrylic bridge with a metallic lingual band was proposed for the lower arch, to be mounted over 5 mini screws -orthodontic mini-implants - (1.2 x 6-8 mm) in order to assure an adequate function and esthetical temporary fixed outcome until the patient is able to have an adequate prosthetical/implant rehabilitation.

Genetic analysis

Because of the clinical presentation of oligodontia, the EDA and WNT10A genes were analysed through direct sequencing of PCR products followed by sequencing on an ABI 3130 automated capillary DNA sequencer (Applied Biosystems). DNA sequences were compared to reference sequences using Chromas Pro v1.22 (Technelysium, Queensland, Australia). Analysis of the proband's sequence revealed the presence of a hemizygote missense variant p. E67G (c.200A>G) in EDA gene 12 not found in the publically available Human Gene Mutation Database. Computational evidence including MutationTaster, REVEL and SIFT support a deleterious effect of this variant and as per ACMG recommendations, it is classified as likely pathogenic [7].

The variant was not detected in the mother. It therefore occurred as a de novo genetic event in the proband.

Discussion

The pathological process and histogenesis involved in the development of follicular cysts is still not clearly delineated. Three key elements are required in the process: capacity for bone resorption, a source of epithelium, and stimulus for epithelial proliferation and cyst growth.

The enamel knots throughout the normal odontogenesis, initiate and regulate the folding of the epithelium

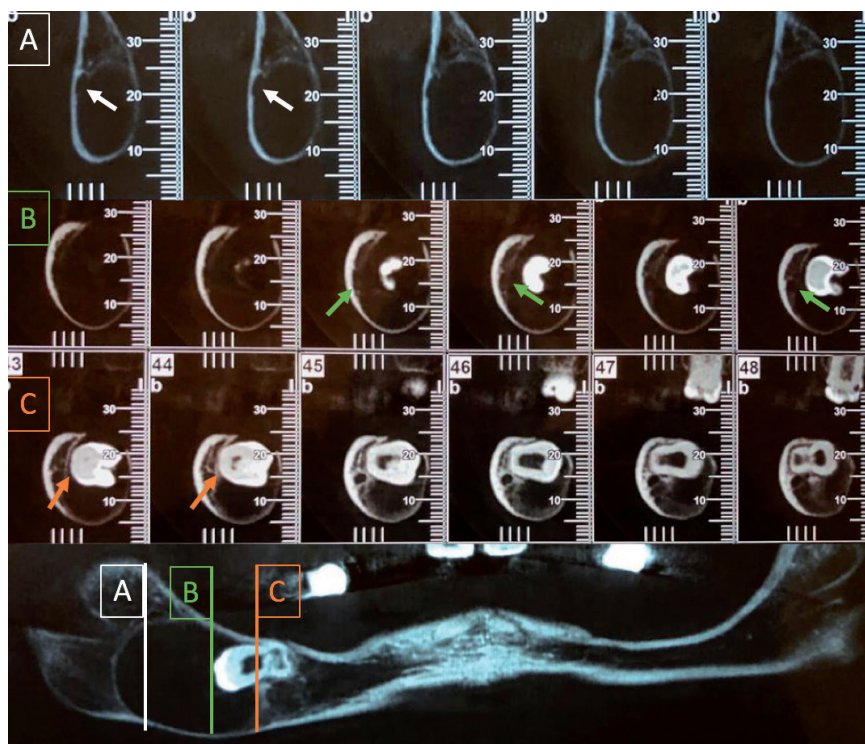


Figure 4: Cone beam computed tomography of the mandible:

Lower part: Panoramic view of the right mandible: showing the 1mm cut levels:

- A: Sagittal 1mm cut of the radiolucency at its distal part; Thick white arrows show the proximity between the cystic and the alveolar nerve.
 B: Sagittal 1mm cut of the radiolucency at the beginning of the tooth visibility inside the cyst. Thick green arrows show the proximity between the cystic formation and the alveolar nerve.
 C: Sagittal 1mm cut of the radiolucency at the cemento-enamel junction (CEJ) of the impacted tooth. Thick orange arrows show the area the CEJ with the radiolucency closure around it.

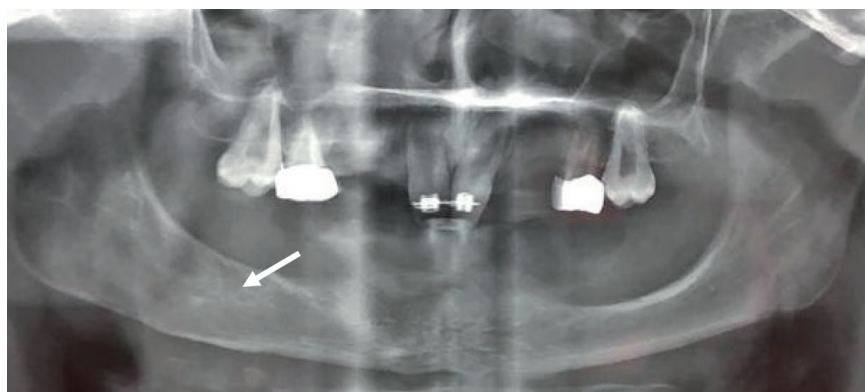


Figure 5: Panoramic x-ray taken 1 month after the impacted tooth extraction and cyst enucleation. White arrow showing the previous position of the impacted tooth.

by stimulating the surrounding epithelium to proliferate, and repressing their own proliferation. This is achieved through an over-expression of the cyclin-dependent kinase inhibitor p21 and lack of FGF receptors making them insensitive to the proliferation signals [8].

During the cap and bell stages the epithelial bud envelops the underlying dental mesenchyme, leading to the emergence of the cervical loop. When root formation starts, the cervical loop will initiate a degenerative structural

modification, leaving only a double layer of basal epithelium known as Hertwig's epithelial root sheath (HERS). The latter will dissolve progressively resulting in a reduced enamel epithelium and rests of Malassez with a limited growth capacity [9].

In the case of an EDA mutation, the enamel knots degeneration process could be altered, in addition to an over-expression of the Reduced Enamel Epithelium and Rests of Malassez.

resulting in the formation of squamous epithelium, and generating

the primer source of epithelium [9] involved in the development of a follicular/ dentigerous cyst.

Furthermore, the bone homeostasis capacity which is the balance between the resorption by the osteoclast and formation by the osteoblast, is controlled by the RANK/RANKL system. The receptor activator of nuclear factor- κ B ligand (RANKL) – part of the TNF superfamily- is a ligand for its receptor (RANK) which can be found on osteoclast progenitor cells. This interaction, [RANK-RANKL] activates

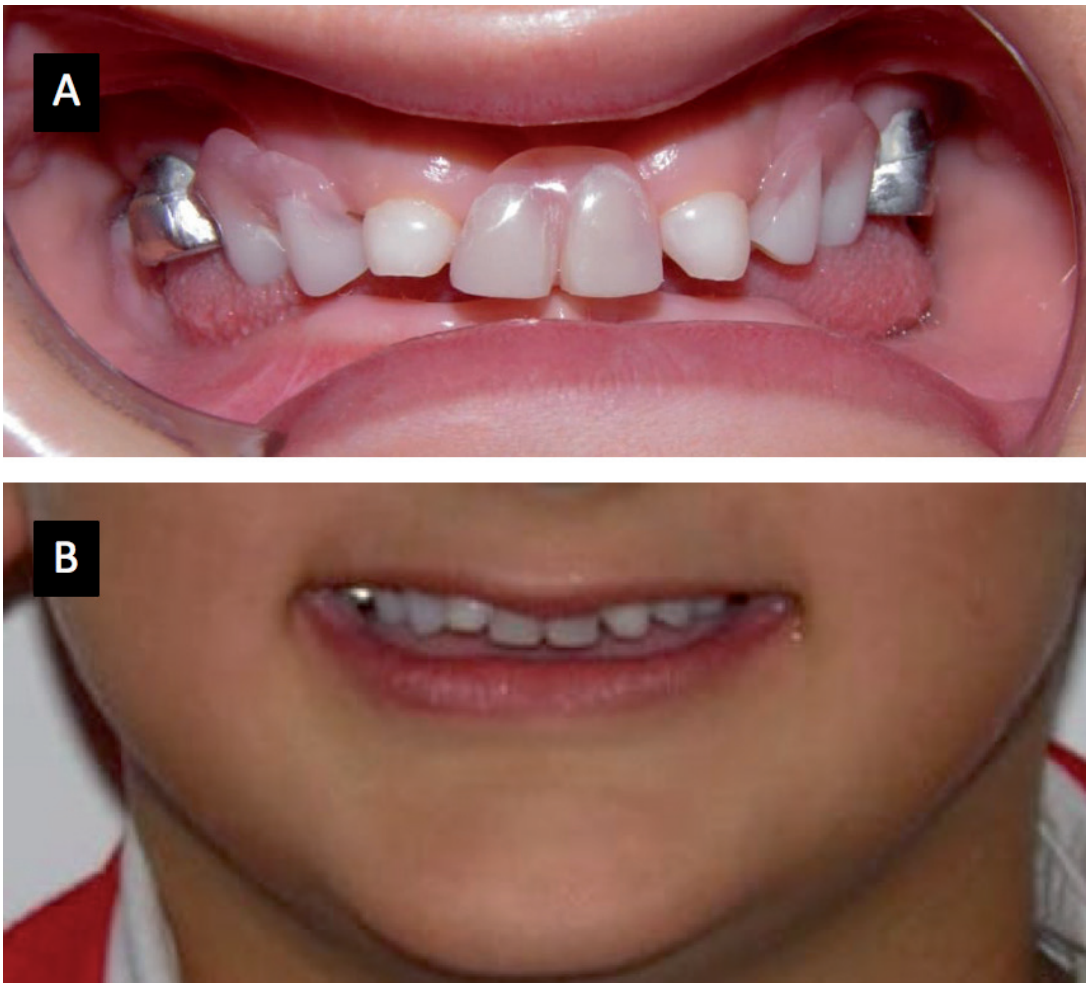


Figure 6: Photographic image after the placement of Nance palatal arch appliance with acrylic teeth: (A) intra-oral image; (B) extra-oral image.

NF- κ B pathway, upregulating the NFATc1 protein, and regulating the cytokines which are important for the osteoclastogenesis [10].

As previously described, an EDA mutation would change the normal NF- κ B function and the signaling pathway during the tooth formation process. The mutation could also alter the RANKL, being a part of the TNF superfamily, and a NF- κ B ligand. This could have promoted the resorption of the bone around the impacted molar.

We believe that, the EDA mutation caused the bone resorption around the impacted molar, which along with the presence of Reduced Enamel

Epithelium and Rests of Malassez, resulted in the formation of the follicular cyst.

Conclusion

We report a new (de novo) EDA mutation p. E67G (c.200A>G) in a patient with non-syndromic oligodontia and its association with a follicular cyst and bone resorption, for the first time in the literature. This needs to be further corroborated with eventual reporting of additional cases for a better characterization of the role of EDA mutations in cyst development.

Acknowledgements:

The authors would like to express their gratitude to Dr. Farah FAKHRE (DDS, MSc.) for performing the orthodontic treatment and to the genetic department at the Saint-Joseph University.

Funding:

This research did not receive any specific grant from funding agencies in the public, commercial, or not-for-profit sectors.

Conflict of Interest:

All authors (Dr. Rami Abou-khalil; Mr. Tony Yammine; Prof. Nadim Mokbel; Prof. Chantal Farra; Dr. Carole Chakar) declare no conflict of interest.

Informed Consent:

All the procedures followed were in accordance with the ethical standards of the responsible committee on human experimentation and with the Helsinki Declaration of 1975, as revised in 2008.

Informed consent was obtained from the patient, and his parent for being included in the study.

An informed consent to publish radiographic imaging and photographic images was obtained from the patient himself and his parents.

Références

1. Polder, B.J., Van't Hof, M.A., Van der Linden, F.P.G.M. and Kuijpers-Jagtman, A.M. (2004), A meta-analysis of the prevalence of dental agenesis of permanent teeth. *Community Dentistry and Oral Epidemiology*, 32
2. Bergendal, B., Klar, J., Stecksén-Blicks, C., Norderyd, J. and Dahl, N. (2011), Isolated oligodontia associated with mutations in EDARADD, AXIN2, MSX1, and PAX9 genes. *Am. J. Med. Genet.*, 155: 1616-162.
3. Courtney JM, Blackburn J, Sharpe PT (2005) The Ectodysplasin and NFjB signalling pathways in odontogenesis. *Arch Oral Biol* 50:159–163.
4. Mikkola, ML., 2009. Molecular aspects of hypohidrotic ectodermal dysplasia. *Am. J. Med. Genet. A*. 149, 2031-2036.
5. Johanna Pispá, Han-Sung Jung. et al. (1999), Cusp Patterning Defect in Tabby Mouse Teeth and Its Partial Rescue by FGF, *Developmental Biology*, Volume 216, Issue 2, Pages 521-534.
6. Pummila, M. Fliniaux, I. Jaatinen, R. et al. Ectodysplasin has a dual role in ectodermal organogenesis: inhibition of Bmp activity and induction of Shh expression *Development*, 134 (2007), pp. 117-125 morphogenesis. *Development*. 127(21):4691–4700.
7. Richards S et al ACMG Laboratory Quality Assurance Committee. Standards and guidelines for the interpretation of sequence variants: a joint consensus recommendation of the American College of Medical Genetics and Genomics and the Association for Molecular Pathology *Genet Med*. 2015 May;17(5):405-24.
8. J. Jernvall, T. Aberg, P. Kettunen, S. Keranen, I. Thesleff. (1998), The life history of an embryonic signaling center: BMP-4 induces p21 and is associated with apoptosis in the mouse tooth enamel knot. *Development*; 125: 161-169.
9. Martin LHC, Speight PM, (2017), Odontogenic cysts: an update. *Diagn Histopathol*, 23; 6, 260 – 265.
10. Thomson AW, Lotze MT, editors. (2003) *The Cytokine Handbook*, Two-Volume Set. 4th ed. Elsevier.