

NON-SURGICAL AND SURGICAL THERAPY: DECISION-MAKING AND CLINICAL APPROACHES

Layal Bou Semaan* | Carole Chakar** | Nadim Mokbel***

Abstract

Periodontal therapy consists of a set of surgical and non-surgical treatments in case of periodontitis. With the advances in technology and the introduction of new methods for non-surgical periodontal therapy, several procedures such as the removal of contaminated root cement have been ignored. As well, the use of antibiotic therapy as an adjunct to root scaling is a topic to be discussed. Surgery has long been compared to non-surgical methods as both treatments aim to control infection and to preserve the periodontium and teeth. Mechanical debridement and optimal plaque control remain essential for successful nonsurgical and surgical periodontal therapy.

Keywords: Antibiotics- antiseptics- non surgical periodontal therapy- periodontitis- surgical periodontal therapy- treatment protocols

IAJD 2021;12(2): 81-89.

THÉRAPIE PARODONTALE NON CHIRURGICALE ET CHIRURGICALE : PRISE DE DÉCISION ET APPROCHES CLINIQUES

Résumé

La thérapie parodontale consiste en un ensemble de traitements chirurgicaux et non chirurgicaux dans le cas de parodontite. Un certain nombre de procédures de traitement telle que l'élimination agressive du ciment radiculaire contaminé ont été ignorées et des progrès technologiques ont abouti à l'introduction de nouvelles méthodes pour la thérapie parodontale non chirurgicale. Aussi bien, l'utilisation de l'antibiothérapie comme adjuvante au surfaçage et au détartrage fut un sujet à discuter. En outre, la chirurgie a été longtemps comparée aux méthodes non chirurgicales vu que les deux traitements visent à contrôler l'infection et à préserver le parodonte et les dents. Le praticien a besoin alors d'un guide pour la prise de décision thérapeutique. Ce qui n'a pas changé, c'est l'importance du débridement mécanique complet et du contrôle optimal de la plaque pour une thérapie parodontale non chirurgicale et chirurgicale réussie.

Mots-clefs : Antibiotiques- antiseptiques- thérapie parodontale non chirurgicale- parodontite- thérapie parodontale chirurgicale- protocoles de traitement

IAJD 2021;12(2): 81-89.

* DDS, Department of periodontology
Saint-Joseph University
layal.bs@live.com

** DDS, MSc, PhD
Department of periodontology
Saint-Joseph University
carole.chakar@hotmail.com

*** DDS, MSc, PhD.
Department of periodontology
Saint-Joseph University
nadim.mokbel@gmail.com

Introduction

The goal of periodontal treatment is to avoid the progression of periodontitis and prevent teeth loss. Different non-surgical and surgical treatments have sustained these objectives. Non-surgical therapy associates pocket instrumentation to manual supragingival plaque control. Its main purpose is to disturb the microbial biofilm and suppress the inflammation. Surgery, considered as an adjuvant treatment modality, combines various flap methods to facilitate the removal of subgingival deposits and control the infection.

Guidelines are needed for therapeutic decision-making. So, what are the limitations of non-surgical periodontal therapy and when to start a surgical treatment? What are the thresholds leading the practitioner's choice?

Initial periodontal therapy: Diagnosis and motivation

The collapse of periodontal support is reflected by clinical attachment loss (CAL), radiographic bone loss (BL), presence of periodontal pockets (PPD) and bleeding on probing (BOP), which are the main features of periodontitis. The last classification [1] adopted divided periodontal diseases into chronic periodontitis, aggressive periodontitis, periodontitis as a manifestation of systemic diseases, periodontal necrotizing diseases and periodontal abscesses. Although it has been applied for years, it has several shortcomings since there is a difficulty of distinction between the categories as well as an inaccuracy of the diagnosis.

The diagnosis will be described by a stage and a grade based on a new classification [2]. The stage is defined upon the severity of the disease and the complexity of the case with a description of the extent. The grade is determined according to the risk of rapid progression and of any effect on the general health of the patient.

Maintaining effective plaque control remains the key to any attempt to prevent periodontal disease. Without ongoing patient collaboration, periodontal therapy is not successful, and the results obtained do not last. The most important risk factor for periodontitis is the accumulation of a biofilm associated with an inflammatory and destructive immune response of the host [3]. During the first session, a plaque-revealing solution is applied to all sides of the teeth. With the help of a mirror, the patient is invited to look at the different sites with plaque. The brushing technique must be either improved or replaced by the Bass technique (1948). The toothbrush must be soft. It is held to form an angle of 45 degrees with the tooth with a contact on the edge of the gum. The brush is held horizontally, and the patient will perform light movements back and forth to clean each two teeth apart. A passage of the brush vertically at the palatal and lingual surfaces must also be performed. During the second hygiene control session, a plaque-revealing solution is applied after brushing and the patient is asked to observe the accumulation zones. Changes in brushing technique are made if necessary. During a third control session, 2 to 3 weeks later, the procedure used during the second session is repeated. The evaluation aims to strengthen patient's cooperation. As well, inter-dental floss and brushes, wooden sticks and superfloss are useful for interproximal control of plaque. Scraping the tongue with a scraper or a brush is also recommended [4].

Non-surgical therapy

Instrumentation

Dental cures and sonic or ultrasonic scalers are the most frequently used instruments for periodontal treatment.

Manual instruments have been considered the Gold Standard for the treatment of pockets. Their handling remains long, painful for the patient and difficult in areas of furcation and fissures. The success of manual

treatment depends primarily on the expertise of the practitioner. A good tactile sensation and a control of the instrument are advantageous⁵.

Magnetostrictive and piezoelectric ultrasonic and sonic instruments have become widely recommended. There are no additional advantages over the manual instruments for effectiveness that have been described although they save time and reduce pain [6,7,8,9].

The effectiveness of root debridement depends essentially on the depth of the initial pockets before surgery and the nature of the tooth and its surface. The presence of residual deposits is greater when the pockets are deeper and when the debridement becomes tough. This is often the case with multi-rooted teeth, molar furcation zone and interproximal areas. This is similar with cures as with ultrasonic devices [6]. Yet, Zhang et al. [10] recommended using ultrasonic and manual subgingival instruments together when pockets are medium or deep.

The use of laser (Er: YAG) has been introduced as adjuvant or alternative to conventional periodontal therapy techniques. It has a bactericidal and detoxifying effect on pathogenic bacteria but remains an expensive treatment for the patient. It can result in tissue and bone damage following exposure to high temperatures, sometimes leading to necrosis. Therefore, it requires meticulousness [11]. Although laser treatment offers some benefits, studies on its efficacy indicate that it does not bring additional benefits to conventional techniques [12]. A meta-analysis by Sgolastra et al [13] aims to identify the role of laser as an adjuvant to manual treatment. A lack of change in periodontal parameters such as recession, supracrestal attachment and pocket depth has been proved. Further studies, with long term follow up, are needed to prove the role of the laser in the non-surgical treatment of periodontal pockets [14].

Antiseptic irrigation of periodontal pockets

Povidone-iodine, diluted sodium hypochlorite (NaOCl) and

chlorhexidine are the most cited antiseptics used for pocket irrigation. They do not interact with any medication and do not pose a risk of developing resistance against infectious agents. They are used after root debridement to induce regression of the biofilm. The effect of these products remains transient and non-systemic since the gingival fluid is renewed every 90 seconds [11].

The povidone-iodine is introduced by a fine syringe to the bottom of the pocket, non-toxic and non-irritating to the mucous membranes. It can be easily washed with soap and water without residual stains and available worldwide at low cost. It can cause allergic reactions and is contraindicated in pregnant women, breastfeeding and in cases of thyroid dysfunction [11]. In a recent 6-month split mouth RCT aiming to evaluate the effect of subgingival irrigation using 10% solution of povidone iodine compared to a NaOCl solution after one-stage full mouth scaling and root planing in patients with chronic periodontitis showed improvements in PI (Plaque Index), PPD, CAL and BOP for both groups with a trend favoring povidone iodine for PPD [15]. Rosling & al. reported after full-mouth application of povidone-iodine at the time of initial therapy, 150 patients exhibited less periodontitis for up to 13 years post-treatment [16,17].

Diluted sodium hypochlorite is effective. This solution has no negative effects as it is naturally found in human macrophages, monocytes and neutrophils [11,17].

Chlorhexidine is used in dentistry as a mouthwash concentration between 0.12 and 0.2%. The chlorhexidine molecules have positive charges and a high affinity for the negative charges found in microorganisms, glycoproteins, salivary phosphoproteins, and epithelial cells of the oral mucosa disrupting the osmotic balance of bacterial cells. The substantivity of chlorhexidine [18] to tooth surfaces and mucous membranes causes the release of antiseptic for a long time so

that its effect lasts hours after its application [17,19].

A new antiseptic containing polyhexamethylene guanidine phosphate (PHMG-P), a member of the family of polymeric guanidine antiseptics, has shown potent activity against Gram-positive and Gram-negative bacteria. Its use has reduced the need for surgical treatment, but its effects as a reduction in pocket depths remain on a short-term [20,21].

Treatment protocols

The traditional non-surgical treatment modality consists of a scaling and roots planning (SRP) by quadrants or sextants in a series of appointments. The new protocol is total disinfection by complete scaling and root planing in less than 24 hours with twice daily chlorhexidine mouthwashes, tongue scraping, tonsil spraying and subgingival irrigation of the pockets with Chlorhexidine or other antiseptic (FMD: Full Mouth Disinfection). As well, total scaling and root planing can be done without antiseptics in less than 24 hours (FMS: Full Mouth Scaling). The goal is to avoid the cross infection of sites treated from untreated sites and oral niches [22,23].

FMD, FMS and SRP are all effective for the treatment of periodontitis and do not lead to obvious discomfort for the patient. Total oral disinfection shows minimal advantages over conventional treatment concerning pocket depth reduction and clinical attachment gain. The FMS and the FMD reduce the number of appointments required to complete the therapy. The thoroughness in the root debridement, the motivation, and the level of hygiene of the patient remain critical factors in the success of the treatment whatever its modality [24,25,26,27].

Nonsurgical treatment with administration of antibiotics

Local administration of antibiotics

The local antibiotic must reach the depth of the pocket and the entire affected area for a long period of time at a high concentration for it to be

effective. Maintaining a high concentration for a prolonged period is rare with the characteristic rinsing effect of the gingival fluid⁴. Several local agents associated with nonsurgical treatment appear to offer additional benefits in terms of pocket depth reduction and attachment gain compared to nonsurgical treatment alone. Positive results were obtained with tetracycline, minocycline and metronidazole with minimal improvements in pocket depth reduction compared with root planing alone [28,29]. However, these systematic reviews did not prove the long-term effects of local antibiotics on clinical and microbiological parameters. Scientific evidence supports the use of antimicrobials as adjuvants in deep or recurrent sites. Further trials are needed for an assessment of the long-term effects of locally administered antibiotics [30,31].

Systemic administration of antibiotics

Studies demonstrate an additional benefit of adjuvant systemic antibiotic administration to increase the effectiveness of mechanical debridement therapy. It is difficult to reach a conclusion as to whether there are clinical improvements, the molecule that should be prescribed, the dose and especially the timing of drug administration. Their clinical relevance is controversial [32].

Systemic antibiotic therapy is accompanied by a development of microbial resistance and an influence on the entire human organism not only the oral cavity. They may interact with other drugs and cause allergic reactions and gastrointestinal intolerance [33].

Due to the plurality of trials, there are no specific recommendations for an antibiotic or a combination of antibiotics. Most evidence exists for the combination of amoxicillin and metronidazole, metronidazole alone and azithromycin. Patients with deep pockets, progressive or active periodontitis, or with a specific microbiological profile may benefit from adjuvant antibiotic therapy [34].

Pretzl et al. [35] developed in their consensus and based on six clinical trials that the extent and severity of periodontal diseases as well as the history of medication should be taken into consideration. In patients less than 56 years of age with periodontitis and pocket depth ≥ 5 mm in at least 35% of sites, systemic antibiotics may be administered concurrently with non-surgical periodontal therapy. Patients with periodontitis aged 56 years or older should not take systemic antibiotics. In patients with pocket depth ≥ 4 mm in less than 35% of sites, primary systemic antibiotic therapy should not be considered. In patients younger than 36 years old diagnosed with aggressive periodontitis, systemic antibiotic therapy should be given. Patients who are 36 years old or younger should have at least a stage II periodontitis [35].

Elimination of contaminated cementum

The common idea was that bacterial endotoxins penetrated the root cementum of periodontally affected teeth. Aggressive scaling and root planing, to remove the entire infected cement, was then performed. Thus, obtaining smooth surfaces free of endotoxins was a primary endpoint for periodontal healing [36,37]. Thus, studies have shown that endotoxins do not harbor in contaminated cement and that it is not necessary to eliminate it for successful treatment [38].

In a study published in 1995 [39], flaps were raised after supragingival debridement and hygiene education. Any angular bone defect has been reconstructed. Scaling and root planing was performed on the control teeth. The test teeth had only a simple removal of deposits and irrigation with saline and sterile solution. After 1 year, both groups of teeth showed similar clinical and microbiological results with respect to pocket depth and proportion of pathogens. It has been concluded that the success of periodontal treatment is more conditioned by the suppression of anaerobic pathogens

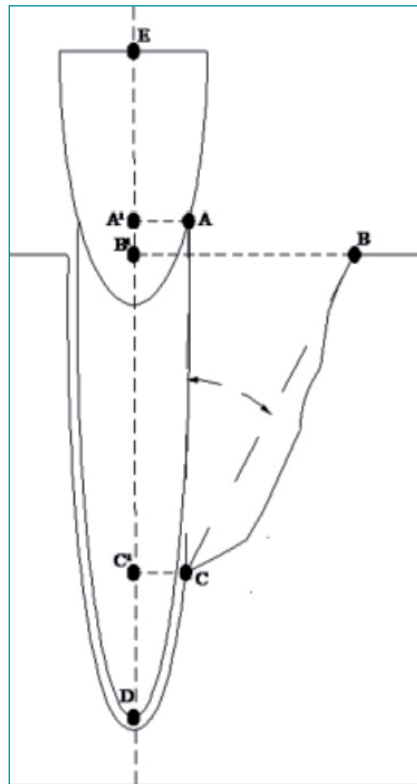


Figure 1 (A): Junction-cement junction (CEJ) with infra-osseous defect. (B): Summit of the alveolar ridge. (C): Bottom of the alveolar ridge. (D-E): Long axis of the tooth. (A-A1), (B-B1) and (C-C1): Perpendicular emitted respectively from A, B and C along the long axis of the tooth. (A1-B1): Horizontal component of bone loss. (B1-C1): vertical component of bone loss. (A1-C1): component of total bone loss. If the tooth is restored, its cervical limit is taken as a reference instead of the (CEJ). Radiographically, the two axes (A-C) and (C-B) determine the bone defect [42].

than the elimination of contaminated cementum.

Since endotoxins are exclusively located on the root surface, repeated therapy to remove the contaminated cementum would obviously result in unnecessary excessive loss of root material. This exposes the patient to risks such as hypersensitivity, root fracture or pulpitis by exposure of the dentinal tubules [40]. A smooth root surface does not retain the microbial plaque and is therefore a useful objective after instrumentation. Intentional and targeted removal of the root cementum is not mandatory.

Clinical results after instrumentation of the pockets

Nonsurgical treatment is effective in reducing PPD, CAL and infra-osseous defects.

The effect of scaling and root planing on the decrease in pocket depth is not significant at the sites with a minor initial depth. Nonsurgical treatment

reduces the pocket by more than 1 mm at the sites with a medium initial pocket depth (4-6 mm) and more than 2 mm at the deep pockets (>7 mm). With respect to supracrestal attachment, scaling at shallow sites appears to result in a loss. A gain of 0.5 mm for the average pockets and 1 mm for the deep pockets is observed following non-surgical periodontal treatment. This shows that the clinical results after scaling and root planing depend essentially on the initial pocket depth [41].

Periodontitis is characterized by bone destruction resulting in vertical or horizontal defects depending on the extent and direction of the periodontal lesion. Vertical defects are associated with rapid progression of periodontitis and a possible loss of teeth [42].

Whenever the distance (BC) is ≥ 2 mm (Figure 1) with radiographic signs of bone resorption at the lateral limits of the defect and the PPD is ≥ 5 mm in one of the vestibular or

lingual/interproximal palatal aspects of the tooth, an intraosseous or angular defect is present. Following root planing treatment, a bone gain can occur resulting in a decrease of the defect's depth.

Hwang et al., [43] observed an increase in bone density at 39 sites with vertical bone loss with PPD > 3mm that received nonsurgical treatment and reevaluated 12 months later. A gain in bone density is more characteristic at the deep pockets.

Minimally invasive non-surgical periodontal therapy (MINST) associated with minimal tissue trauma has been introduced to improve bone gain, pocket reduction, and supracrestal attachment gain. The goal is to minimize patient discomfort and maximize healing potential using microscopes and fine instruments. Long-term clinical and radiographic results (5 years) show that this therapy produces bone remodeling at the level of defects. The (MINST) is a valuable treatment option for improving the prognosis of teeth with infra-osseous defects [44].

According to Barbato et al., minimally invasive surgical (MIS) and non-surgical (MINST) periodontal therapy manifested with favorable results in the treatment of residual pocket associated with intrabony defect [45].

Microbiological results after instrumentation of the pockets

The microorganisms have been subdivided into several complexes. Each complex contains the pathogens that were commonly found together. The two red (*Porphyromonas gingivalis*, *Tannerella forsythia*, *Treponema denticola*) and orange (*Campylobacter gracilis*, *Campylobacter rectus*, *Campylobacter showae*, *Eubacterium nodatum*, *Fusobacterium nucleatum*, *Fusobacterium periodonticum*, *Peptostreptococcus micros*, *Prevotella intermedia*, *Prevotella nigrescens*, *Streptococcus constellatus*) complexes are the most frequently encountered at sites with periodontal disease [46].

The removal of subgingival plaque and calculus deposits, in combination with supragingival control, alters the pockets by reduction of microorganisms. Species that persisted in subgingival may find their habitat less hospitable. If each subject with periodontitis had the same subgingival microbiota then a single approach suitable for all could be valid which is not the case; hence the heterogeneity. A reduction of microorganisms in sites with a pocket depth > 3 mm from 91×10^5 to 23×10^5 was observed following periodontal treatment [47].

After periodontal treatment and within 3 to 12 months, re-emergence of red and orange complex species may indicate an absence of resolution of periodontal disease. The removal of subgingival calculus results in only a brief reduction in the number of colonizing agents and that the bacterial quantity can be restored in 2 to 7 days. The bacteria are supplied again by nutrients and multiply rapidly. The elimination of microorganisms causes two important phenomena. The first is a change in the proportions of the species during the recolonization period and the second is the change in the environment of the bacteria. Pathogenic species do not recolonize dental surfaces in the same proportions as before the practitioner's initial intervention [48].

It should be noted that a hyperinflammatory phenotype is more likely to react to small proportions of pathogenic species favoring their outbreaks. Adjuvant systemic antibiotic therapy can improve treatment outcomes. Since species differ in microbiota levels in each subject and individuals do not respond identically to treatment, the results depend on the host's defense of an infection and the nature of the bacteria in the site. Recolonization underlines the importance of maintenance and control visits [48].

Reassessment and criteria for success of nonsurgical treatment

Although quadrant scaling and root planing (SRP) and total disinfection

(FMD and FMS) by complete scaling in less than 24 hours accompanied by strict instructions regarding the mechanical control of plaque by the patient are effective, it is important to note that lesions can't be all resolved. The main objective is to follow the initial treatment and to carry out re-evaluations, especially at sites with recurrent clinical signs. Periodontal tissue resistance to probing and absence of bleeding are signs of resolution of the inflammatory lesion [4]. The decrease in pocket depths reduces the risk of progression of periodontitis and loss of teeth [49]. As well, teeth with a positive bleeding index are 46 times more likely to be lost than teeth without a major gingival inflammation [50].

Surgical therapy

Purpose

Surgical removal of pockets is intended to prevent the progression of periodontal disease and make root surfaces accessible to scaling and root planning. By better access to the root surfaces, the anatomical shape as well as the sequelae consequent to the periodontal disease will be corrected. Affected periodontal tissues will be regenerated or reconstructed. As well, it facilitates the plaque control by the patient [4].

Indications of surgical treatment

Scaling and root planing have been shown to be beneficial but surgical treatment is considered the next phase. It is difficult to determine which patients should be non-surgically retreated and which patients require surgery. The struggle when performing nonsurgical treatment increases with the depth of pockets, increased width of tooth surfaces, presence of root fissures, concavities, furcations and with subgingival defective limits of dental restorations. It is also important to monitor for persistent inflammation and bleeding as well as rough tooth surfaces that may suggest residual deposits. The infection control and oral hygiene maintained by the patient are not only determined by his dexterity

but also by the presence of hyperplasia, gingival craters and restorations with an unfavorable contour and surface. Surgical treatment is therefore indicated for the establishment of a better dento-gingival morphology to make hygiene control successful [4].

Contraindications of surgical treatment of the pockets

Although tobacco negatively affects healing, it is considered as a contraindication for surgical periodontal treatment. The clinician should be aware that the reduction in pocket depth, supracrestal attachment gain, and bone regeneration are less important in smokers than non-smokers [51,52].

The various surgical techniques are useful in the short term, but the mechanical control is a critical factor in the success of the surgical treatment. The new plaque formation causes recurrence of the disease and further loss of clinical attachment [53].

Also, the patient's medical history is fundamental to identify the conditions that can prevent periodontal surgery and the precautions that should be taken into consideration.

Clinical outcome of nonsurgical vs surgical treatment

Plaque accumulation

An important factor to consider when evaluating the effect of surgery is the control of postoperative infection. Insufficient hygiene instructions and minimal postoperative support after surgical periodontal intervention, regardless of the surgeon's technique, result in increased pocket depths and additional deterioration of supracrestal attachment. Patients receiving repeated oral hygiene instructions maintain a reduced pocket with attachment gains. A professional tooth cleaning every 3 months can partially offset the negative effects of variations in plaque control performed but there is no evidence to suggest differences between nonsurgical or surgical treatment or between various surgical procedures [4,53,54].

Level of supracrestal attachment and pocket depth

At sites with low initial pocket depth, surgical therapy may result in greater loss of supracrestal attachment compared to nonsurgical therapy. A significant gain in supracrestal attachment is obtained following periodontal surgery at sites with a deep initial pocket. In a systematic review, published in 2002, meta-analysis indicated that after 12 months of surgical treatment a reduction of 0.6 mm in pocket depth (weighted mean difference = 0.58 mm; 95% CI: 0.38-0.79) and supracrestal attachment gain of 0.2 mm (weighted mean difference = 0.19 mm; 95% CI: 0.04-0.35) were more important than of non-surgical treatment in deep pockets (> 6 mm).

In 4 to 6 mm pockets, surgical treatment resulted in greater supracrestal attachment gain of 0.4 mm (weighted mean difference = -0.37 mm; 95% CI: -0.49 to -0.26) but a smaller pocket reduction of 0.4 mm (weighted mean difference = 0.35 mm; 95% CI: 0.23-0.47) than nonsurgical treatment.

Surgical treatment at the sites with shallow pockets (1-3 mm) induces a 0.5 mm decrease in the supracrestal attachment (weighted mean difference = -0.51 mm; 95% CI: -0.74 to -0.29) compared to nonsurgical treatment.

From this review, it can be concluded that treatment of deep pockets (> 6 mm) by surgical access gives greater reduction in pocket depth and supracrestal attachment gain. In the long term, these two treatment modalities are effective for maintaining gum health and preventing the loss of supracrestal attachment [55].

Gingival recession

Gingival recession is an inevitable consequence of periodontal therapy due to resolution of inflammation detected after nonsurgical as well as surgical therapy. Regardless of the treatment modality used, sites with initially deep pockets will experience more pronounced signs of gingival recession compared to sites with shallow initial pockets. Root planing causes

less gingival recession than surgical therapy, especially one that includes resection of the bone. This initial difference observed in the magnitude of the recession between the different treatment modalities decreases with time due to a coronal rise of the gingival margin after surgical treatment [56].

Treatment of infrabony defect

The defect morphology is usually described depending on the number of bone walls limiting the lesion [57]. This description should include the perspective of the periodontal ligament since the primary purpose of periodontal therapy is the regeneration of the periodontium including a formation of a new cementum and bone with insertion of periodontal ligament fibers.

Defects with a one remaining bone wall are characterized by a single zone for ligamentous cell proliferation at the apical portion. While defects with at least two remaining bone walls have larger sources for cell proliferation [58].

Rosling et al. [59] studied the healing of two- and three-wall infra-osseous defects following a modified Widman flap with curettage and root planing. Patients in the test group received periodontal treatment follow-up every two weeks for 2 years while subjects in the control group were recalled once a year for prophylaxis. Patients in the test group had supracrestal attachment gain while the control group had sites with recurrent periodontitis associated with bone loss and supracrestal attachment. This shows that infra-osseous defects may present bone remodeling following surgical treatment associated with adequate plaque control.

Limitations of non-surgical treatment and decision-making

In the case of inadequate oral hygiene, efforts must be made to motivate the patient. Following re-evaluation and in the case of recurring sites, active treatment may become an option if repeated debridement at one site does not contribute anymore.

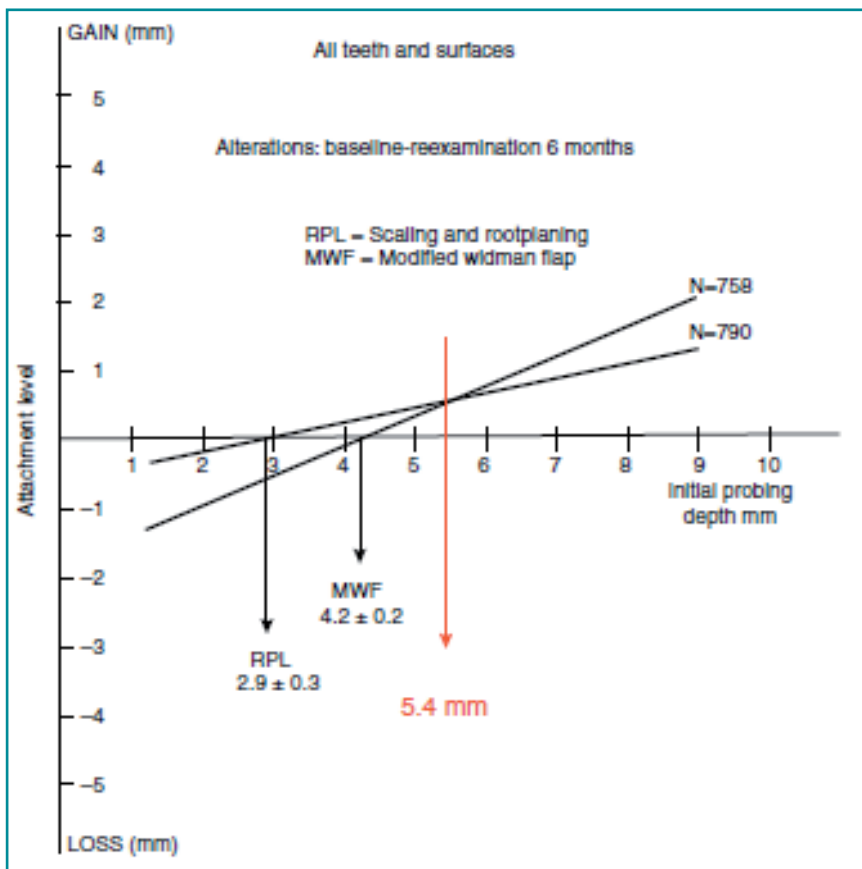


Figure 2: Graph illustrating attachment loss with initial pocket depth according to Lindhe et al, (1982)61.

Clinical improvements in the retreated pockets are less than those obtained during the initial nonsurgical treatment. Only 11 to 16% of retreated sites are considered successful and about 50% of sites with an initial pocket depth ≥ 7 mm are considered unsuccessful [60].

The critical probing depth for decision making represents a value above which a treatment will result in attachment gain and below which attachment loss can occur.

Lindhe et al., (Figure 2) indicates that the critical probing depth for nonsurgical treatment is 2.9 mm. This means that below this value scaling and root planning can cause a loss of supracrestal attachment. The critical probing depth for surgical treatment with an access flap is 4.2 mm. This means that the surgical treatment is beneficial only beyond this value.

Below this value, a loss of attachment can result. The two values already described meet and define in their turn a critical pocket depth of 5.4 mm. This means that surgery is indicated mainly with a probing depth ≥ 5.4 mm, while between 2.9 and 5.4 mm non-surgical treatment is preferred [61,62].

Conclusion

In conclusion, although techniques and technologies have been introduced, this has not devalued the mechanical debridement and plaque control for successful non-surgical and surgical periodontal treatment. Disruption and elimination of biofilm remains a condition for periodontal success, whereas intentional removal of the root surface is not necessary. The use of specific systemic antimicrobials in subjects with aggressive

periodontitis and deep pockets may be beneficial as an adjunct to non-surgical periodontal therapy. All treatment modalities are equivalent options and have the same therapeutic results. Access flap surgical therapy is indicated in sites with a deep pocket with postoperative periodontal support and adequate maintenance of oral hygiene. A critical depth of probing remains essential for decision-making.

References

1. Armitage GC. Development of a Classification System for Periodontal Diseases and Conditions. *Ann Periodontol.* 1999 Dec 1;4(1):1–6.
2. Papapanou PN, Sanz M, Buduneli N, Dietrich T, Feres M, Fine DH, et al. Periodontitis: Consensus report of workgroup 2 of the 2017 World Workshop on the Classification of Periodontal and Peri-Implant Diseases and Conditions: Classification and case definitions for periodontitis. *J Periodontol.* 2018 Jun;89:S173–82.
3. Chapple ILC, Van der Weijden F, Doerfer C, Herrera D, Shapira L, Polak D, et al. Primary prevention of periodontitis: managing gingivitis. *J Clin Periodontol.* 2015 Jan 29;42(S16):S71–6.
4. Lang NP, Lindhe J, editors. *Clinical Periodontology and Implant Dentistry*, 6th Edition. Vol. 26. John Wiley & Sons; 2015.
5. Yaghini J, Naghsh N, Attaei E, Birang R, Birang E. Root Surface Roughness After Scaling and Root Planing with Er:YAG Laser Compared to Hand and Ultrasonic Instruments by Profilometry. *J Dent Tehran Iran.* 2015 Dec;12(12):899.
6. Jepsen S, Deschner J, Braun A, Schwarz F, Eberhard J. Calculus removal and the prevention of its formation. *Periodontol 2000.* 2011 Feb 1;55(1):167–88.
7. Walmsley AD, Lea SC, Landini G, Moses AJ. Advances in power driven pocket/root instrumentation. *J Clin Periodontol.* 2008 Aug 26;35(s8):22–8.
8. PR408: Effect of periodontal treatment with ultrasonic instrumentation alone or in combination with hand instrumentation on patient pain and sensitivity in generalized advanced periodontitis. *J Clin Periodontol.* 2018 Jun 20;45(S19):258–258.
9. P. Hahner, H. Mayer, V. Faber, D. Graßhoff, O. Lemeschew, N. Mauermann, R. Rößler, G. Gaßmann. O086: Subjective evaluation of different piezo-electric ultrasonic devices in supportive periodontal treatment by patients and dental hygiene students. *J Clin Periodontol.* 2018 Jun 20;45(S19):37–37.
10. Zhang X, Hu Z, Zhu X, Li W, Chen J. Treating periodontitis—a systematic review and meta-analysis comparing ultrasonic and manual subgingival scaling at different probing pocket depths. *BMC oral health.* 2020 Dec;20(1):1-6.
11. Perry R, Klokkevoeld, Bobby Butler, Richard T. Kao. *Lasers in Periodontal and Peri-implant Therapy*. Newman and Carranza's *Clinical Periodontology*, Chapter 68. 688-695.e4.
12. Slots J. Low-cost periodontal therapy. *Periodontol 2000.* 2012 Oct 1;60(1):110–37.
13. Sgolastra F, Severino M, Petrucci A, Gatto R, Monaco A. Nd:YAG laser as an adjunctive treatment to nonsurgical periodontal therapy: A meta-analysis. *Lasers Med Sci.* 2014 May;29(3):887–95.
14. Erbil D, Nazaroğlu K, Baser U, Issever H, Mese S, Isik AG. Clinical and Immunological Effects of Er, Cr: YSGG Laser in Nonsurgical Periodontal Treatment: A Randomized Clinical Trial. *Photobiomodulation, Photomedicine, and Laser Surgery.* 2020 May 1;38(5):316-22.
15. Kessler S, Lasserre JF, Toma S. Evaluation of multiple subgingival irrigations with 10% povidone-iodine after scaling and root planing: a randomized clinical trial. *Quintessence International.* 2021 Jun 1;52(6):496-504.
16. Rosling B, Hellström MK, Ramberg P, Socransky SS, Lindhe J. The use of PVP-iodine as an adjunct to non-surgical treatment of chronic periodontitis. *Journal of clinical periodontology.* 2001 Nov;28(11):1023-31.
17. Deepa A, Sharma S. Low-Cost Antiseptics in Periodontal Therapy—A Review Article. *International Journal Of Drug Research And Dental Science.* 2021 Jun 30;3(2):115-20.
18. Carrilho MR, Carvalho RM, Sousa EN, Nicolau J, Breschi L, Mazzoni A, Tjäderhane L, Tay FR, Agee K, Pashley DH. Substantivity of chlorhexidine to human dentin. *Dental materials.* 2010 Aug 1;26(8):779-85.
19. Szulc M, Zakrzewska A, Zborowski J. Local drug delivery in periodontitis treatment: A review of contemporary literature. *Dent Med Probl.* 2018;55(3):333–42.
20. Vitt A, Gustafsson A, Ramberg P, Slizen V, Kazeko LA, Buhlin K. Polyhexamethylene guanidine phosphate irrigation as an adjunctive to scaling and root planing in the treatment of chronic periodontitis. *Acta Odontologica Scandinavica.* 2019 May 19;77(4):290-5.
21. PR106: Efficacy of antiseptics as adjunctive to scaling and root planing. *J Clin Periodontol.* 2018 Jun 20;45(S19):155–6.
22. Quirynen M, Bollen CM, Vandekerckhove BN, Dekeyser C, Papaioannou W, Eysen H. Full-vs. partial-mouth disinfection in the treatment of periodontal infections: short-term clinical and microbiological observations. *Journal of dental research.* 1995 Aug;74(8):1459-67.
23. Heitz-Mayfield LJA, Lang NP. Surgical and nonsurgical periodontal therapy. *Learned and unlearned concepts. Periodontol 2000.* 2013 Jun 1;62(1):218–31.
24. Afacan B, Çınarcık S, Gürkan A, Özdemir G, İlhan HA, Vural C, Köse T, Emingil G. The effects of full-mouth disinfection on gingival crevicular fluid levels of calprotectin, osteocalcin, and N-telopeptide of Type I collagen in severe chronic periodontitis. *Journal of Periodontology.* 2020 Feb 5.
25. Tomasi C, Wennström JL. Full-mouth treatment vs. the conventional staged approach for periodontal infection control. *Periodontology 2000.* 2009;51(1):45-62.
26. Santuchi CC, Cortelli JR, Cortelli SC, Cota LO, Fonseca DC, Alencar CO, Costa FO. Scaling and Root Planing per Quadrant Versus One-Stage Full-Mouth Disinfection: Assessment of the Impact of Chronic Periodontitis Treatment on Quality of Life—A Clinical Randomized, Controlled Trial. *Journal of periodontology.* 2016 Feb;87(2):114-23.
27. Fang H, Han M, Li Q-L, Cao CY, Xia R, Zhang Z-H. Comparison of full-mouth disinfection and quadrant-wise scaling in the treatment of adult chronic periodontitis: a systematic review and meta-analysis. *J Periodontol Res.* 2016 Aug;51(4):417–30.
28. Hanes PJ, Purvis JP. Local Anti-Infective Therapy: Pharmacological Agents. *A Systematic Review. Ann Periodontol.* 2003 Dec 1;8(1):79–98.
29. Bonito AJ, Lux L, Lohr KN. Impact of Local Adjuncts to Scaling and Root Planing in Periodontal Disease Therapy: A Systematic Review. *J Periodontol.* 2005 Aug 1;76(8):1227–36.
30. Gomes EW, Casarin M, Martins TM, da Silva AF. Local delivery therapies as adjuvants to non-surgical periodontal treatment of periodontitis grade C: a systematic review. *Clinical Oral Investigations.* 2020 Oct 17:1-2.

31. Matesanz-Pérez P, García-Gargallo M, Figuero E, Bascones-Martínez A, Sanz M, Herrera D. A systematic review on the effects of local antimicrobials as adjuncts to subgingival debridement, compared with subgingival debridement alone, in the treatment of chronic periodontitis. *J Clin Periodontol*. 2013 Mar;40(3):227–41.
32. Munasur SL, Turawa EB, Chikte UM, Musekiwa A. Mechanical Debridement with Antibiotics in the Treatment of Chronic Periodontitis: Effect on Systemic Biomarkers-A Systematic Review. *International Journal of Environmental Research and Public Health*. 2020 Jan;17(15):5601.
33. Hersh EV, Moore PA. Adverse drug interactions in dentistry. *Periodontol 2000*. 2008 Jan 14;46(1):109.
34. Herrera D, Sanz M, Jepsen S, Needleman I, Roldán S. A systematic review on the effect of systemic antimicrobials as an adjunct to scaling and root planing in periodontitis patients. *J Clin Periodontol*. 2003 May 15;29(s3):136–59.
35. Pretzl B, Sälzer S, Ehmke B, Schlagenhauf U, Dannewitz B, Dommisch H, et al. Administration of systemic antibiotics during non-surgical periodontal therapy—a consensus report. *Clin Oral Investig*. 2018 Oct 29.
36. O’Leary TJ. The Impact of Research on Scaling and Root Planing. *J Periodontol*. 1986 Feb 1;57(2):69–75.
37. Jones WA, O’Leary TJ. The Effectiveness of in Vivo Root Planing in Removing Bacterial Endotoxin from the Roots of Periodontally Involved Teeth. *J Periodontol*. 1978 Jul 1;49(7):337–42.
38. Nyman S, Sarhed G, Ericsson I, Gottlow J, Karring T. Role of “diseased” root cementum in healing following treatment of periodontal disease. *J Periodontol Res*. 1986 Sep;21(5):496–503.
39. Mombelli A, Nyman S, Brägger U, Wennström J, Lang NP. Clinical and microbiological changes associated with an altered subgingival environment induced by periodontal pocket reduction. *J Clin Periodontol*. 1995 Oct;22(10):780–7.
40. Cadosch J, Zimmermann U, Ruppert M, Guindy J, Case D, Zappa U. Root surface debridement and endotoxin removal. *J Periodontol Res*. 2003 Apr 30;38(3):229–36.
41. Hung H-C, Douglass CW. Meta-analysis of the effect of scaling and root planing, surgical treatment and antibiotic therapies on periodontal probing depth and attachment loss. *J Clin Periodontol*. 2002 Nov 1;29(11):975–86.
42. Nibali L, Pometti D, Tu Y-K, Donos N. Clinical and radiographic outcomes following non-surgical therapy of periodontal infrabony defects: a retrospective study. *J Clin Periodontol*. 2011 Jan 1;38(1):50–7.
43. Hwang Y-J, Fien MJ, Lee S-S, Kim T-I, Seol Y-J, Lee Y-M, et al. Effect of Scaling and Root Planing on Alveolar Bone as Measured by Subtraction Radiography. *J Periodontol*. 2008 Sep;79(9):1663–9.
44. Nibali L, Yeh Y-C, Pometti D, Tu Y-K. Long-term stability of intrabony defects treated with minimally invasive non-surgical therapy. *J Clin Periodontol*. 2018 Dec 1;45(12):1458–64.
45. Barbato L, Selvaggi F, Kalemaj Z, Buti J, Bendinelli E, La Marca M, Cairo F. Clinical efficacy of minimally invasive surgical (MIS) and non-surgical (MINST) treatments of periodontal intra-bony defect. A systematic review and network meta-analysis of RCT’s. *Clinical oral investigations*. 2020 Mar;24(3):1125-35.
46. Socransky SS, Haffajee AD, Cugini MA, Smith C, Kent RL. Microbial complexes in subgingival plaque. *J Clin Periodontol*. 1998 Feb 1;25(2):134–44.
47. Teles RP, Haffajee AD, Socransky SS. Microbiological goals of periodontal therapy. *Periodontol 2000*. 2006 Aug 23;42(1):180–218.
48. Haffajee AD, Teles RP, Socransky SS. The effect of periodontal therapy on the composition of the subgingival microbiota. *Periodontol 2000*. 2006 Oct 1;42(1):219–58.
49. Matuliene G, Pjetursson BE, Salvi GE, Schmidlin K, Brägger U, Zwahlen M, et al. Influence of residual pockets on progression of periodontitis and tooth loss: Results after 11 years of maintenance. *J Clin Periodontol*. 2008 Jul 23;35(8):685–95.
50. Schätzle M, Loe H, Lang NP, Bürgin W, Ånerud Å, Boysen H. The clinical course of chronic periodontitis. *J Clin Periodontol*. 2004 Nov 19;31(12):1122–7.
51. Javed F, Al-Rasheed A, Al-Hezaimi K, Almas K, Romanos GE. Effect of Cigarette Smoking on the Clinical Outcomes of Periodontal Surgical Procedures. *Am J Med Sci*. 2012 Jan 1;343(1):78–84.
52. Patel RA, Wilson RF, Palmer RM. The Effect of Smoking on Periodontal Bone Regeneration: A Systematic Review and Meta-Analysis. *J Periodontol*. 2012 Feb;83(2):143–55.
53. Nyman S, Lindhe J, Rosling B. Periodontal surgery in plaque-infected dentitions. *J Clin Periodontol*. 1977 Dec 1;4(4):240–9.
54. Rosling B, Nyman S, Lindhe J. The effect of systematic plaque control on bone regeneration in infrabony pockets. *Journal of clinical periodontology*. 1976 Mar;3(1):38-53.
55. Heitz-Mayfield LJ, Trombelli L, Heitz F, Needleman I, Moles D. A systematic review of the effect of surgical debridement vs. non-surgical debridement for the treatment of chronic periodontitis. *Journal of clinical periodontology*. 2002 Dec 1;29:92-102.
56. Kaldahl WB, Kalkwarf KL, Patil KD, Molvar MP, Dyer JK. Long-term evaluation of periodontal therapy: I. Response to 4 therapeutic modalities. *Journal of periodontology*. 1996 Feb;67(2):93-102.
57. Papapanou PN, Tonetti MS. Diagnosis and epidemiology of periodontal osseous lesions. *Periodontology 2000*. 2000 Feb;22(1):8-21.
58. Lang NP. Focus on intrabony defects—conservative therapy. *Periodontology 2000*. 2000 Feb;22(1):51-8.
59. Rosling B, Nyman S, Lindhe J. The effect of systematic plaque control on bone regeneration in infrabony pockets. *Journal of clinical periodontology*. 1976 Mar;3(1):38-53.
60. Wennström JL, Tomasi C, Bertelle A, Dellasega E. Full-mouth ultrasonic debridement versus quadrant scaling and root planing as an initial approach in the treatment of chronic periodontitis. *J Clin Periodontol*. 2005 Jun 30;32(8):851–9.
61. Lindhe J, Socransky SS, Nyman S, Haffajee A, Westfelt E. “Critical probing depths” in periodontal therapy. *J Clin Periodontol*. 1982 Aug 1;9(4):323–36.
62. Lang NP, Salvi GE, Sculean A. Nonsurgical therapy for teeth and implants—When and why?. *Periodontology 2000*. 2019 Feb;79(1):15-21.