

PREVALENCE OF IMPACTED CANINE AND ITS ASSOCIATION WITH OTHER DENTAL ANOMALIES AMONG POPULATION IN SANA'A CITY

Amenah Shumar*

Abstract

The aim of the present study is to determine the prevalence of impacted canines and its association with other dental anomalies in a random sample of Yemeni population in Sana'a.

This non-interventional, descriptive, cross-sectional study involved 2150 orthopantomogram (OPG) obtained randomly from different digital panoramic x-ray centers in Sana'a, Yemen from January 2018 to February 2020. This study was conducted over a period of 3 months from March 2019 to May 2020. Data collected was entered into a spreadsheet (Excel 2016; Microsoft, US) and analyzed using Statistical Package for Social Sciences (SPSS) version 25. Among 2150 OPGs, impacted canines were found in 182 patients (9.2%), most commonly in females (66.5%). A statistically significant difference was found between the right and left sides ($p < 0.05$), the mesioangular impaction was seen in 165 patients (66.3%), and level B depth of impaction was observed in 149 patients (59.8%).

The most commonly associated anomaly with canine impaction was retention of deciduous canine (29.5%); the most common associated pathology was dentigerous cyst (10.4%). No relation was noticed between canine impaction and the third molar status ($p > 0.05$).

The present study provides useful data regarding the prevalence of canine impaction in Yemeni population, Sana'a city.

Keywords: Dental anomalies – canines – orthopantomogram – pathology – dental impaction.

IAJD 2021;12(1):32-39.

PRÉVALENCE DE L'INCLUSION DE LA CANINE ET SON ASSOCIATION AVEC D'AUTRES ANOMALIES DENTAIRES DANS UNE POPULATION À SANA'A- YÉMEN

Résumé

Le but de la présente étude est de déterminer la prévalence des canines incluses et son association avec d'autres anomalies dentaires dans un échantillon aléatoire de la population yéménite de Sana'a.

Cette étude non interventionnelle, descriptive et transversale a porté sur 2150 orthopantomogrammes (OPG) obtenus au hasard dans différents centres de radiographie panoramique numérique à Sanaa, au Yémen, de janvier 2018 à février 2020. Cette étude a été menée sur une période de 3 mois, de mars 2019 à mai 2020.

Les données collectées ont été saisies (Excel 2016; Microsoft, États-Unis) et analysées à l'aide du programme « Statistical Package for Social Sciences (SPSS) » version 25.

A partir des 2150 OPGs observés, des canines incluses ont été retrouvées chez 182 patients (9,2%), le plus souvent chez les femmes (66,5%). Une différence statistiquement significative est observée entre les côtés droit et gauche ($p < 0,05$), l'impaction mésioangulaire a été observée chez 165 patients (66,3%) et la profondeur d'impaction de niveau B a été observée chez 149 patients (59,8%).

L'anomalie la plus fréquemment associée était la rétention de la canine de lait (29,5%); la pathologie associée la plus courante était le kyste dentigère (10,4%). Aucune relation n'a été observée entre l'impaction de la canine et le statut de la troisième molaire ($p > 0,05$).

La présente étude fournit des données utiles concernant la prévalence de l'impaction canine dans la population yéménite de la ville de Sana'a.

Mots-clés : anomalies dentaires - canines - orthopantomogramme - pathologie - impaction dentaire.

IAJD 2021;12(1):32-39.

* B.D.S,
Sana'a University

Introduction

According to Anderson (1997), impaction may be defined as the failure of complete eruption into a normal functional position of one tooth within normal time due to lack of space in the dental arch, caused by obstruction by another tooth or development in an abnormal position [1]. The permanent canines are the foundation and pillar of an aesthetic smile and functional occlusion. It stands at the corner of the dental arch forming the canine eminence for support of the alar base and upper lip. Functionally, it supports the dentition contributing to its disarticulation in lateral movements in certain individuals. Its root length and particularly its volume, makes it one of the most outstanding abutments for prosthetic replacement of other maxillary teeth.

Impacted teeth, especially canines, present many problems for orthodontist. They can compromise tooth movement, aesthetics and functional outcomes [2]. Moyers [3] stated that the maxillary cuspid follows a more difficult and tortuous path of eruption than any other tooth. At the age of three, it is high in the maxilla with its crown directed mesially and somewhat lingually. It moves towards the occlusal plane, gradually up righting itself until it seems to strike the distal aspect of the root of the lateral incisor. Then, it seems to be deflected to a more vertical position. However, it often erupts into the oral cavity with a marked mesial inclination. The most frequently impacted teeth are third molars, maxillary canines, maxillary central incisors and maxillary premolars, respectively [4 - 6].

Canine impaction occurs in approximately 2-13% of population and is twice as common in females as it is in males. The incidence of canine impaction in the maxilla is more than that in the mandible [7]. Canine impaction can be caused by several etiologic factors [8] such as local factors, systemic and genetic.

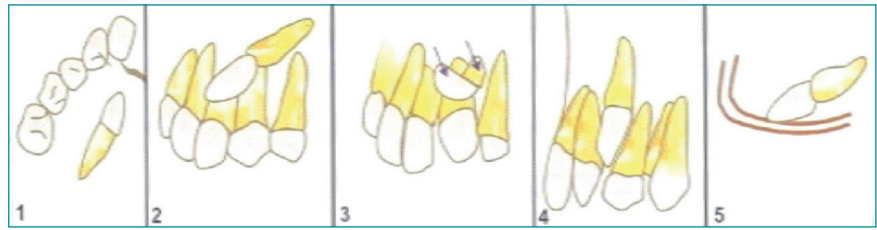


Fig. 1: Classification of impacted canine according to axial inclination.

Dental anomalies and pathologies associated with impacted canines are retention of deciduous teeth, ectopic eruption, mal shaped laterals, congenital missing teeth, supernumerary teeth, transmigration and odontoms, they can also cause movement or external root resorption of the adjacent teeth, cystic lesions, and especially in partial eruption cases, infection, pain and trismus [9].

Many classification systems have been proposed to determine the level and severity of canine impaction, depending on many criteria such as tooth inclination and localization.

In 1935, Field and Ackerman [10] proposed a classification of maxillary and mandibular impacted canines in relation to the arches and the apices of the adjacent teeth:

-Labial position:

- 1) Crown with intimate relationship with incisors;
- 2) Crown well above apices of incisors.

-Palatal position:

- 1) Crown near surface, in close relationship to root of incisors.
- 2) Crown deeply embedded in close relationship to apices of incisors.

-Intermediate position:

- 1) Crown between lateral incisor and first premolar root.

- 2) Crown above of these teeth with crown labially placed and root palatally placed, or vice versa.

-Unusual position:

- 1) In nasal or antral wall.
- 2) In infraorbital region.

In the mandible, the classification of Field and Ackerman is:

-Labial position:

Vertical, oblique, horizontal.

-Unusual position:

At the inferior border, in mental protuberance, migrated to the opposite side.

According to the axial inclination, 6 classes are observed (Fig. 1):

Class I: Impacted canine located in the palate: Horizontal, vertical, semi-vertical.

Class II: Impacted canine located in the buccal side: Horizontal, vertical, semi-vertical

Class III: Impacted canines located in both palatal as well as buccal alveolar bone.

Class IV: Impacted canines located vertically between incisors and premolars.

Class V: Impacted canines located in edentulous maxilla.

Class VI: when canine is placed in abnormal position, antral wall, and infraorbital region

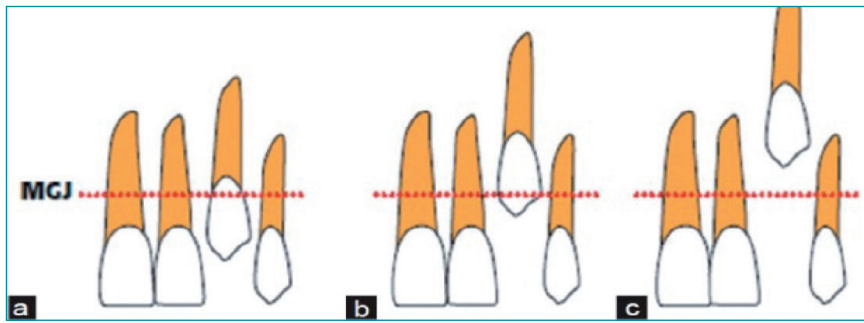


Fig. 2: Classification of impacted canine according to the depth.

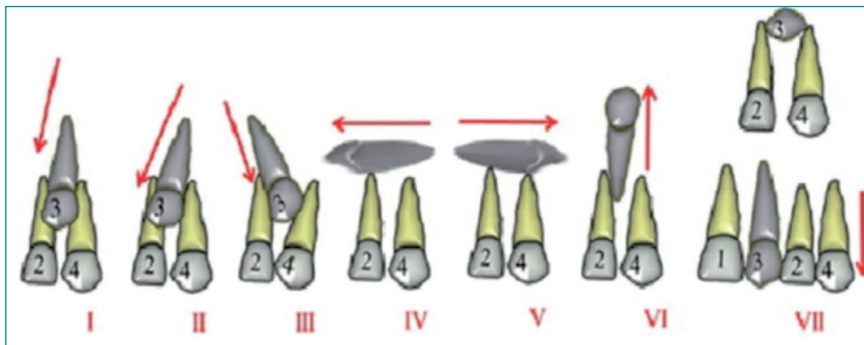


Fig. 3: Classification of canine impaction according to Yamamoto et al. (2003) [12].

Mandibular impacted canines were also classified according to the depth of impaction (Fig. 2) [11]:

- Level A: The crown of the impacted canine tooth is at the cervical line of the adjacent teeth.
- Level B: The crown of the impacted canine tooth is between the cervical line and root apices of the adjacent teeth.
- Level C: The crown of the impacted canines is beneath the root apices of the adjacent teeth.

Another classification was proposed by Yamamoto et al. in 2003 [12]. The authors described seven subtypes of maxillary canine impaction depending on the angle between the long axis of the tooth and the occlusal plane as identified on orthopantomograms (Fig. 3).

Although many impacted teeth are asymptomatic, they can cause movement or external root resorption of the adjacent teeth, cystic lesions, and especially in partial eruption

cases, infection, pain and trismus [13]. Impacted canine can be associated with many dental anomalies such as retention of deciduous teeth, ectopic eruption, transmigrating, peg shaped laterals, congenitally missing teeth, supernumerary tooth, odontoma ... etc.

The general objective of this study is: to determine the prevalence of impacted canines and its association with other dental anomalies in a random sample of Yemeni population in Sana'a.

Materials and methods

Study design

This non-interventional, descriptive, cross-sectional study involved 2150 panoramic radiographs obtained from different digital panoramic x-ray centers in Sana'a, Yemen from January 2018 to February 2020. This study was conducted over a period of 3 months from March 2019 to May 2020.

Sample size

The sample size was selected according to population survey study using random sampling calculated by using epi info. Software, version 1.4.3, was used, taking into consideration the following criteria:

- Population size = 4000000 [14].
- expected frequency = 50% [epi info.].
- Worst acceptable (precision) = 2.4%
- Confidence level 95%

So the sample size was 2150 radiographs.

Selection criteria

Patients with age less than 15 years, with history of maxillofacial trauma, craniofacial anomaly or syndrome (Down syndrome or Cleidocranial Dysostosis), presence of incomplete data or poor quality of OPG, incomplete formation of root were excluded from the study.

Data variables

An individual panoramic radiograph was used for each patient which recorded multiple variables: gender (male/female), type of impaction (unilateral, bilateral), side (left/right), jaw (maxilla, mandible), angle (mesioangular, distoangular, horizontal, vertical) and depth (A, B,C), associated anomalies (ectopic eruption, inadequate space, retention of deciduous canine, retention of deciduous second molar, agenesis of teeth, ill shaped laterals, multiple impactions, supernumerary teeth, transmigrating), associated lesions that appears radiographically (caries, periodontitis, dentigerous cysts, root resorption of adjacent tooth, odontoma), third molar situation (erupted, impacted, missing).

Statistical analysis

The collected data were verified, coded and analyzed for descriptive statistics then entered into a spreadsheet (Excel 2016; Microsoft, US) and analyzed using Statistical Package for Social Sciences (IBM, SPSS Statistics version 25.0). Results of variables rela-

Gender/Arch	Maxilla N (%)	Mandible N (%)	Both N (%)	Total N (%)
Female	103 (56.6%)	10 (5.5%)	8 (4.4%)	121 (66.5%)
Male	52 (28.6%)	6 (3.3%)	3 (1.6%)	61 (33.5%)
Total	155 (85.2%)	16 (8.8%)	11 (6%)	182 (100%)

Table 1: Distribution of impacted canines by arches in relation to gender.

Associated anomalies	Frequency	Percent
Congenital missing lateral incisor	7	1.8%
Congenital missing second premolar	4	1.0%
Ectopic eruption	108	27.5%
Inadequate space	72	18.3%
Multiple impactions	6	1.5%
Peg shaped lateral	10	2.5%
Retention of deciduous canine	116	29.5%
Retention of deciduous second molar	1	0.3%
Supernumerary tooth	4	1.0%
Transmigration	60	15.3%
Missing values	5	1.3%
Total	393	100.0%

Table 2: Associated anomalies with impacted canines.

tions were assessed and displayed by frequency and percentage. P-value was assessed through Pearson Chi-square test. The level of significance was set at 0.05.

Ethical consideration

The study was approved by the head of Department of Community Medicine at Sana'a University and conducted according to the declaration of Helsinki principles. All data including patient's demographic information were kept confidential.

Results

Among 2150 OPG's of Yemeni patients, 249 impacted canines were found in 182 (9.2%) cases. A female predilection in impacted canines was observed (121 females (66.5%); 61 male (33.5%)). The male to female ratio was 1:2.

The proportion of impacted maxillary canines (85.2%) was significantly more than that of impacted mandibular canines (8.8%) and more than that of impacted upper and lower canines together (6%), with the ratio of mandible to maxilla 1:9.7.

The distribution of impacted canines by area of jaw was related to gender in table 1. It appeared that impacted maxillary canines in females (56.6%) was higher than in males (28.6%). Same observation was made for the mandibular canines where the prevalence of impaction was significantly higher in females 10 (5.5%) than in males 6 (3.3%) ($p < 0.05$).

The distribution of impacted canine by side was evaluated: out of 182 patients with 249 impacted canine teeth, it appeared that impactions were leaning towards the right side (51.8%) more than left side (48.2%).

Over two thirds of the selected population presented with unilateral type of impaction (71.4%), and the rest (28.6%) presented bilateral impactions.

Concerning the distribution of canine impaction by angle, the mesioangular was the most dominant angulation (66.3%), followed by vertical (23.7%) and horizontal (8%). The distoangular seemed to be the least common angulation (2%).

For the depth of impaction, the most dominant depth was level B (59.8%), followed by level C (24.9%), and level A (15.3%).

Dental anomalies associated with impacted canine are listed in table 2. The present study showed that two or more anomalies can be observed on the same OPG. The most common anomaly was retention of deciduous canine (29.5%), followed by ectopic eruption (27.5%). The least encoun-

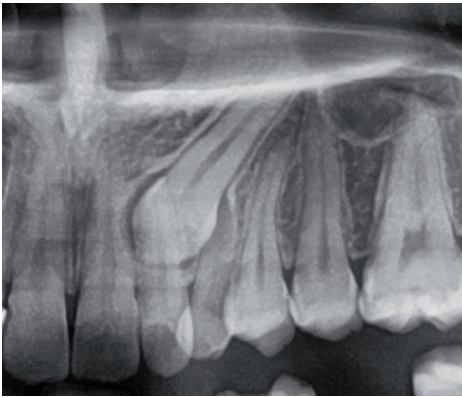


Fig. 4: Radiograph of dentigerous cyst in maxillary impacted canine.

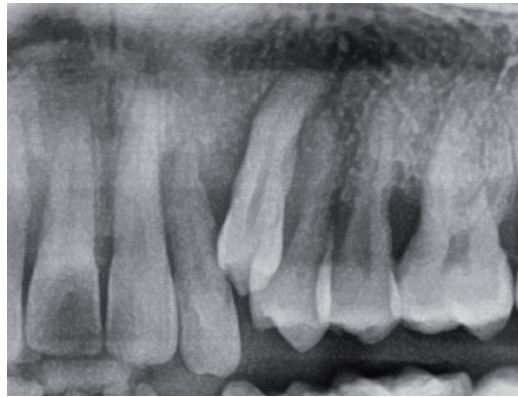


Fig. 5: Radiograph of periodontitis in maxillary impacted canine.

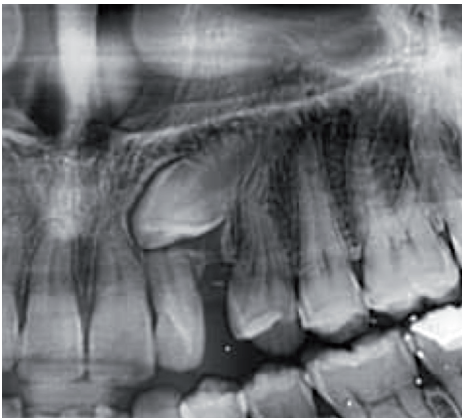


Fig. 6: Radiograph of lateral incisor root resorption in case of a maxillary impacted canine.

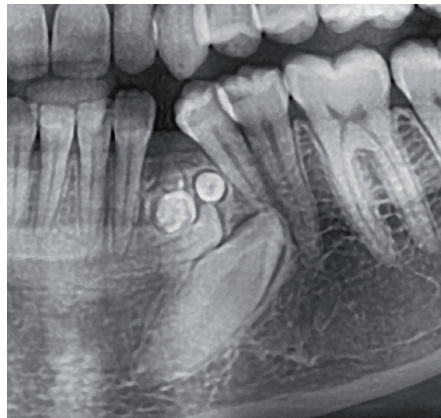


Fig. 7: Radiograph of odontome adjacent to mandibular impacted canine.

tered anomaly was retention of deciduous second molar (0.3%).

Among the dental pathologies associated with impacted canine, the most prevalent pathology was dentigerous cyst found in 19 cases (10.4%) (Fig. 4), followed by root resorption of adjacent tooth found in 12 patients (6.6%), dental caries of adjacent tooth found in 4 cases (2.2%), odontomes found in 4 cases (2.2%); the least to be found was periodontitis found only in 1 case (0.5%) (Fig. 5). In some cases, impacted maxillary canine might resorb the root of the adjacent lateral incisor (Fig. 6).

The present study has related the impaction of canines to third molar status (missing, erupted, impacted or still forming). Out of 182 patients with

249 impacted canines, the third molar most common situation was missing third molars 99 (39.7%) whether they were congenitally missing or extracted for any reason, followed by erupted third molars 65 (26.1%). Then, impacted third molars counted for 17.3% of the cases, and 16.9% of the cases were still in forming status. The relation between the canine impaction and third molar eruption is statistically not significant with $p > 0.05$ which makes it hardly an etiology of canine impaction.

Discussion

The prevalence of canine impaction among this Yemeni population of Sana'a city was found to be 9.2%, a higher rate than the prevalence repor-

ted in the study of Al-Motareb et al., realized in a Yemeni population and published in 2017 [15] where the prevalence of canine impaction was 3.55%.

However, similar prevalence rates of canine impaction were found in India (9.7%) [16], in Iran (9.8%) [17], and in Central Saudi Arabia (7.5%) [18].

In 1981, Becker et al. obtained a prevalence of 13.9% [19]; however other studies showed a lesser prevalence such as that realized in Hong Kong (2.05%) [20], in Western India (5.9%) [21], in Saudi Arabia (1.44%) [22], in Sudan (2%) [23] and in Najran in Saudi Arabia (5.35%) [24].

The present study showed that canine impaction was more prevalent in females (66.5%). This result is in agreement with the results of a study

Anomalies & Pathologies	Our Study N= 182	Sudan [23] N= 59	Hong Kong [20] N= 533	Mexico [27] N= 52	Yemen [15] N= 188	Belgium [30] N=130	UAE [28] N= 146
Retention of d. C	N= 116 (29.5%)	N= 40 (81.6%)	-	-	N= 97 (51.5%)	-	-
Ectopic eruption	N= 108 (27.5%)	-	-	-	N= 115 (61.1%)	-	-
Inadequate space	N= 72 (18.3%)	-	-	-	N= 53 (28.2%)	-	-
Transmigration	N= 60 (15.3%)	N= 2 (4%)	N= 32 (6.0%)	N= 12 (23.07%)	-	-	-
Peg shaped laterals	N= 10 (2.5%)	N= 1 (2%)	-	N= 1 (1.92%)	-	-	N= 6 (16.67%)
Congenital missing laterals	N= 7 (1.8%)	N= 4 (8.2%)	-	N= 4 (7.69%)	-	-	-
Multiple impactions	N= 6 (1.5%)	N= 1 (2%)	N= 48 (9.0%)	N= 10 (19.23%)	-	-	N= 9 (25.0%)
Congenital missing premolars	N= 4 (1.0%)	-	-	N= 4 (7.69%)	-	-	-
Supernumerary tooth	N= 4 (1.0%)	-	N= 37 (6.9%)	N= 3 (5.76%)	-	-	N= 4 (11.11%)
Retention of d. E	N= 1 (0.3%)	N= 3 (6.2%)	-	-	-	-	N= 2 (5.56%)
Dental caries	N= 4 (2.2%)	-	-	-	-	-	-
Dentigerous cyst	N= 19 (10.4%)	N= 1 (2%)	-	-	-	-	-
Root resorption	N= 12 (6.6%)	-	N= 22 (4.1%)	-	N= 12 (6.3%)	N= 24 (14.8%)	-
Periodontitis	N= 1 (0.5%)	-	-	-	-	-	-
Odontoma	N= 4 (2.2%)	N= 1 (2%)	N= 26 (4.9%)	-	-	N= 3 (1.9%)	N= 2 (5.56%)

Table 3: Comparison between results of dental anomalies and pathologies of the present study with other studies.

conducted in Yemen in 2017 [15] where 65.4% of the canine impactions were observed in females. Other studies showed also female predilection such as that realized in Hong Kong (61.4%) [20], in Sudan where male to female ratio was approximately 1:4 [23], in a Portuguese population (5.2%) [25], and in a Jordanian study (68.6%) [26].

However, some studies showed no significant difference among males and females (42.6%) [17,27]. Other studies showed higher male predilection such as the study realized in King Khalid University in Saudi Arabia where the male to female ratio was 43:12 (3.58:1) [22] and in the United Arab Emirates where 77% of canine impaction cases were observed among men [28].

Impaction of maxillary canines (85.2%) was more prevalent than mandibular canine impaction (8.8%); the least common was two the arches involvement (6%). Similar results were reported in the literature: in Western India, canine impaction in the maxillary arch was 89.3% [21], in Sudan 1.6% [23] and in Saudi Arabia (94.54%) [22]. In Iran, the study showed maxilla to mandible canine impaction ratio 5:1 [17].

The present study showed that the right side was the most hosting side of canine impaction (51.8%), which is in agreement with a study done in a Portuguese population [25] and in a Jordanian sample [26]. However, no significant differences between right and left side impactions were reported

in many studies such as that realized in a Mexican population [27] and in a Palestinian population [29]. Other studies reported left side predilection such as in Belgium [30], United Arab Emirates [28], Western India [21] and Najran in Saudi Arabia [24].

Unilateral type of impaction (71.4%) was most common in patients than bilateral impaction (28.6%) which is in agreement with a study done in Yemen 2017 where 73.4% of the participants presented with unilateral impaction [15]. Other studies showed the same results [20, 21, 23, 27].

In the present study, mesial angulation was the most dominant angulation (66.3%), followed by vertical (23.7%), horizontal (8%), and distoan-

gular (2%). Similar results were obtained in Yemen [15].

Concerning the depth of impaction, the most dominant depth was level B (59.8%), followed by level C (24.9%) and level A (15.3%); similar to the results reported by Al-Motareb et al. [15].

Concerning the dental anomalies associated with impacted canine, the results of the present study were compared to the results of multinational studies (Table 3).

The present study has several limitations such as difficulty in tracing all the dental records notes and OPG. In addition, there were incomplete data in some dental records.

The relationship between gender and the location of impaction was statistically significant. However, this could be due to the unequal number of females and males in the population of choice. Further research is needed to determine whether this relation is due to genetic differences in the genders or it is due to the misrepresented sample.

The increase in accidental findings of impacted canine should encourage the community to raise awareness and educate the population about the clinical implications and the importance of implementing preventive and interceptive procedures.

Conclusion

Within the limitations of the present study, the following conclusions can be withdrawn:

- Impacted canines were more prevalent in female subjects, in maxillary arch, in the right side specifically, and commonly as unilateral type.

- Mesial angulation was the most common pattern of impaction; the majority of patients presented with B level depth of impaction.

- The most common pathology associated with impacted canines was dentigerous cyst, and the most common dental anomalies associated with canine impaction were retentions of deciduous canine.

More studies are required to evaluate the pattern of canine impaction and its associated dental anomalies and pathologies in other regions of Yemen including diverse age groups, larger sample. More appropriate radiographic tools such as Cone Beam Computed Tomographies (CBCT) should be used to localize impacted canines and to determine the overall prevalence of canine impaction.

Also, other studies are required to evaluate the etiology of impacted canine in the Yemeni population and to evaluate epidemiological data collected as postoperative squeal and complications associated with surgical removal of impacted canines.

Acknowledgment

Prof. Ahmed Al-Haddad head of community medicine department in Sana'a University.

References

1. Khawaja NA. Third molar impaction: a review. *J Pak Dent Assoc* 2006;15:97-101.
2. Mulick JF. Impacted Canines. *JC Orthod.* 1997;40:824-34.
3. Moyers RE. *Handbook of Orthodontics.* 3rd ed. New York: Mosby;1973. P:55-8.
4. Murray P, Brown NL. The conservative approach to managing unerupted lower premolars - two case reports. *Int J Paediatr Dent* 2003;13:198-203.
5. Lee PP. Impacted premolars. *Dent Update* 2005;32:152-4.
6. Karapanou V. Endodontic management of an impacted premolar. *J Clin Pediatr Dent* 2005;29:293-8.
7. Manne R, Gandikota C, Juvvadi SR, Rama HM, Anche S. Impacted canines: Etiology, diagnosis, and orthodontic management, *J Pharm Bioallied Sci.* 2012 Aug;4(Suppl 2):S234–S238.
8. Power SM, Short MB. An investigation into the response of palatally displaced canines to the removal of deciduous canines and an assessment of factors contributing to a favourable eruption. *Br J Orthod.* 1993;20:215–23.
9. Bishara SE. Impacted maxillary canines: a review. *Am J Orthod Dentofacial Orthop* 1992;101:159-71.
10. Proffit WR, Fields HW, Sarver DM. *Contemporary Orthodontics* (4th ed), Mosby Elsevier, St. Louis, MO (2007)
11. Ericson S, Kuroi J. Longitudinal study and analysis of clinical supervision of maxillary canine eruption. *Community Dent Oral Epidemiol.* 1986;14:112–6.
12. Yamamoto G, Ohta Y, Tsuda Y, Tanaka A, Nishikawa M, Inoda H. A new classification of impacted canines and second premolars using orthopantomography. *Asian J. Oral Maxillofac. Surg.* 2003;15:31-37.
13. Bishara SE. Impacted maxillary canines: a review. *Am J Orthod Dentofacial Orthop* 1992;101:159-71.
14. <http://worldpopulationreview.com/countries/yemen-population/cities/>
15. Al-Motareb F, Al-Labani M, Al-Zubair N, Dhaifullah E. Prevalence of impacted canine among Yemen population in Sana'a city. *Int J Dental Res* 2017;5(2):148-151.
16. Santosh P, Maheshwari S. Prevalence of impacted and supernumerary teeth in the North Indian population. *J Clin Exp Dent* 2014 Apr;6(2):116-120.
17. Arabion H, Gholami M, Dehghan H, Khalife H. Prevalence of impacted teeth among young adults: A retrospective radiographic study 2017;6(3):131-137.
18. Fawzan A, et al. "Prevalence of maxillary canine impaction in orthodontics at Eastern Riyadh specialized dental center". *Journal of Dental and Medical Sciences* 2017;16(1):72-74.
19. Becker A, Smith P, Behar R. The incidence of anomalous maxillary lateral incisors in relation to palatally displaced cuspids. *Angle Orthod.* 1981;51(1):24-9.
20. Sajjani AK. Impacted canines: characteristics, prevalence and implications, University of Hong Kong in September 2009.
21. Maheshwari S. Prevalence of impacted canines in Western India. *Universal Research Journal of Dentistry* 2014;4(3):148-152.
22. Mustafa AM. Prevalence of impacted canine teeth in College of Dentistry, King Khalid University. A retrospective study. *International Journal of Health Sciences & Research* 2014;4(12):211-214.
23. Mustafa RA et al. Prevalence of impacted canines among Sudanese university students, *Braz Dent Sci* 2014 Oct/Dec;17(4).
24. Alyamia B, Braimahb R, Alhariethc S. Prevalence and pattern of impacted canines in Najran, South Western Saudi Arabian population. *The Saudi Dental Journal* 2019;32(6):300-305.
25. Moreira T, Braga A, Ferreira A. Prevalence of palatally impacted canines. *Int J Dental Sci Res* 2016;January–April:2-8.
26. Rahamneh A, Al-Weshah M, Ghazlan M, Smadi H, Abu-Odeh R. Prevalence and severity of ectopic maxillary canine impaction in Southern Jordanian population: A radiographic sector analysis. *Journal of The Royal Medicals Services* 2017;24(1):38-44.
27. Herrera-Atoche JR, Agüayo-de-Pau M, Escoffié-Ramírez M, Aguilar-Ayala FJ, Carrillo-Ávila BA, Rejón-Peraza ME. Impacted maxillary canine prevalence and its association with other dental anomalies in a Mexican population. *Int J Dent.* 2017;2017:7326061.
28. Abutayyem H, et al. Prevalence of impacted maxillary canines and its associated anomalies among a dental college patients. *EC Dental Science* 18.9 (2019): 2048-2058.
29. Arandi N, Rabi T, Mustafa S. The prevalence of impacted maxillary canines in a Palestinian population: A retrospective study. *Open Journal of Stomatology* 2017;7:283-290.
30. Grisar K, Piccart F, Al-Rimawi A, Basso I, Politis C, Jacobs R. Three-dimensional position of impacted maxillary canines: Prevalence, associated pathology and introduction to a new classification system, *Clin Exp Dent Res.* 2019;5:19–25.