

ADVERSE EFFECTS OF BOTULINUM TOXIN TYPE A INJECTIONS IN MASTICATORY MUSCLES ON UNDERLYING BONE AND CARTILAGE: A LITERATURE REVIEW

Camille Haddad * | Stephanie Mrad** | Georges El Najjar***

Abstract

Botulinum toxin type A (BTA) injections in masticatory muscles are used to treat numerous clinical conditions. This neurotoxin causes atrophy and transient paralysis of the concerned muscles.

The aim of this review is to gather and define the effects of BTA injections in masticatory muscles on the underlying cartilage and bone structures. Electronic search of Medline and Google scholar databases covering the period between January 2007 and July 2019 was carried out. Eligible articles were selected according to the inclusion/exclusion criteria. Fourteen articles were included. BTA injections may cause short term reduction of cortical bone thickness and trabeculation. On the long term, cartilage volume reduction and bone volume loss were evident on the condyle and mandibular angle, at both injected and non-injected mandibular bone structures. Bone mineral density remained unaffected when only one masticatory muscle was injected but was reduced when several masticatory muscles were treated with BTA. Several cellular and molecular alterations were noticed in some articles.

Because of evidence of irreversible negative effects of BTA on the underlying structures, possible muscle, bone and cartilage volume reduction should be communicated to the patients prior to any intervention. Further studies are needed to fully understand the cellular mechanisms and molecular responses behind this phenomenon.

Keywords: Botulinum toxin – botulinum toxin type A injection – adverse effects – mandibular bone – temporomandibular joint.

IAJD 2020;11(1):37-42.

EFFETS INDÉSIRABLES DES INJECTIONS DE TOXINE BOTULINIQUE DE TYPE A DANS LES MUSCLES MASTICATOIRES SUR L'OS SOUS-JACENT ET LE CARTILAGE: UNE REVUE DE LA LITTÉRATURE

Résumé

Les injections de toxine botulique de type A (BTA) dans les muscles masticateurs sont des procédures cliniques utilisées pour traiter de nombreuses conditions. Cette neurotoxine provoque une paralysie transitoire suivie d'une atrophie des muscles concernés.

Le but de cette revue est de rassembler et de définir les effets des injections de BTA sur les muscles masticateurs ainsi que sur les structures cartilagineuses et osseuses sous-jacentes.

Une recherche électronique des bases de données « Medline » et « Google Scholar » couvrant la période de janvier 2007 à juillet 2019 a été effectuée. Les articles éligibles ont été sélectionnés en fonction des critères d'inclusion / exclusion.

Quatorze articles ont été inclus. Les injections de BTA peuvent entraîner une réduction à court terme de l'épaisseur et la trabéculatation de l'os cortical. À long terme, la réduction du volume du cartilage et la perte de volume osseux étaient évidentes sur le condyle et l'angle mandibulaire, à la fois dans les structures osseuses mandibulaires injectées et non injectées. La densité osseuse est affectée uniquement dans les cas où plusieurs muscles sont injectés simultanément. Plusieurs altérations cellulaires et moléculaires ont été remarquées dans certains articles.

En raison des effets négatifs irréversibles du BTA sur les structures sous-jacentes décrits dans la littérature, une éventuelle réduction du volume des muscles, des os et du cartilage doit être communiquée aux patients avant toute intervention. D'autres études ultérieures sont nécessaires pour mieux comprendre les mécanismes cellulaires et les réponses moléculaires à la base de ce phénomène.

Mots-clés : toxine botulique - injection de toxine botulique A - effets indésirables - os mandibulaire - articulation temporo-mandibulaire.

IAJD 2020;11(1):37-42.

* Assistant Professor,
Dpt of Prosthodontics and Occlusion,
Faculty of Dental Medicine,
Saint-Joseph University, Beirut, Lebanon
camhaddad@hotmail.com

** Resident,
Dpt of Oral Surgery,
Faculty of Dental Medicine,
Saint-Joseph University, Beirut, Lebanon

*** Resident,
Dpt of Esthetic and Prosthetic Dentistry,
Faculty of Dental Medicine,
Saint-Joseph University, Beirut, Lebanon

Introduction

Botulinum toxin type A is a metalloprotease produced by clostridium bacteria [1]. This potent neurotoxin temporarily blocks acetylcholine release at the presynaptic membrane of neuromuscular junctions leading to transient inactivity of the innervated muscles and glands [2]. BTA is the most widely used Botox preparation [3, 4]. Scott et al. introduced its use of for strabismus treatment in 1989 [5]. In dentistry the use of BTA extended for several indications such as focal dystonia, dyskinesia, migraine, hemifacial spasm, contraction of smooth and skeletal muscles, sialorrhea and myalgia [6, 7].

Botulinum toxin is often injected in facial muscles, mainly the masseter and temporal, to treat bruxism, clenching, trismus, repetitive jaw dislocations and temporomandibular joint disorders [8, 9]. BTA is also indicated for aesthetic improvement in cases of masseter hypertrophy. Single or repeated injections may be indicated to obtain the final result [10].

In animal studies, BTA injections into the masticatory muscles decreased stress at the periosteum and reduced muscle contractions and maximal bite force inducing short term bone changes [11]. In a pilot study on human subjects, Raphael et al. [12] detected reduction of trabecular bone density in the mandibular condyle of women after BTA injections.

The aim of this review is to investigate current literature on adverse effects of repetitive BTA injections in masticatory muscles for craniomandibular dysfunctions treatment on the underlying bone and cartilage structures.

Materials and methods

Studies aiming to assess the effect of BTA injections in the masticatory muscles on the mandibular bone and cartilage, published from January 2007 to July 2019, were sought using Medline electronic database, with

restrictions to the English language. A search strategy combining the following Medical Subject Headings (MeSH), search terms was used:

MeSH terms: (“Mandibular Condyle”[Mesh]) OR “Alveolar Bone Loss”[Mesh]) OR “Mandible”[Mesh]) OR “Temporomandibular Joint”[Mesh]) OR “Temporomandibular Joint Disc”[Mesh]) AND “Botulinum Toxins, Type A”[Mesh]) OR “Botulinum Toxins”[Mesh]) AND “adverse effects” [Subheading].

In addition, a Google Scholar search was performed to identify other relevant studies. Two authors screened the titles and abstracts of the identified articles in the initial search. Irrelevant publications were excluded and potential articles were required to meet the inclusion/exclusion criteria to be eligible for critical appraisal.

The inclusion criteria for studies to be considered were:

- Randomized and quasi-randomized controlled trials, including parallel studies or cross-over studies having a wash-out period of at least 3 months.
- Human and animal participants.
- Injections of BT injection type A, irrespective of dose.
- Injections in all masticatory muscles.
- Presence of a control group with any alternative intervention or placebo.
- Bone parameters assessed by histomorphometry, bone mineral density (BMD) and microtomography (micro CT) as primary outcomes.

The exclusion criteria were:

- Previously published literature or systematic reviews and thesis abstracts.
- Injections of Botox types B, C-1, C-2, D, E, F, or G.

Eligible articles were then reviewed independently in full text version by two examiners.

Data extraction

Study details were extracted and entered into data collection forms. The following characteristics were recorded: (1) title and publication date; (2) specie, and number of participants; (3) dosage, of BTA; (4) outcome measurement methods; (5) interval and length of follow-up

Results

Search outcome

Figure 1 illustrates the search strategy that yielded a total of 159 articles. After evaluating the titles and abstracts, 138 articles were excluded for non-relevance, and 21 full-text articles were assessed for eligibility by two authors. After review of full-texts, 7 articles were excluded with the following reasons: pilot study (one article), a prospective cohort (three articles), reviews (one article) and ineligible diagnosis based on TMD arthralgia or esthetic masseteric hypertrophy (two articles). A total of fourteen randomized controlled trials were finally included in this review and processed for critical appraisal. A summary of the selected studies is presented in table 1.

Effects of BTA on mandibular bone density

Two randomized controlled studies evaluated the effect of BTA on bone mineral density (BMD) compared with a control group (saline). In 2010, a study conducted on 10 old Sprague-Dawley rats showed significant bone mineral density difference in unilateral injected BTA side compared with that of the saline injected side 90 days after injections [13]. Similar results were obtained in the study of Tsai et al. [22] conducted on 60 adult rats. In the group where BTA was injected in either the masseter or temporalis alone the difference with the control saline group was not significant. Nevertheless, in a group where BTA was injected in both masseter and temporalis muscles, BMD of the mandible was 5.71 per cent less than that of the control group.

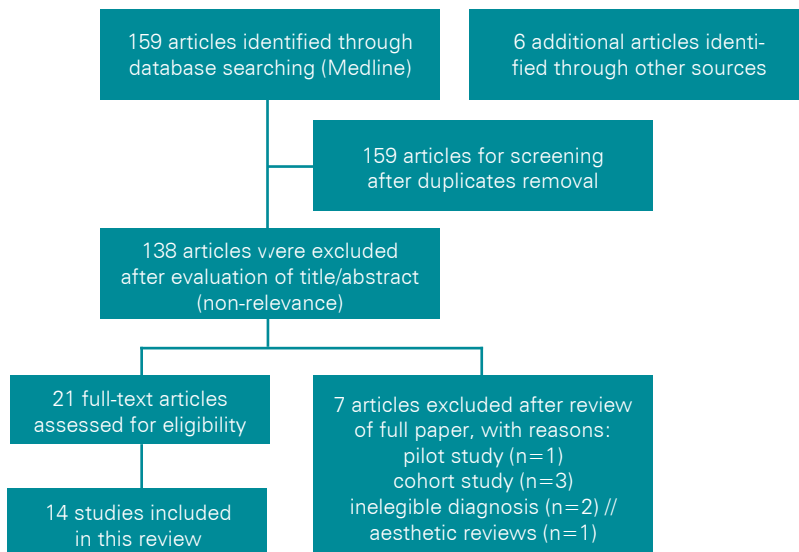


Fig. 1: PRISMA flow diagram.

Title, Journal and Year	Subjects	Dosage	Method of measurement	Time of measurement
Morphologic and bony structural changes in the mandible after a unilateral injection of botulinum neurotoxin in adult rats. <i>Journal of Oral Maxillofacial Surgery</i> (2010) [13].	Ten male 60-day-old Sprague-Dawley rats	25 U/mL (0.3 mL)	BMD	90 days after the procedure
Bone and cartilage changes in rabbit mandibular condyles after 1 injection of botulinum toxin. <i>American Journal Orthodontics and Dentofacial Orthopedics</i> (2015)[14].	50 females New Zealand rabbits	10 units	BMD	4 or 12 weeks after the injection
Mandibular bone effects of botulinum toxin injections in masticatory muscles in adult. <i>Oral Surgery Oral Medicine Oral Pathology Oral Radiology</i> (2019) [15].	Twelve adult patients	100 U: 30 U for each masseter and 20 U for each temporalis	CBCT	12 months after the injection
Botulinum toxin in masticatory muscles: Short- and long-term effects on muscle, bone, and craniofacial function in adult rabbits. <i>Bone</i> (2011) [16].	41 female New Zealand white rabbits	10 units (0.25ml)	CT-Scan	4 and 12 weeks after the injection
Botulinum toxin in masticatory muscles of the adult rat induces bone loss at the condyle and alveolar regions of the mandible associated with a bone proliferation at a muscle entheses. <i>Bone</i> (2015) [17].	15 analysis of mandibular 3D porosity by a vector projection algorithm	1 unit in 0.2ml in the masseter and 1 unit (in 0.2ml) in the temporalis	Analysis of mandibular 3D porosity by a vector projection algorithm, CT-Scan, Micro-CT	4 weeks after injection
Condylar degradation from decreased occlusal loading following masticatory muscle atrophy. <i>Hindawi</i> (2018) [18].	Sixty 5-week-old female Sprague-Dawley rats	2 units	Micro-CT, histological assessment and immunohistochemical staining	4 weeks after injection
Contrast enhancement with uranyl acetate allows quantitative analysis of the articular cartilage by micro CT: Application to mandibular condyles in the BTX rat model of disuse. <i>Micron</i> (2017) [19].	11 eighteen weeks-old male Sprague-Dawley rats	2 units (0.4 ml)	Micro-CT	4 weeks after injection
Loading of the condylar cartilage can rescue the effects of Botox on TMJ. <i>Calcified Tissue International</i> (2018) [20].	24 6-week-old females	0.3 U, volume of 30 μ l	Micro-CT, histological staining	4 weeks after injection

Bone loss after temporarily induced muscle paralysis by Botox is not fully recovered after 12 Weeks. <i>Annals of The New York Academy of Sciences</i> (2007) [21].	16 4-month-old mice in a C57BL/6 background	2U/100 g	BMC	12 weeks after injection
Bone changes in the mandible following botulinum neurotoxin injections. <i>European Journal of Orthodontics</i> (2011) [22].	Sixty 30-day-old male Long-Evans rats	2.5 ml of 25 U/ml	Cortical bone thickness and BMD	45 days after the injection
Repeated injections of botulinum toxin into the masseter muscle induces bony changes in human adults: A longitudinal study. <i>The Korean Journal of Orthodontics</i> (2017) [23].	10 human patients.	25 IU (0.5 mL) per muscle	CBCT	6 months after the injection
Cellular and matrix response of the mandibular condylar cartilage to Botulinum toxin. <i>Plos One</i> (2016) [24].	13 5-week-old transgenic mice (Col10a1) on a CD-1 background	0.3 unit: volume of 30 μ l	Micro-CT, histological examination	30 days after the injection
Early molecular response and micro anatomical changes in the masseter muscle and mandibular head after botulinum toxin intervention in adult mice. <i>Annals of Anatomy</i> (2018) [25].	16 adult male BALB/c mice	0.2 U	histomorphometric analysis, qPCR	14 days after the intervention
Masseter muscle atrophy impairs bone quality of the mandibular condyle but not the alveolar process early after induction. <i>Journal of oral rehabilitation</i> (2019) [26].	18 adult male BALB/c mice	10 μ l	micro CT	14 days after the intervention

Table 1: Summary of selected articles.

This difference was statistically significant [22].

Cortical bone thickness

In the study of Tsai et al. (2010) [13] the cortical bone showed a clear thickness reduction, in the area surrounding the BTA injection site, 4 weeks after injection. At 12 weeks, the bone showed some clear signs of a partial recovery of the losses.

Bone trabeculation

In 2012, Rafferty et al. [16] indicated significant differences in the bone trabeculation. 4 weeks after injections test groups showed almost 3 times less trabeculations than control groups. Some improvement was shown 12 weeks after injections.

Mandibular bone volume

According to a study on human subjects, Lee et al. [23] indicated significant volume loss in the mandibular angle area, 6 months after injection.

Alveolar bone volume

During a study on 41 rabbits who received a one-sided, single masse-

teric injection, both the injected and the non-injected sides showed significant alveolar bone volume reduction at 4 weeks after the procedure. These changes were still present at 12 weeks; however, they became statistically insignificant [16].

Condylar bone volume

Through Micro-CT and condylar morphometry, bone volume loss was evident in the injected site at 4 weeks, 12 weeks and a year. According to Matthys et al. [14] and Shi et al. [18], this resorption was noted specially in the anterior part of the condyle. The non-injected site showed no volume loss. Balanto-Melo et al. [26] showed that, after one BTA injection, condyle bone resorption begins at an early stage of masseter atrophy, and before alveolar process alteration.

Cartilage and subchondral bone
Kun-Darbois et al. [27] showed that after single BTA injection in masseter or temporalis muscle, cartilage thickness of adult rats did not show significant difference between injected and non-injected sites. On the other hand, in a recent study on human subjects

who received one BTA injection, Kahn A et al. (2019) [15] revealed significant loss of volume in the cartilage area and increase of trabeculation in the subchondral bone area 12 months after the injection. These changes are explained in the study of Dutra et al. [20] by a decrease in mineralization, matrix deposition and Tartrate Resistant Acid Phosphatase (TRAP) activity in the mandibular condylar cartilage [20].

Effects of BTA on cellular activity and molecular response

Dutra et al. [24] studied the cellular and matrix response of the mandibular cartilage to BTA injections. Positive TRAP staining showed a significant lower percentage of osteoclast activity in the injected side in comparison to control, suggesting a lower bone turnover. This bone remodeling decrease can be explained by immunohistochemistry tests revealing a reduced expression of Vascular Endothelial Growth Factor (VEGF), the angiogenic stimulator that attracts osteoblasts, osteoclasts and chondroclasts during endochondral ossification. Furthermore, immunohistochemistry

showed a decreased expression of pSMAD 1/5/8 on the BTA injected side signaling an increased proliferation of chondrocytes. In addition, Toluidine blue staining showed a decrease of proteoglycan secretion and Safranin O staining revealed a marked reduction of glycosaminoglycans in the mandibular condylar cartilage of the BTA injected side [24].

Another article conducted by Balanta-Melo et al. [25] in 2018 studying early molecular response of the mandibular head revealed that two days after BTA injection, mRNA levels of the bone resorption promoter RANKL showed a 4-fold increase. Also, histomorphometric analysis showed a significant reduction in bone per tissue area in the BTA injected side [25].

Discussion

When injected into masticatory muscles, botulinum toxin type A causes transient paralysis [2]. According to the Wolff's law, mastication muscles exert stresses at the periosteum and control bone microarchitecture [28]. Mandibular bone and alveolar processes are stimulated by the mechanical forces of mastication to keep the teeth and underlying bone healthy. Therefore, masticatory function and occlusal forces are correlated with mandibular bone mineral density and cortical bone [22]. This review gathers most relevant literature that report adverse effects of BTA injections in facial muscles. The use of micro CT in most articles improves and standardizes the evaluation of bone changes in the mandible. However, reviewed articles present heterogeneous study designs regarding the brand and dosage of BTA and the type of animals used.

In animal studies, Tsai et al. [13] showed that after transient muscle paralysis, injected and non-injected sites of the same mandible exhibited losses in cortical thickness due to reduced muscular activity. Important reduction of both cortical bone thickness and trabeculation, 4 weeks after injection, explains the significant loss

of bone volume on different levels: alveolar, condylar and mandibular angle. Even though bone thickness and trabeculation show recovery 12 weeks after injection, bone's total volume differences between test and control groups remain significant on the long term. These results are in agreement with two human studies that confirmed long term reduction of bone volume after BTA injections. Lee et al. [23] offered extensive evidence that bone volume loss persisted for 6 months and Kahn A et al. [15] proved that the losses remained significant at 1 year after injection. Even though bone remodeling is much faster in mice (2 weeks) than in humans (up to 9 months), the results of these two studies confirm long term reduction of bone volume after BTA injections [28].

On the other hand, results concerning bone mineral density reported in rats did not find any significance between BTA and saline injected sites when one masticatory muscle is injected with BTA. This result may be explained by the small specimen (10 old rats), by the long term follow-up period after a single injection (90 days after injection), or by the parallel changes of bone volume. BMD changes are highlighted in the study of Tsai et al. [22] where groups receiving BTA injections in only one of the masticatory muscles did not show significant changes whereas the group receiving BTA injections in both masseter and temporal muscles showed significant BMD reduction. The non-change can be explained by the compensatory effect of the non-injected muscles while the significant change might be induced by the simultaneous function reduction of both injected muscles.

Changes in bone biology after BTA injections were explored using genetically modified mice. Concerning the long term molecular response, Dutra et al. [24] conducted a study on transgenic mice and found a decreased expression of pSMAD 1/5/8 which led to increased chondrocytes proliferation and a decreased in glycoaminoglycans and proteoglycans distribution.

This study also showed a reduced TRAP and VEGF activity which indicates less bone remodeling on the injected side on the long term. On the other hand, Balanta-Melo et al. [25] demonstrated a significant decrease in RANKL expression in mandibular heads as early as 2 days after injection, which questions the specific cells concerned in this early response. RANKL is a promoter of bone resorption and osteoclastogenesis that is increased only in the first week post-injection based on the study of Balanta et al. This explains the bone loss of 30% after 14 days in the BTA injected mandibular heads. This effect is in accordance with the results found in the study of Dutra et al. [24] on female mice (-21.4%) and the study of Kun-Darbois et al. [27] on male rats (-35%) after 4 weeks. A sex contribution may have contributed in the outcome difference between male and female animals. It will be relevant to establish in the future a relationship between biochemical factors secreted by paralysed or atrophied muscles, decreased mechanical loading and osteopenia.

Conclusion

The findings of the reviewed articles suggest that repetitive BTA injections in masticatory muscles lead to several adverse effects in the related structures. A volume reduction of temporomandibular joint's cartilage, mandibular bone and alveolar process are presented. These side effects should be communicated to patients before any BTA injection in facial masticatory muscles. Future researches will help to fully understand the cellular and molecular changes behind these phenomena. Also, new indications and ways to control the negative effects of BTA injections are to investigate.

References

1. Tighe AP, Schiavo G. Botulinum neurotoxins: mechanism of action. *Toxicol Off J Int Soc Toxinology*. 2013 Jun 1;67:87–93.
2. Bogucki ZA, Kownacka M. Clinical aspects of the use of Botulinum toxin type A in the treatment of dysfunction of the masticatory system. *Adv Clin Exp Med Off Organ Wroclaw Med Univ*. 2016 Jun 5;25(3):569–73.
3. Majid OW. Clinical use of botulinum toxins in oral and maxillofacial surgery. *Int J Oral Maxillofac Surg*. 2010 Mar;39(3):197–207.
4. Rossetto O, Pirazzini M, Montecucco C. Botulinum neurotoxins: genetic, structural and mechanistic insights. *Nat Rev Microbiol*. 2014 Aug;12(8):535–49.
5. Scott AB, Magoon EH, McNeer KW, Stager DR. Botulinum treatment of strabismus in children. *Trans Am Ophthalmol Soc*. 1989;87:174–80.
6. Erbguth FJ. From poison to remedy: the chequered history of Botulinum toxin. *J Neural Transm*. 2008 Apr;115(4):559–65.
7. Clark GT, Stiles A, Lockerman LZ, Gross SG. A critical review of the use of Botulinum toxin in orofacial pain disorders. *Dent Clin North Am*. 2007 Jan;51(1):245.
8. Khanna S, Jain S. Botox: the poison that heals. *Int Dent J*. 2006 Dec;56(6):356–8.
9. Ihde SKA, Konstantinovic VS. The therapeutic use of Botulinum toxin in cervical and maxillofacial conditions: an evidence-based review. *Oral Surg Oral Med Oral Pathol Oral Radiol Endodontology*. 2007 Aug;104(2):e1–11.
10. Kim N-H, Chung J-H, Park R-H, Park J-B. The use of Botulinum toxin type A in aesthetic mandibular contouring. *Plast Reconstr Surg*. 2005 Mar;115(3):919–30.
11. Ahn KY, Kim ST. The change of maximum bite force after Botulinum toxin type A injection for treating masseteric hypertrophy. *Plast Reconstr Surg*. 2007 Nov;120(6):1662–6.
12. Raphael KG, Tadinada A, Bradshaw JM, Janal MN, Sirois DA, Chan KC, et al. Osteopenic consequences of botulinum toxin injections in the masticatory muscles: a pilot study. *J Oral Rehabil*. 2014 Aug;41(8):555–63.
13. Tsai C-Y, Huang R-Y, Lee C-M, Hsiao W-T, Yang L-Y. Morphologic and bony structural changes in the mandible after a unilateral injection of Botulinum neurotoxin in adult rats. *J Oral Maxillofac Surg*. 2010 May;68(5):1081–7.
14. Matthys T, Ho Dang HA, Rafferty KL, Herring SW. Bone and cartilage changes in rabbit mandibular condyles after 1 injection of Botulinum toxin. *Am J Orthod Dentofacial Orthop*. 2015 Dec;148(6):999–1009.
15. Kahn A, Kün-Darbois J-D, Bertin H, Corre P, Chappard D. Mandibular bone effects of Botulinum toxin injections in masticatory muscles in adult. *Oral Surg Oral Med Oral Pathol Oral Radiol*. 2019.
16. Rafferty KL, Liu ZJ, Ye W, Navarrete AL, Nguyen TT, Salamati A, et al. Botulinum toxin in masticatory muscles: Short- and long-term effects on muscle, bone, and craniofacial function in adult rabbits. *Bone*. 2012 Mar;50(3):651–62.
17. Kün-Darbois J-D, Libouban H, Chappard D. Botulinum toxin in masticatory muscles of the adult rat induces bone loss at the condyle and alveolar regions of the mandible associated with a bone proliferation at a muscle enthesis. *Bone*. 2015 Aug;77:75–82.
18. Shi Z, Lv J, Xiaoyu L, Zheng LW, Yang X. Condylar Degradation from Decreased Occlusal Loading following Masticatory Muscle Atrophy. *BioMed Res Int*. 2018 May 27;2018:1–11.
19. Kün-Darbois J-D, Manero F, Rony L, Chappard D. Contrast enhancement with uranyl acetate allows quantitative analysis of the articular cartilage by microCT: Application to mandibular condyles in the BTX rat model of disuse. *Micron*. 2017;97:35–40.
20. Dutra EH, O'Brien MH, Logan C, Tadinada A, Nanda R, Yadav S. Loading of the condylar cartilage can rescue the effects of Botox on TMJ. *Calcif Tissue Int*. 2018 Jul;103(1):71–9.
21. Grimston SK, Silva MJ, Civitelli R. Bone loss after temporarily induced muscle paralysis by Botox is not fully recovered after 12 weeks. *Ann N Y Acad Sci*. 2007;1116(1):444–460.
22. Tsai C-Y, Shyr Y-M, Chiu W-C, Lee C-M. Bone changes in the mandible following botulinum neurotoxin injections. *Eur J Orthod*. 2011 Apr;33(2):132–8.
23. Lee H-J, Kim S-J, Lee K-J, Yu H-S, Baik H-S. Repeated injections of botulinum toxin into the masseter muscle induce bony changes in human adults: A longitudinal study. *Korean J Orthod*. 2017 Jul;47(4):222–8.
24. Dutra EH, O'Brien MH, Lima A, Kalajcic Z, Tadinada A, Nanda R, et al. Cellular and matrix response of the mandibular condylar cartilage to Botulinum toxin. *Plos One*. 2016 Oct 10;11(10):e0164599–e0164599.
25. Balanta-Melo J, Toro-Ibacache V, Torres-Quintana MA, Kupczik K, Vega C, Morales C, et al. Early molecular response and microanatomical changes in the masseter muscle and mandibular head after botulinum toxin intervention in adult mice. *Ann Anat-Anat Anz*. 2018;216:112–119.
26. Balanta-Melo J, Torres-Quintana MA, Bemmann M, Vega C, González C, Kupczik K, et al. Masseter muscle atrophy impairs bone quality of the mandibular condyle but not the alveolar process early after induction. *J Oral Rehabil*. 2019;46(3):233–241.
27. Boyle C, Kim IY. Three-dimensional micro-level computational study of Wolff's law via trabecular bone remodeling in the human proximal femur using design space topology optimization. *J Biomech*. 2011;44(5):935–942.
28. Jilka RL. The relevance of mouse models for investigating age-related bone loss in humans. *J Gerontol Ser Biomed Sci Med Sci*. 2013;68(10):1209–1217.