

## MAXILLARY FIRST MOLAR WITH EXTRA PALATAL CANALS

Souheir Saad El Masril \* | Roula Abiad\*\*

### Abstract

Knowledge of the root canal anatomy and its variations is essential for successful completion of the endodontic treatment. Root canal treatment of maxillary first molars with aberrant canal configuration can be challenging. The incidence of two palatal canals in a palatal root is quite rare and had never been reported among Lebanese population. This manuscript reviews the incidence of maxillary molars with two palatal root canals reported in the literature as well as reporting the endodontic management of a maxillary first molar having two canals in the palatal root one mesial and another distal, in addition to one mesiobuccal and one distobuccal canals for a Lebanese patient.

**Keywords:** Root canal anatomy - maxillary first molar - two palatal canals.

IAJD 2020;11(1):33-36.

## PREMIÈRE MOLAIRE MAXILLAIRE AVEC CANAUX EXTRA PALATAUX

### Résumé

La connaissance de l'anatomie des canaux radiculaires et de ses variations est essentielle à la réussite du traitement endodontique. Le traitement canalair des premières molaires maxillaires avec une configuration de canal aberrant peut être difficile. L'incidence de deux canaux palatins dans une racine palatine est assez rare et n'avait jamais été rapportée dans la population Libanaise. Ce manuscrit passe en revue l'incidence des molaires maxillaires à deux canaux radiculaires palatins rapportés dans la littérature, ainsi que la prise en charge et le traitement canalair d'une première molaire maxillaire présentant deux canaux au niveau de la racine palatine, un mésial et un distal, ainsi qu'un mésio-vestibulaire et un disto-vestibulaire chez un patient Libanais.

**Mots clés:** anatomie canalair - première molaire maxillaire - deux canaux palataux.

IAJD 2020;11(1):33-36.

\* Specialty Diploma,  
Clinical Instructor,  
Dpt. of Endodontology,  
Faculty of Dentistry, Beirut Arab University, Lebanon  
souheirsaad@hotmail.com

\*\* PhD,  
Dpt. of Endodontology,  
Faculty of Dentistry, Beirut Arab University,  
Beirut- Lebanon

## Introduction

Knowledge of both normal and abnormal anatomies of the root canal system is the key for successful root canal treatment [1]. Inability to remove infected tissues can lead to persistent problems for the patient [2]. With the introduction of dental operating microscopes, detection of extracanal canals became more frequent [3]. Maxillary molars could be the most common teeth to be referred to endodontists for treatment, as they have difficult access and difficult canals anatomy [4]. Those teeth usually have three well-separated roots with a longest palatal root, a mesiobuccal root broad buccolingually having two root canals in most of the cases and a distobuccal root. [4] Dentist always look for the second mesiobuccal canal but they usually miss looking for an extra palatal canal. The literature cites the variation in the palatal root of the maxillary molars as a single root with two separate orifices [5], two separate canals [5], and two separate foramina [5]; two separate roots, each with one orifice, one canal, and one foramen [6] and a single root with one orifice [6], a bifurcated canal, and two separate foramina [7], also with a trifurcation at the apical third in the palatal canal [8]. The incidence of more than one canal in the palatal root of maxillary molars has been reported to be 1% [4]. This case provides an evidence for the incidence of two canals in palatal root of maxillary first molar among Lebanese population that was not found in the literature before.

## Clinical case

A 50 years old Lebanese male presented with severe pain related to his upper left maxillary molar that was very sensitive to percussion. Upon detailed clinical and radiographic examination, the tooth was found to have previously initiated root canal therapy and left unsealed (Fig. 1).

A diagnosis of incomplete previously initiated therapy with symptomatic apical periodontitis was

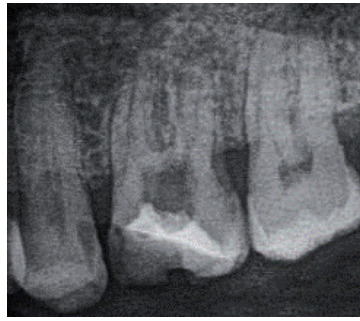

Fig. 1: Preoperative radiograph.

confirmed and non-surgical root canal retreatment was suggested to the patient. The patient was anesthetized with 1.8 mL of Lidocaine HCL 2% containing 1:100,000 epinephrine (Lignospan® Standard- Septodont). After placement of rubber dam, adjustments to the access opening was done. Typically, maxillary first molars access cavity is located within the mesial half of the occlusal surface slightly shifted buccally [11]. A rhomboidal access can be extended to insure locating second mesial canals if present [11]. The entire roof of the pulp chamber was removed to ensure proper cleaning and locating any extra canal orifice [7]. Three canals were found at the beginning (Mesio-Buccal, Disto-Buccal, and Palatal). Upon proper examination of the pulp chamber floor using a DG16 Endo probe (Hu-Friedy Mfg. Chicago, IL), a fourth canal orifice was detected about one mm distal to the main palatal canal. There was no second mesiobuccal canal. The access cavity was slightly modified, the pulp chamber was flushed with 5.25% sodium hypochlorite to remove debris. A size 10 K-file (MicroMega, Besançon, France), was used initially to confirm the patency. Working length of the four canals was determined using the apex locator (Root ZX, J Morita, Japan) and confirmed by a digital radiograph (MediaDent V6, Belgium). The radiograph confirmed the presence of the two canals in the palatal root. All of the canals were instrumented using the TwoShape rotary instruments (MicroMega, Besançon, France) and irrigated with 5.25 % sodium hypo-

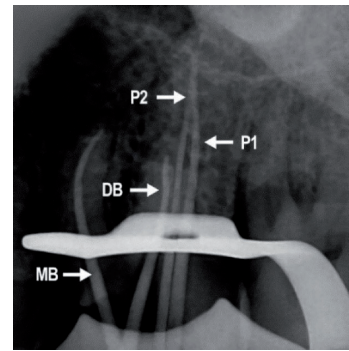


Fig. 2: Master cones in the four canals.

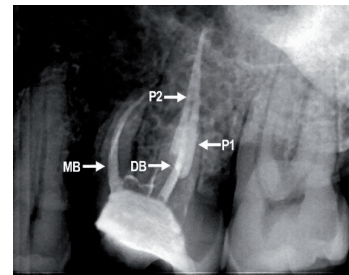


Fig. 3: Obturation radiographs.

chlorite. A final rinse was done with saline then 17% EDTA for one minute followed by a saline rinse for 2 minutes [10]. Root canals were then dried and obturated with vertical condensation technique of gutta-percha and sealer. The post obturation radiograph confirmed a Vertucci's type II root canal morphology in the palatal root (Figs. 2 & 3).

## Discussion

Success in endodontic treatment is achieved after debridement of all canals by using mechanical and chemical irrigation followed by the obturation of the whole root canal system [12]. Undetected extra roots and extra canals may contain microorganisms and their byproducts are a major reason for failure [2, 12]. In order to prevent the failure of root canal treatment, the clinicians should find and locate the orifices of all canals to clean, shape and fill the complex root canal system [12]. Technological advances may help the clinician to identify and treat the complex root anatomy system [9]. The use of magnification (magnifying glass and dental operating microscopes)

minimizes the chance to leave a canal without debridement [3]. Also, the availability of CBCT three dimensional radiograph versus the two-dimension conventional radiograph help in evaluation of the root canal anatomy during endodontic treatment [13].

The anatomy of maxillary first molar is described in the literature as having three roots and three or four root canals, the fourth canal usually being a second mesiobuccal [4]. Some authors have, however, reported seeing anatomic variations involving the number of roots/root canals with respect to distobuccal and palatal roots, but those are highly unusual and rare (less than 1%), nevertheless their existence cannot be ignored and should be thoroughly investigated [13].

Variations like two palatal roots with individual canals, single palatal root with two independent canals, and single palatal root with two canals joining in the apical third have been reported [2]. Stone and Stroner [14] studied the morphology of the palatal root in maxillary molars and reported the variations like single root having two canals with distinct orifices and foramina or single root having one canal with one orifice and two distinct foramina and two roots each having a single canal with one orifice and foramen [13].

Many studies provided some information on ethnic background, age and gender. Rodriguez et al. [15], Kottor et al. [16] and Yadav et al. [9] have reported the incidence of seven root canals in maxillary first molars; cases were described having three root canals in the mesiobuccal root, two in the distobuccal and two in the palatal root. One of those cases was found in Brazil for a 23 years old woman [15], and the other two cases were found in India for a 37 and 40 years old men [9, 16].

Tomazinho et al. [18] reported a case of a maxillary first molar with two palatal roots in Brazil. Gopikrishna et al. [19] also reported a case of two palatal roots in India, for a 25 years old woman. Her first maxillary molar had three roots in total, one fused buccal

having two buccal canals and two palatal roots with two separate canals.

The incidence of four roots having four root canals in a maxillary first molar, two buccal and two palatal, have also been described in many places of the world; Barbizam et al. [20] reported such a case in Brazil for a 35-year-old man, Baratto-Filho et al. [3] reported another for a 38-year-old Japanese woman, a similar case was found in the United States by Di Fiore [21] for 31-year-old man and Christie et al. [22] reported two cases in Canada.

Three roots and five root canals (two mesiobuccal, one distobuccal and two palatal) were reported to be found in Germany by Holderrieth et al. [23] for a 21-year-old man; also in Canada for a 42 years old man as reported by Johal. [24]. Cecic et al. [7] found their case in a white American 23 years old man.

Using CBCT, Sharma et al. [13] also found palatal canals in the first maxillary molar of an Indian patient that seemed to follow the Vertucci type II canal pattern. Pambo et al. [28] found two palatal canals using the CBCT having separate orifices and joined in the apical third.

Bifurcation at middle third of the palatal canals was described by Holderrieth et al. [23] in German 32-year-old man who had three roots with five canals: two mesiobuccal, one distal and two palatal canals having one orifice and two separate foramina.

Trifurcated palatal canals were also reported in the literature whether the tooth had one or two mesiobuccal canals. Maggiore et al. [8] reported a case for a 19 years old African American male having 3 roots with six root canals: mesiobuccal, distobuccal and three palatal canals; two palatal orifices were easily identified at high magnification dental operating microscope with the third one furcated at the apical 4 mm exiting between the two apices. De Almeida-Gomes and his colleagues [29] described a case in Brazil, for a 26-year-old man having three roots and six canals; two diso-

buccal and two palatal. Earlier in 1988 Bond et al. had [31] described a similar case in the United States for a 27 years old black woman.

Christie et al. [22] speculated that maxillary molars with two palatal roots may be encountered once every 3 years in a busy endodontic practice. Cases were found in many places of the world, mainly India, Brazil, US, Canada and Turkey. The anatomy of the case reported in this article looks very similar to the three cases described by Poorni et al. [26] in India, having only one mesiobuccal canal, one distobuccal and two palatal canals that are following Vertucci type II root canal morphology. Different races and ethnic backgrounds were involved however, such abnormal root canal among Lebanese population was not found in the literature.

This case of unusual canal anatomy was detected clinically and confirmed radiographically using two dimension digital radiographs. Magnification and CBCT were not used for initial detection of the extra canal in this case, which poses the question; is this anomaly so frequent in Lebanon for such an easy detection? Further investigations are requested to study the real anatomy of this tooth among Lebanese population.

## Conclusion

The clinicians should be aware that variations in both internal and external anatomy may be encountered, no race, age or gender is an exception. Proper examination of the floor of the pulp chamber and radiographs facilitates the detection of extra canals and prevent the failure of root canal system. More details are needed about reported cases of various possible canal morphologies, that could give better feedback about the so called map anomalies. The use of magnification and three dimensional imaging such as CBCT is highly recommended to detect extracanal.

## References

- Rubinstein R, Kim S. Long-term follow-up of cases considered healing 1 year after apical microsurgery, *J Endod* 28:378, 2002.
- Tabassum S, Raza Khan F. Failure of endodontic treatment: The usual suspects. *Eur J Dent*. 2016 Jan-Mar; 10(1): 144–147.
- Baratto-Filho F, Fariniuk LF, Ferreira EL, et al. Clinical and macroscopic study of maxillary molars with two palatal roots. *Int Endod J* 2002;35:796–801.
- Cleghorn BM, Christie WH, Dong CC. Root and root canal morphology of the human permanent maxillary first molar: a literature review. *J Endod*. 2006;32(9):813-21.
- Harris WE. Unusual root canal anatomy in a maxillary molar. *J Endod* 1980; 6(5):573-5.
- Thews ME, Kemp WB, Jones CR. Aberrations in palatal root and root canal morphology of two maxillary first molars. *J Endodon* 1979;5:94-6.
- Cecic P, Hartwell G, Bellizi R. The multiple root canal system in the maxillary first molar: a case report. *J Endod*. 1982;8(3):113-115.
- Maggiore F, Jou YT, Kim S. A six-canal maxillary first molar. *Int Endod J* 2002;35:486–91.
- Yadav HK, Saini GK, Chhabra HS, Panwar PS. Endodontic management of a maxillary first molar with seven root canals using spiral computed tomography. *J Dent*. 2017 Mar;18(1):65-69.
- Neelakantan P, Ahmed HMA, Wong MCM et al. Effect of root canal irrigant protocols on the dislocation resistance of mineral trioxide aggregate-based materials; A systematic review of laboratory studies. *Int Endod J*. 2018; Jan 29.
- Roula RS. Rubric for practical endodontics. *J Orthod Endod*. 2017;3:1.
- Iqbal A. The factors responsible for endodontic treatment failure in the permanent dentitions of the patients reported to the college of dentistry, the University of Aljouf, Kingdom of Saudi Arabia. *J Clin Diagn Res*. 2016 May; 10(5): ZC146–ZC148.
- Sharma S, Sharma V, Grover S, Mittal M. CBCT diagnosis and endodontic management of maxillary first molar with unusual anatomy of two palatal canals: A case report. *J Conserv Dent*. 2014 Jul-Aug;17(4):396–399.
- Stone LH, Stroner WF. Maxillary molars demonstrating more than one palatal root canal. *Oral Surg Oral Med Oral Pathol*. 1981;51:649-652.
- Rodrigues E, Brait AH, Galvão BF, da Silva EJ. Maxillary first molar with 7 root canals diagnosed using cone-beam computed tomography. *Restor Dent Endod*. 2017 Feb;42(1):60-64.
- Kottoor J, Velmurugan N, Sudha R, Hemamalathi S. Maxillary first molar with seven root canals diagnosed with cone-beam computed tomography scanning: A case report. *J Endod* 2010;:-1–7.
- Adanir N. An unusual maxillary first molar with four roots and six canals: a case report. *Aust Dent J* 2007;52:333–5.
- Tomazinho FS1, Baratto-Filho F, Zaitter S, Leonardi DP, Gonzaga CC. Unusual anatomy of a maxillary first molar with two palatal roots: a case report. *J Oral Sci*. 2010 Mar;52(1):149-53.
- Gopikrishna V, Reuben J, Kandaswamy D. Endodontic management of a maxillary first molar with two palatal roots and a single fused buccal root diagnosed with spiral computed tomography: A case report. *Oral Surg Oral Med Oral Pathol Oral Radiol Endod* 2008 Apr;105(4):e74-8.
- Barbizam JV, Ribeiro RG, Tanomaru Filho M. Unusual anatomy of permanent maxillary molars. *J Endod* 2004;30:668–71.
- Di Fiore PM. A four-rooted quadrangular maxillary molar. *J Endod* 1999;25:695–7.
- Christie WH, Peikoff MD, Fogel HM. Maxillary molars with two palatal roots: a retrospective clinical study. *J Endod* 1991;17:80–4.
- Holderrieth S, Gernhardt CR. Maxillary molars with morphologic variations of the palatal root canals: a report of four cases. *J Endod* 2009;35:1060–5.
- Johal S. Unusual maxillary first molar with 2 palatal canals within a single root: a case report. *J Can Dent Assoc* 2001;67:211–4.
- Aggarwal V, Singla M, Logani A, et al. Endodontic management of a maxillary first molar with two palatal canals with the aid of spiral computed tomography: a case report. *J Endod* 2009;35:137–9.
- Poorni S, Kumar A, Indira R. Maxillary first molar with aberrant canal configuration: a report of 3 cases. *Oral Surg Oral Med Oral Pathol Oral Radiol Endod* 2008;106: e53–5.
- Shi JJ. Maxillary first molar with two palatal canals: a case report. *Shanghai Kou Qiang Yi Xue, Shanghai Journal of Stomatology* 2013, 22(3):358-360.
- Pamboo J, Hans MK, Chander S, Sharma K. Endodontic management of maxillary first molar with two palatal canals aided with cone beam computed tomography: A case report. *Compend Contin Educ Dent*. 2017 Apr;38(4):e1-e4.
- Wong M. Maxillary first molar with three palatal canals. *J Endod* 1991;17:298–9.
- de Almeida-Gomes F, Maniglia-Ferreira C, Carvalho de Sousa B, et al. Six root canals in maxillary first molar. *Oral Surg Oral Med Oral Pathol Oral Radiol Endod* 2009; 108:e157–9.
- Bond JL, Hartwell G, Portell FR. Maxillary first molar with six canals. *J Endod*. 1988; 14(5):258-260.