

HOW ORTHODONTICS CAN FACILITATE RESTORATIVE DENTISTRY

Chimène Chalala*

Abstract

Full comprehensive orthodontic treatment is often a requisite in the rehabilitation of oral form and function specifically when anterior restoration(s) is (are) needed. Patients with missing, abraded or fractured teeth, peg-shaped lateral incisors, or other restorative needs may require tooth movement for optimal treatment outcomes. Such treatment necessitate collaboration between the orthodontist and others specialties, such as the restorative dentist and / or the periodontist.

The major indication for adjunctive orthodontic treatment is to facilitate and improve the dental restorative conditions at the level of the arch (space management), roots (parallel abutments) and bone height (periodontal considerations) for the placement of well-adapted and contoured restorations, crowns or implants.

This interdisciplinary management will be illustrated through specific dental treatment phases, in addition to the assessment of guidelines for general dentists, specialists, and orthodontists to establish a comprehensive treatment plan and execute it in an orderly way toward successful results.

Keywords: Orthodontics – dental restoration - periodontics.

IAJD 2012;3(2):66-73.

COMMENT L'ORTHODONTIE PEUT-ELLE FACILITER LA DENTISTERIE RESTAURATRICE

Résumé

Le traitement orthodontique est souvent une phase nécessaire pour la réhabilitation complète de la forme et de la fonction, surtout en cas de restauration des dents antérieures. Les patients dont les dents sont absentes, abrasées ou fracturées, avec des incisives latérales riziformes, ou autres impératifs de restaurations, nécessiteraient un traitement orthodontique pour optimiser les résultats. Un tel traitement exige la collaboration orthodontiste/dentiste sur différents niveaux. L'indication majeure de ce traitement est au niveau de l'arcade (créer l'espace), des racines (pour un meilleur parallélisme des piliers) et de l'os (considérations parodontales) pour le bon placement des implants et la confection de couronnes bien adaptées.

Les objectifs majeurs du traitement sont donc la fonction, l'esthétique et la santé parodontale.

L'approche multidisciplinaire est illustrée par des cas cliniques où sont développées les étapes de traitement dentaire, en plus de l'élaboration d'un référentiel à l'intention des dentistes, des spécialistes, et des orthodontistes pour établir un plan de traitement global et pouvoir le réaliser dans les meilleures conditions de succès.

Mots-clés : orthodontie – restauration dentaire – parodontie.

IAJD 2012;3(2):66-73.

* DESS Orthodontics
Clinical Associate, Faculty of Dentistry,
American University of Beirut
Instructor, Faculty of Dentistry, Lebanese University
chalalachimene@yahoo.com

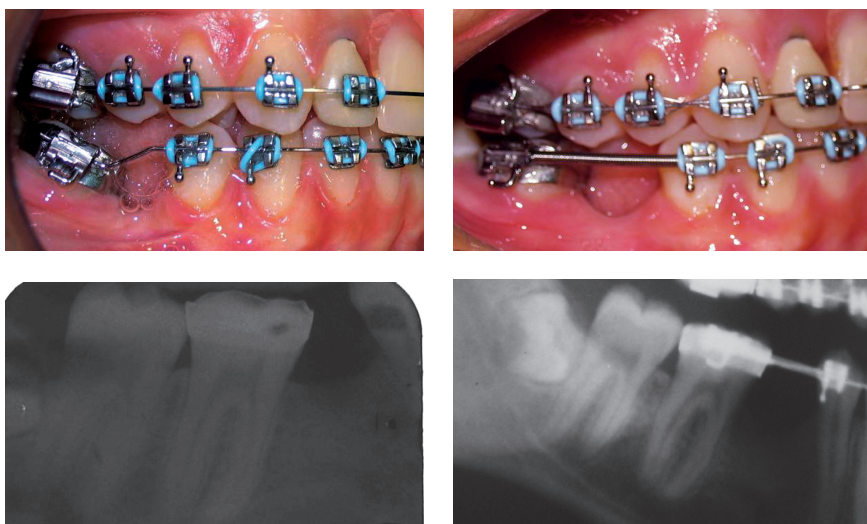


Fig. 1: Orthodontic uprighting of mandibular right 1st molar.

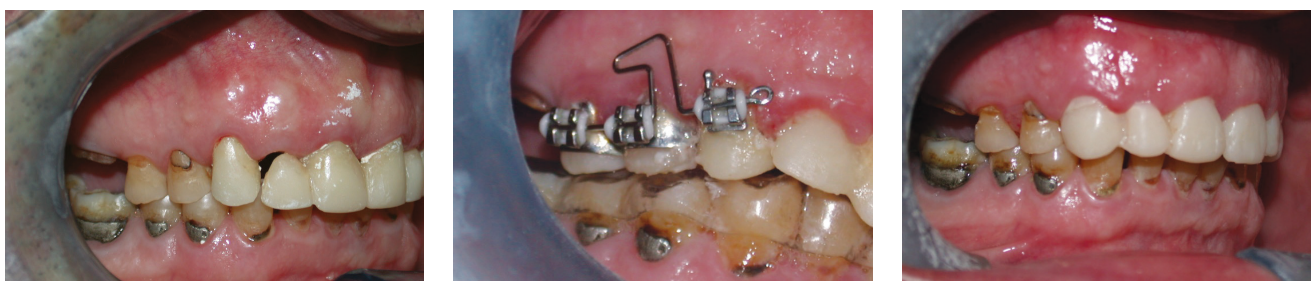

Fig 2: Orthodontic crown lengthening for periodontal (biological width) and esthetic considerations (gingival margins).

Introduction

With patients' increasing esthetics and functional demands, orthodontists are solicited to manage and create an optimal restorative environment. In fact, various dental specialties are available now to assure the ultimate dental condition of the most critical cases. Thus the interdisciplinary management is essential for the attainment of the best dental treatment outcome. The purpose of this paper is not to criticize or support orthodontic versus non orthodontic approaches, but to emphasize the criteria by which we assess the multiple and available treatment options.

Orthodontics can support restorative dentistry for periodontal, occlusal and dental considerations.

Periodontal management

Optimization of restorative conditions

Uncompensated old extractions alter adjacent and antagonist teeth position as well as their bone level: the contiguous teeth will tilt toward the vacant space creating an angular bony defect in addition to the loss of the available space.

In order to address these cited problems, an orthodontic treatment is needed to eliminate the bony defect by uprighting the tipped tooth [1]. Therefore, an amelioration of the tooth axis is often mandatory for a better realization of the prosthetic crown and a better distribution of occlusal forces [2]. Orthodontics is essential to recreate the adequate space for missing teeth replacement with optimal dimensions (Fig. 1).

Orthodontics crown lengthening

Tooth fracture is a very common problem and the level of fracture is an important factor that dictates the prognosis of the tooth [3]. If the fracture is cervical or more sub-crestal, an optimal restoration cannot be achieved without impinging on the biological width. In such situation 2 options of treatment are available:

a. Surgical crown lengthening to recreate the proper biological width. It may compromise the esthetic outcome, especially in the anterior region creating uneven gingival margins relative to the adjacent teeth and long clinical crowns [4, 5].

b. Orthodontic crown lengthening (extrusion) which provides sufficient supra-gingival tissue to restore appropriately the tooth with pleasing esthetic outcome [6] (Fig. 2).

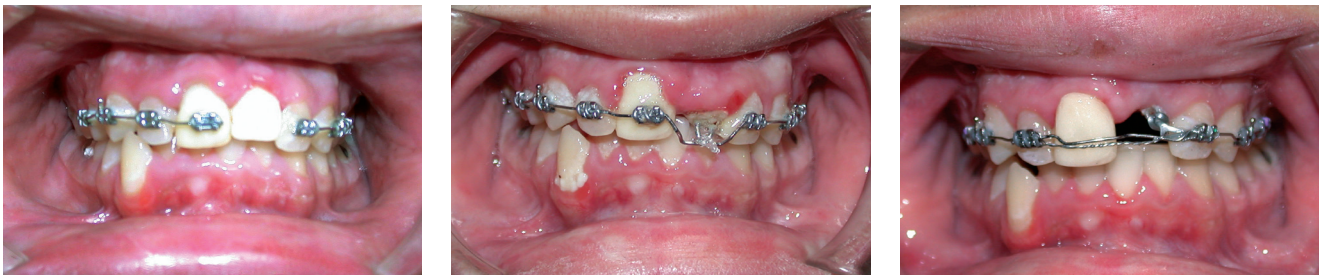

Fig. 3: Orthodontic root extrusion of a subcrestal fracture of maxillary central incisor.

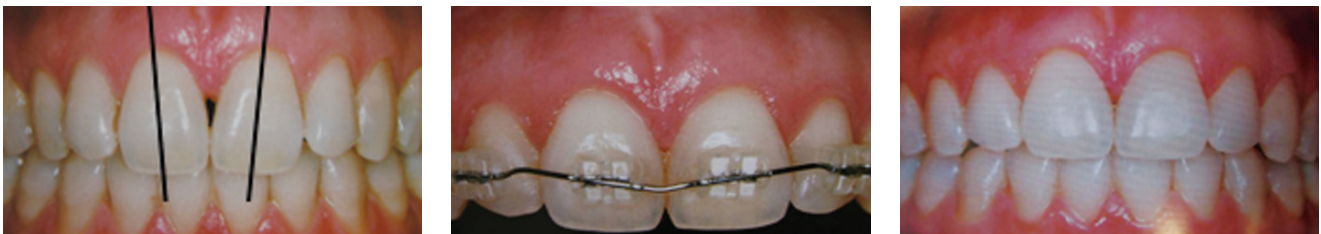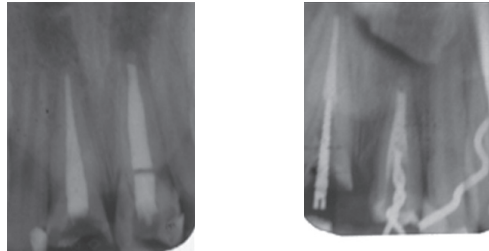


Fig. 4: Black triangle between maxillary central incisors (divergent roots) corrected orthodontically.

In both options, the length of the root is a crucial parameter mainly to support a post crown and to finish with an optimal crown to root ratio.

In summary, the subsequent factors should be considered in planning extrusion of teeth:

- Root length and form: thick, non-tapered.
- Level of defect or fracture.
- Relative importance of the tooth.
- Esthetic considerations: amount of visible gingiva upon smiling.
- Endodontic considerations: good endodontic treatment, retreatment or apicectomy (endodontic lesions)
- Periodontal considerations, including contra-indication of periodontal crown lengthening as:
 - Adjacent root exposure due to flap design.
 - Loss of the interdental papillae.
 - Uneven gingival margins [7].

Forced eruption technique is a method of orthodontic crown lengthening

where tooth extrusion is promptly achieved without the pursuing of the periodontium basically the bone (Fig. 3).

Improvement of gingival esthetics

Interdental papilla

Open gingival embrasures or black triangles (Fig. 4) observed in the cervical region between the teeth result from a deficit of gingival papilla below the proximal contact points [8].

The contributing factors to this unaesthetic situation are numerous and summarized as follows:

- 1- Age.
- 2- Attachment loss subsequent to periodontal surgery or to periodontal disease.
- 3- Severe crowding specially of maxillary and mandibular incisors. Although according to Kokish [9], pretreatment maxillary central incisor rotation and overlap are not directly associated with post-treatment open gingival embrasures.

4- Triangular-shaped crown with or without bone resorption [10].

5- An increased distance from the alveolar bone to the interproximal contact resulting from a bone loss or from more incisally positioned interproximal contacts [11].

6- Divergent roots [12].

Treatment of black triangles depends first on a thorough evaluation of the etiology in order to insure the best outcome. Emphasize on the interdisciplinary management of the cases is primordial with an ultimate collaboration between the general dentist, the periodontist and the orthodontist.

The prevalence of open gingival embrasure between maxillary central incisors after orthodontic treatment of adult patients is estimated to be around 40% [13, 14]. The age, the duration of active treatment and the crown morphology were the parameters involved in the occurrence of black triangles between mandibular incisors after orthodontic treatment [15].

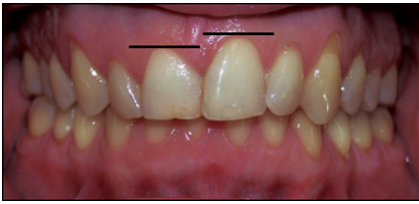

Fig. 5: Uneven gingival margins due to abrasion of incisal edge of the tooth #11 orthodontically corrected.

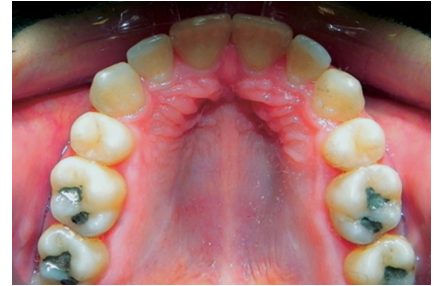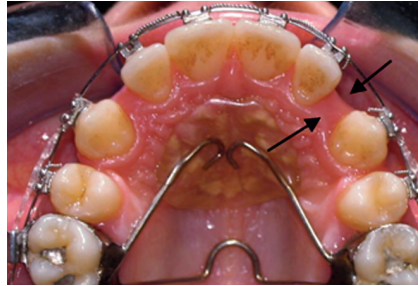
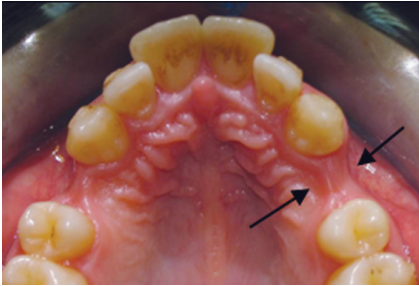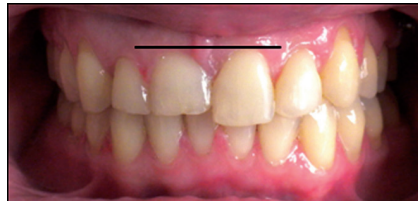


Fig. 6: Retraction of canines in old extraction site had enhanced the bucco-lingual width of alveolar bone.

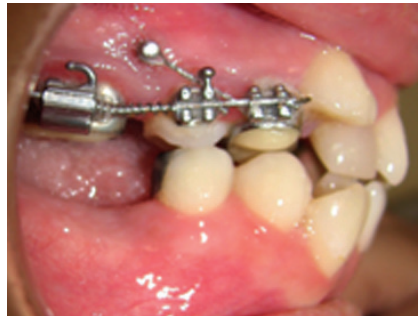
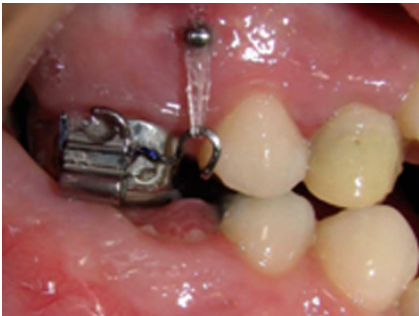
Fig. 7: Intrusion of maxillary 1st molar creating the needed space for the restoration of the mandibular opposite site. Orthodontic treatment was initiated to correct the crowding and manage the optimal space vertically and sagittally for proper restoration of mandibular edentulous space.

Gingival margins

Uneven gingival margins are a major aesthetic problem especially in patients with gummy smile. They can result from inflammatory periodontal diseases or from variable amount of tooth wear and abrasion on different adjacent teeth (Fig. 5).

In some cases, orthodontic intrusion and restoration of incisal edge are required.

The determining factors to correct the gingival margins include the sulcus depth, the location of the cemento-enamel junction relative to the bone level, the amount of existing tooth structure, the root-to-crown ratio and the shape of the root [16].

The gingival margin of the central incisors must be at the same level and the lateral incisors gingival level

should be slightly more occlusal than the canines and the central incisors. The contour of the gingival margin should mimic the cemento-enamel junction (CEJ) of the teeth.

Horizontal bone regeneration

Orthodontic sagittal movement can be a substitute for guided bone regeneration, surgical bone augmentation or bone grafting (Fig. 6). Atrophic bone in sites of tooth agenesis or previous extraction of permanent teeth prevents the placement of implant in these areas without requiring a bone augmentation surgical procedure. However, moving orthodontically a tooth in such atrophic areas can resolve the problem by developing alveolar bone on the tension side enhancing the width of the crestal bone [17, 18, 19]. Spears

et al. [20] revealed that bone created by orthodontic separation of two teeth is much less resorptive over time compared to the amount of resorption following tooth extraction.

Vertical bone regeneration

Orthodontic extraction of an unrestorable tooth is an advantageous and an effective way to enhance the periodontal conditions for the replacing implant [21, 22]. Such orthodontic extrusion will improve the alveolar bone and the gingival characteristics of the recipient site prior to the placement of an implant. Furthermore, it is considered as a viable alternative to the conventional surgical augmentative procedures of bone in height [23, 24]

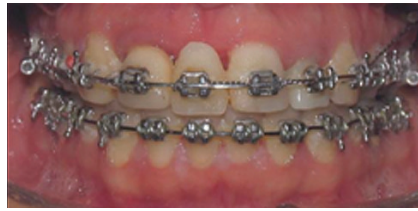
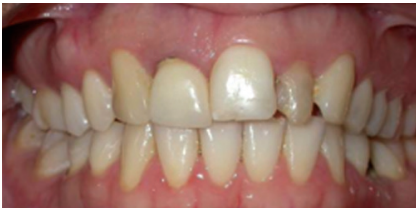
Fig. 8: Reopening of an adequate space for the maxillary right central incisor that was substituted by the lateral incisor.

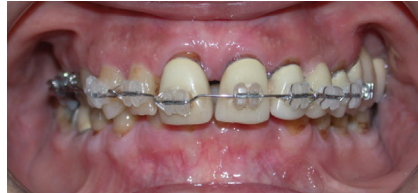
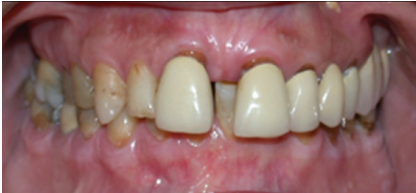
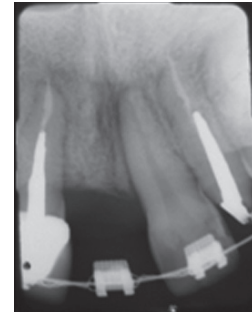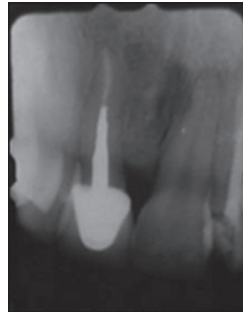Fig. 9: Closure of maxillary midline diastema and distribution of space between all anterior teeth that will be restored with new crowns.



Dental Management

Inter-arch space management

Orthodontic intrusion to recreate an adequate prosthetic space can be a substitute for coronoplasty and crown lengthening or extraction (Fig. 7).

Intra-arch space management

Opening an optimal space for a missing tooth especially in the anterior and premolar areas has an important impact on perceived smile aesthetics (Fig. 8). Proportional width of teeth relative to each others should be considered in order to manage the proper space for a pleasant result [25]. Along the crown, the width of the contralateral will be the reference in case of unilateral missing teeth. Along the crest, 1mm between implant and adjacent teeth is required for creating adequate papillae [26].

Diastema closure is attributed to aesthetic and psychological reasons rather than to functional ones. Management of maxillary diastema should resolve its etiology and cause [27, 28, 29]. Oral habits, muscular imbalances, tooth-size discrepancies, pathological conditions as ectodermal dysplasia, abnormal maxillary arch structure in cleft lip and palate patients, and various dental anomalies (supernumerary teeth, cysts...) are all etiological factors causing a diastema.

The closure of maxillary diastemas is facilitated by a multidisciplinary approach [30] (Fig. 9) involving orthodontics [31, 32], restorative dentistry [33, 34, 35] and surgery.

According to Mulligan [36], controlling the divergence of the incisal axis and the vertical effects of occlusal forces must be considered for long-term stability of the result much more than the efficiency of the retainer.

Restoring tooth proportions

The aesthetic rehabilitation of maxillary anterior teeth should emphasize the importance of the width/length ratio. The measurements of these teeth are different and variable in width and length. The width/length ratio of maxillary central incisors is the largest (85%) while the smallest ratio is for the maxillary lateral incisors (79%) and the intermediate one is for the canines (83%) [37, 38]. These dimensions give a positive impact on the esthetic assessment of the final restorations.

To restore an abraded dentition in addition to an edge to edge anterior relationship (Fig. 10), an orthodontic treatment is necessary in order to create the needed overjet and overbite for the reestablishment of the optimal aesthetic height. In most instances, conservative aesthetic therapies, such as porcelain crowns, supplement

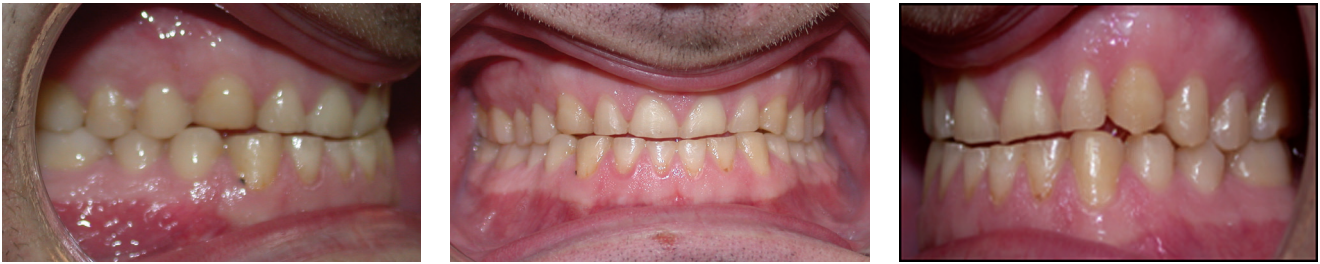

Fig. 10: Abraded anterior teeth in edge to edge relationship. Notice that the maxillary anterior teeth are not visible upon smiling.

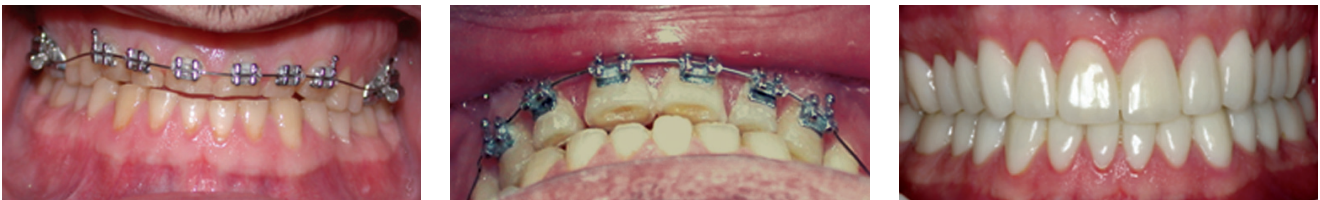
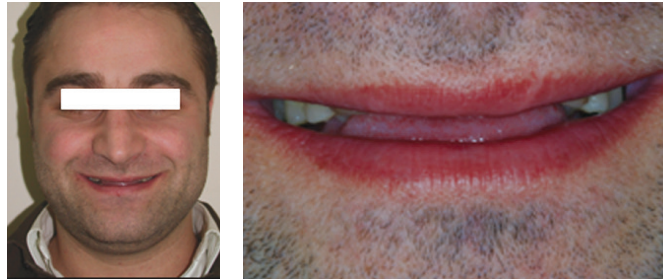
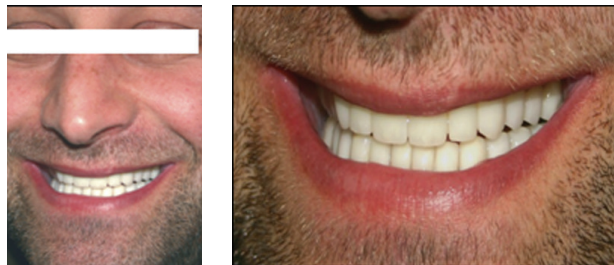Fig. 11: Orthodontic treatment recreates the appropriate overjet for full mouth restoration with ceramic crowns.



orthodontic therapy to create a final result are possible only with singular approach (Fig. 11).

Discussion

General dentists are the first to refer patients for a needed orthodontic intervention in order to correct a malocclusion or to improve the status of the supporting structures. Optimizing a healthy environment for dental restorations is crucial for the longevity and stability of the outcomes.

Furthermore, the impact of the media raising the slogan of Hollywood smile has lift up the challenge toward a very high level of aesthetic acceptance and execution which define new criteria of a "beautiful smile". This motto led to introduce the porcelain veneer restorations and lumineers to the dental practice and to execute a beautiful smile without implementing any orthodontic treatment. Such alternative has some limitations regarding the correction of gingival margins and papilla [39] and in some cases is less conservative.

An appropriate referral of patients and fine considerations of the available orthodontic treatment possibilities, limitations and risks are prevalent factors for general practitioners to admit any needed adjunctive dental treatment [40]. The orthodontic- prosthodontics - periodontic collaboration was conducted a long time ago [41] to assist dentists in their practice. Patients should be informed about the ideal treatment option before considering the compromised approaches that should be discussed thoroughly wei-

Treatment	Advantages	Disadvantages
Orthodontics	<ul style="list-style-type: none"> - Fewer restorations - No root canals or periodontal surgery - Less cost 	<ul style="list-style-type: none"> - Longer treatment - Need for retention
Non orthodontics	<ul style="list-style-type: none"> - Less time involvement 	<ul style="list-style-type: none"> - Increased cost - More restorations - Aggressive tooth Preparation - Periodontal surgery needed

Table 1: Comparison of orthodontic and non orthodontic treatments.

ghting their risks and benefits. Finally, the advantages and disadvantages of orthodontic versus non orthodontic approaches in the comprehensive rehabilitation of oral form and function, especially when anterior restoration is needed can be summarized in table1.

References

- Mihram W and Murphy N. The Orthodontist's role in 21st century periodontic-prosthetic therapy. *Semin Orthod* 2008;14:272-289.
- Cohen BD. The use of orthodontics before fixed prosthodontics in restorative dentistry. *Compendium*. 1995;16(1):110, 112, 114.
- Aggarwal V, Logani A, Shah N. Complicated crown fractures - management and treatment options. *Int Endod J*. 2009 ; 42(8):740-53.
- Hempton TJ, Dominici JT. Contemporary crown-lengthening therapy: a review. *J Am Dent Assoc* 2010;141(6):647-55.
- Yeh S, Andreana S. Crown lengthening: basic principles, indications, techniques and clinical case reports. *N Y State Dent J*. 2004;70(8):30-6.
- Camargo PM, Melnick PR, Camargo LM. Clinical crown lengthening in the aesthetic zone. *J Calif Dent Assoc*. 2007;35(7):487-98.
- Kokich VG. The role of orthodontics as an adjunct to periodontal therapy. In: Newman MG, Takei HH, Carranza FA. *Carranza's Clinical Periodontology*. W.B. Saunders Company. Philadelphia. 10th ed. 704-718.
- Sharma AA, Park JH. Esthetic considerations in interdental papilla: remediation and regeneration. *J Esthet Restor Dent*. 2010 Feb;22(1):18-28.
- Spear FM, Mathews DM, Kokich VG. Interdisciplinary management of single-tooth implants. *Semin Orthod* 1997;3:45-72.
- Bennett JC. *The future of orthodontics*. Belgium:Leuven University Press; 1998.
- Tarnow DP, Magner AW, Fletcher P. The effect of the distance from the contact point to the crest of bone on the presence or absence of the interproximal dental papilla. *J Periodontol* 1992;63:995-996.
- Zachrisson BU. *Orthodontic and Periodontics. Clinical Periodontology and Implant Dentistry – Jan Lindhe*. 4th ed. 2005; 576p.
- Tanaka OM, Furquim BD, Pascotto RC, Ribeiro GL, Bósio JA, Maruo H. The dilemma of the open gingival embrasure between maxillary central incisors. *J Contemp Dent Pract*. 2008 ;9(6):92-8.

14. Burke S, Burch JG, Tetz JA. Incidence and size of pretreatment overlap and post-treatment gingival embrasure space between maxillary central incisors. *Am J Orthod Dentofacial Orthop.* 1994;105(5):506-11.
15. Ikeda T, Yamaguchi M, Meguro D, Kasai K. Prediction and causes of open gingival embrasure spaces between the mandibular central incisors following orthodontic treatment. *Aust Orthod J.* 2004 ;20(2):87-92.
16. Kurth VA, Kokich VG. Open gingival embrasures after orthodontic treatment in adults: Prevalence and etiology. *Am J Orthod Dentofacial Orthop* 2001;120:116-23.
17. Perregaard J, Holmqvist-Larsen M. Interdisciplinary dentistry in practice. *Nordic Dentistry 2003 Yearbook.*Copenhagen: Quintessence, 2003:41–61.
18. Thilander B, Odman J, Lekholm U. Orthodontic aspects of the use of oral implants in adolescents: A 10-year follow-up study. *Eur J Orthod* 2001;23:715–731.
19. Zachrisson BU. Orthodontics and Periodontics. In: Lindhe J, Karring T, Lang N. *Clinical Periodontology and Implant Dentistry.* Blackwell Publishing Company. Oxford UK. 4th ed. 744-780.
20. Spear FM. The esthetic correction of anterior dental malalignment conventional vs. instant (restorative) orthodontics. *J Calif Dent Assoc* 2004;32(2):133-41.
21. Kan JY, Rungcharassaeng K, Fillman M, Caruso J. Tissue architecture modification for anterior implant esthetics: an interdisciplinary approach. *Eur J Esthet Dent* 2009;4(2):104-17.
22. Brindis MA, Block MS. Orthodontic tooth extrusion to enhance soft tissue implant esthetics. *J Oral Maxillofac Surg.* 2009;67(11 Suppl):49-59.
23. Korayem M, Flores-Mir C, Nassar U, Olfert K. Implant site development by orthodontic extrusion. A systematic review. *Angle Orthod.* 2008;78(4):752-60.
24. Kim SH, Tramontina VA, Papalexioiu V, Luczyszyn SM. Orthodontic extrusion and implant site development using an interocclusal appliance for a severe mucogingival deformity: a clinical report. *J Prosthet Dent.* 2011;105(2):72-7.
25. Condon M, Bready M, Quinn F, O'Connell BC, Houston FJ, O'Sullivan M. Maxillary anterior tooth dimensions and proportions in an Irish young adult population. *J Oral Rehabil.* 2010;1365-2842.
26. Kokich VG., Spear FM.. Guidelines for managing the orthodontic-restorative patient. *Seminars in Orthodontics* 1997;3(1):3-20.
27. Duarte S Jr, Schnider P, Lorezon AP. The importance of width/length ratios of maxillary anterior permanent teeth in esthetic rehabilitation. *Eur J Esthet Dent.* 2008;3(3):224-34.
28. Gillen RJ, Schwartz RS, Hilton TJ, Evans DB. An analysis of selected normative tooth proportions. *Int J Prosthodont.* 1994;7(5):410-7.
29. Oesterle LJ, Shellhart WC. Maxillary midline diastemas: a look at the causes. *J Am Dent Assoc.* 1999 ;130(1):85-94.
30. Gkantidis N, Kolokitha OE, Topouzelis N. Management of maxillary midline diastema with emphasis on etiology. *J Clin Pediatr Dent.* 2008;32(4):265-72.
31. Huang WJ, Creath CJ. The midline diastema: a review of its etiology and treatment. *Pediatr Dent.* 1995;17(3):171-9.
32. Oquendo A, Brea L, David S. Diastema: correction of excessive spaces in the esthetic zone. *Dent Clin North Am.* 2011;55(2):265-81.
33. Heymann HO, Hershey HG. Use of composite resin for restorative and orthodontic correction of anterior interdental spacing. *J Prosthet Dent.* 1985;53(6):766-71.
34. Hohlt WF, Hovijitra S. Management of anterior spacing with orthodontics and prosthodontics. *J Indiana Dent Assoc.* 1999;78(3):18-23.
35. De Araujo EM Jr, Fortkamp S, Baratieri LN. Closure of diastema and gingival recontouring using direct adhesive restorations: a case report. *J Esthet Restor Dent.* 2009;21(4):229-40.
36. Wolff D, Kraus T, Schach C, Pritsch M, Mente J, Staehle HJ, Ding P. Recontouring teeth and closing diastemas with direct composite buildups: a clinical evaluation of survival and quality parameters. *J Dent.* 2010; 38(12):1001-9.
37. Lenhard M. Closing diastemas with resin composite restorations. Closing diastemas with resin composite restorations. *Eur J Esthet Dent.* 2008;3(3):258-68.
38. Mulligan TF. Diastemas: is retention necessary. *Int Orthod.* 2009;7(1):55-70.
39. Jacobson N, Frank CA. The Myth of Instant Orthodontics: An Ethical Quandary. *J Am Dent Assoc* 2008;139(4):424-434.
40. Mavreas D, Athanasiou AE. Orthodontics and its interactions with other dental disciplines. *Progress in Orthodontics* 2009;10:72-81.
41. Evans CA , Nathanson D. Indications for orthodontic-prosthodontic collaboration in dental treatment. *J Am Dent Assoc.* 1979;9(5):825-830.