

# MAXILLARY SINUS AUGMENTATION BY THE CRESTAL APPROACH: RADIOGRAPHIC CHANGES IN GRAFT HEIGHT. A 1-YEAR RETROSPECTIVE STUDY

Nareg Bananian\* | Georges Tawil\*\* | Nada Bou-Abboud Naaman\*\*\*

## Abstract

The purpose of this study is to evaluate, radiographically, the change in intra-sinus graft height after implant placement using inorganic mineral bovine bone and the osteotome technique.

Thirty-one implants were placed in twenty-five patients with simultaneous sinus lift using the crestal approach and deproteinized bovine bone (Bio-Oss®). Periapical radiographs were taken immediately after implant placement, after six months (healing period), and after a minimum of six months of loading. Changes of the graft height were evaluated using image analysis software (Image Tool for Windows, version 3, UTHSCA). The distance between the implant apex and the graft summit was measured along the longitudinal axis of the implant (distance D). This distance was consecutively measured on radiographs taken immediately after surgery (D0), at second stage surgery (D6), and at follow-up visits (D12). Only 25 out of 31 implants were included to analyze the variation in the distance D in time (D6 and D12). Statistical analysis showed a significant difference between D0 and D6 ( $p < 0.0001$ ), between D6 and D12 ( $p < 0.002$ ), and between D0 and D12 ( $p < 0.001$ ). The graft lost 27.4% of its apical height after twelve months.

Within the limitations of the present study it was found that the use of deproteinized bovine bone, which has a very slow resorption rate, could not prevent changes in the initially gained intra-sinus graft height. However, the reported results showed that its use was beneficial in limiting the loss of the augmented height to a minimum.

**Key words:** Sinus - osteotome technique - bone graft - dental radiographs - healing.

IAJD 2012;3(2):47-53.

## AUGMENTATION DU SINUS MAXILLAIRE PAR APPROCHE CRESTALE: LES CHANGEMENTS RADIOGRAPHIQUES DE LA HAUTEUR DE LA GREFFE.

### Résumé

Le but de l'article est d'évaluer, rétrospectivement, le changement de la hauteur de la greffe intra-sinusienne après mise en place de l'implant. Vingt-cinq patients ont reçu trente et un implants avec augmentation sinusienne simultanée en utilisant une approche crestale et de l'os bovin déprotéinisé (Bio-Oss®). Des radiographies périapicales ont été prises au moment de la pose de l'implant, après six mois (période de cicatrisation), et après une période minimale de six mois de mise en charge. Un software spécifique (Image Tool for Windows, version 3, UTHSCA) a été utilisé pour analyser les radiographies. La distance entre le sommet de l'implant et le sommet de la greffe a été mesurée le long de l'axe longitudinal de l'implant (distance D). Cette distance a été évaluée sur des radiographies prises immédiatement après la chirurgie (D0), lors de la chirurgie du deuxième temps (D6), et à des visites de suivi (D12). Seulement 25 des 31 implants ont été inclus pour analyser la variation de la distance D dans le temps. L'analyse statistique a montré une différence significative entre D0 et D6 ( $p < 0.0001$ ), entre D6 et D12 ( $p < 0.002$ ), et entre D0 et D12 ( $p < 0.001$ ). Le greffon a perdu 27.4% de sa hauteur apicale après 12 mois.

Dans les limites de la présente étude, il a été constaté que l'utilisation de l'os bovin déprotéinisé, qui a un taux de résorption très lent ne pouvait prévenir les changements de la hauteur gagnée par la greffe sinusienne. Cependant, les résultats rapportés ont montré que son utilisation a été bénéfique en limitant la perte de la hauteur augmentée à un minimum.

**Mots- clés :** sinus - ostéotome - greffe osseuse – radiographie – cicatrisation.

IAJD 2012;3(2):47-53.

\* Master in Periodontology  
Faculty of Dentistry,  
Saint-Joseph University of Beirut  
naregdr@email.com

\*\* DSc Od  
Professor, Faculty of Dentistry,  
Saint-Joseph University of Beirut

\*\*\* PhD  
Dean,  
Professor, Dpt of Periodontics,  
Faculty of Dental Medicine,  
Saint-Joseph University of Beirut.

## Introduction

The edentulous posterior segments of the maxilla are often characterized by severe bone resorption and pneumatization of the maxillary antrum, compromising rehabilitation with implant supported prostheses [1]. Sinus floor elevation restores the height of available bone in the posterior maxilla, thus allowing the placement and integration of endosseous implants. The conventional procedure provides access through the lateral wall of the antrum [2]. Tatum in 1986 [3] proposed a different technique, the crestal approach. However, it was not until 1994 that Summers described the use of specifically designed instruments called osteotomes, hence the “osteotome technique”, to compress bone and elevate the sinus floor under malleting forces [4]. Clinical studies reported favorable long-term outcomes using this technique [5-8]. However, the discrepancy in the reported success/survival rates (between 88.6 % and 100 %) were attributed to some confounder factors such as the residual bone height, the type of implant used and the surgical technique.

Long-term stability of the initially regenerated bone is a concern regardless the site and the type of surgical procedure. Pneumatization of the maxillary sinus continues even after sinus floor elevation; this can lead to loss in the intra-sinus graft height [9]. Using the conventional technique, few studies observed these changes and reported that the amount of loss in the initially gained height was related to the type of grafting material used [10-12]. With the osteotome technique, Bragger et al. [13] used a combination of autogenous bone and deproteinized bovine bone (Bio-Oss®); they reported a considerable loss in the apical graft height after twelve months [13].

Since Bio-Oss® was reported to have a very slow resorption rate [14, 15], the aim of this study was to observe, radiographically, the changes in the apical graft height in sinuses grafted with deproteinized bovine bone alone

Implant Type	Frequency	Percent
3I®	8	25.8
Brånemark®	13	41.9
Xive®	4	12.9
Replace®	2	6.5
Screw Vent®	2	6.5
ITI®	2	6.5
Total	31	100.0

Table 1: Types of implants used.

with simultaneous implant insertion using the osteotome technique.

## Materials and Methods

The files of patients who underwent osteotome sinus floor elevation in three specialized periodontal clinics were screened. Cases were selected based on the following criteria:

- Osteotome sinus floor augmentation was performed using deproteinized bovine bone as the grafting material.
- Implants had been loaded for a minimum of six months.
- Standardized periapical radiographs were taken at the following intervals: preoperative, immediately after implant insertion, at the second stage surgery for submerged implants, or at 4 to 6 months for trans-mucosal implants, and at follow-up visits between 6 to 12 months.
- The following landmarks could be clearly identified on consecutive radiographs: the entire length of the implant, at least two to three millimeters past the cranial end (or summit) of the intra-sinus graft.
- Implants should fulfill the success criteria described in 1986 by Albrektsson et al. [16] during the period covered by the study.

Twenty-five patients fulfilled the selection criteria. They received thirty-one implants, each inserted with simultaneous sinus augmentation using the crestal approach. The mean age of the patients was  $47.96 \pm 10.350$

(range: 28 to 65 years). Ten were males (40%), 15 were females (60%). Only two patients (8%) were smokers.

## Surgical treatment

The surgical procedure was performed using either the modified osteotome sinus floor elevation technique as described by Davarpanah [17], or a modified technique similar to that described by Ferrigno et al. [5].

All sites were grafted with deproteinized bovine bone, namely Bio-Oss® (Geistlich Sons Ltd, Wolhusen, Switzerland). Six different types of textured surface implants were used (Table 1). Implant length varied between 8.5- to 12-mm, the majority (71.0%) were 10-mm long. Implant diameter varied between 3.75 and 5 mm, most were either 4 or 5 mm. 23 implants (74.2%) were inserted at first and second molar sites, the remainder 8 implants (25.8%) at the second premolar site.

Healing periods extended from 4 to 9 months, the majority of implants (83.9%) were allowed to heal for 6 months, and 80.6% in a submerged manner, the rest (19.4%) had a trans-mucosal healing. Restorative treatment was either a single crown (35.5%), or two- to three-unit implant supported fixed partial denture (64.5%).

## Radiographic analysis

All periapical radiographs were taken using extension cone paralleling technique (XCP instruments, Rinn Corporation). Some were taken using

a digital sensor, others were conventional. Each conventional radiograph was digitized by placing it against an illuminated X-ray viewer using a digital camera (Canon Digital Rebel XT® Clinical – Sigma EM-140DG); a picture of the radiograph was taken and transferred to the computer.

Analysis was performed using a computerized measuring technique with image analysis software (Image Tool for Windows, version 3, UTHSCSA). The software allows for internal calibration performed for each radiograph using either the known implant length as a reference, or the distance between three consecutive threads (based on the distance between two consecutive threads as detailed by the manufacturer). The precision of the measuring system is 0.01 mm. In order to improve the quality of the images, and hence analysis, image-enhancement procedures were performed. These included sharpening, brightness, contrast and color to gray-scale.

Figure 1 details the distances measured on each radiograph:

Distance A: The residual bone height (RBH): The distance between the most coronal bone to implant contact to the original sinus floor.

Distance B: The length of the part of the implant protruding into the sinus, measured from the most apical bone to implant contact (original sinus floor) to the implant apex parallel to the long axis of the implant.

Distance C: The height of the intra-sinus graft immediately after surgery. This distance was measured along the axis of the implant from the most apical bone to implant contact (original sinus floor) to the graft summit.

Distance D: The distance between the implant apex and the graft summit as measured along the longitudinal axis of the implant. This distance was consecutively measured on radiographs taken immediately after surgery, at the second stage surgery, and at follow-up visits. The change in this distance reflects change in the intra-sinus bone height. It had a positive value when the graft summit was api-

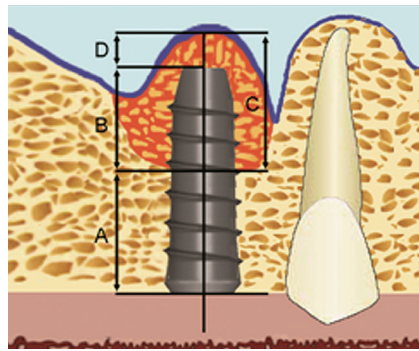


Fig. 1: Diagram illustrating the distances measured on each radiograph.

Distance A: The residual bone height (RBH); distance B: The length of the part of the implant protruding into the sinus; distance C: The height of the intra-sinus graft immediately after surgery; distance D: the distance between the implant apex and the graft summit.

cal to the implant apex, and a negative value when the implant apex was higher than the graft.

### Statistical analysis

The statistical analysis was performed using a software program (SPSS for Windows version 11.0). Each outcome (distance) was scored two times by the same evaluator. For statistical analysis, the average of the two measures was obtained. The reproducibility among measures was evaluated using Pearson product-moment correlation coefficient. The normal distribution of the data was tested using the Kolmogorov Smirnov test.

The statistical analysis included descriptive statistics and non parametric analysis of variance (Friedman test) followed by the Wilcoxon sign rank tests with the Bonferroni correction, for determination of differences in distance between reference points measured after implant insertion, after 6 and 12 months. Relationships between measurements and time were evaluated using linear regression analysis. The relationship between distances was investigated using Pearson correlation coefficient. Paired t-test was used to compare two distances in the same group. The “implant” was defined as the statistical unit. The test was two-sided and a significance of 5% or less was considered statistically significant.

### Results

The quality of bone encountered was type III in the majority of the sites

(80.6%), only few sites (19.4%) exhibited type II bone.

### Radiographic analysis

All measurements were performed by one operator (N.B.) at two different time points. The coefficient of correlation “rho” demonstrated a strong reproducibility between measurements towards +1.

The mean preoperative residual bone height (distance A) was  $6.44 \pm 1.62$  mm ranging from 2.17 mm to 9.34 mm. In 27 out of 31 sites ( $\approx 85\%$ ), this distance was more than 5 mm. Around 35.4% of all sites had less than 6 mm preoperative bone height (Fig. 2).

Figure 3 depicts the measured values for distance B. The mean length of the part of the implant protruding into the sinus was  $3.47 \pm 1.28$  mm ranging from 0.79 to 5.51 mm. In twenty-one out of 31 sites ( $\approx 67.7\%$ ), the implants protruded more than 3 mm past the original sinus boundaries, and more than 4 mm in around 38.7% of the sites.

The post-operative intra-sinus graft height (distance C) was  $4.91 \pm 1.52$  mm. It ranged from 1.33 to 7.16 mm. Distance C was greater than 5 mm in 17 out of 31 sites ( $\approx 54.5\%$ ), and more than 6 mm in 25.8% (8 out of 31 sites) of the sites (Fig. 4).

In all thirty-one sites, the sinus graft covered the implant apex as evident in periapical radiographs taken immediately postoperatively. At implant insertion, the mean distance between the graft summit and implant apex (distance D0) was  $1.70 \pm 0.85$  mm, ranging from 0.47 to 4.48 mm (Fig. 5). In fourteen out of 31 sites (45.4%), distance D0 was greater than 1.5 mm,

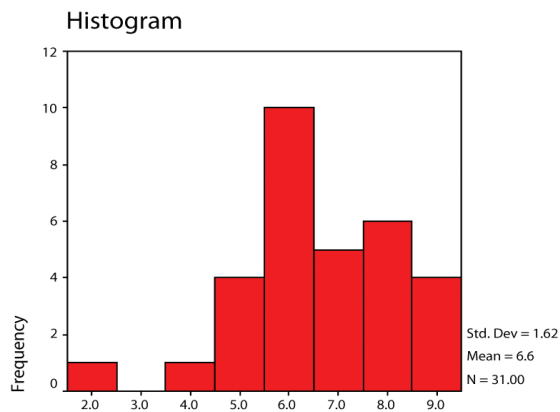


Fig. 2: Residual bone height (distance A).

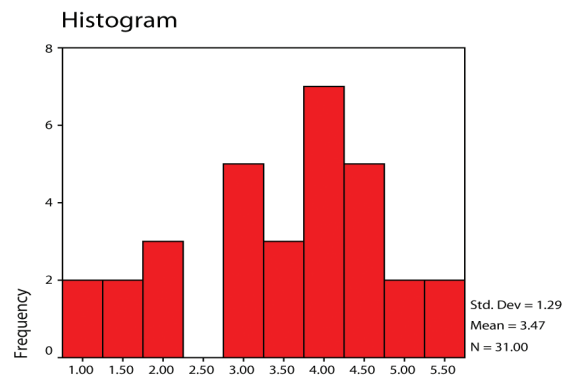


Fig. 3: Length of implant protruding into the sinus (distance B).

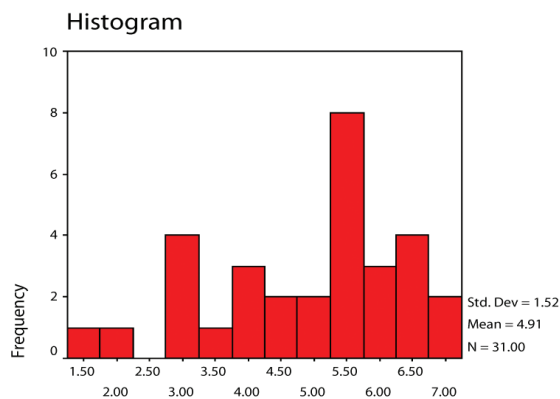


Fig. 4: Distance between graft summit and first apical BIC at baseline (distance C).

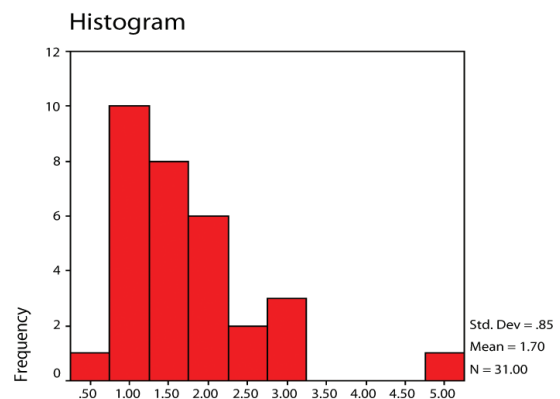


Fig. 5: Distance between graft summit and implant apex at baseline (distance D).

while it was greater than 2mm in only 25.8% of the sites (8 out of 31 sites).

### Changes of distance D in time

Only 25 out of 31 implants were included for this analysis due to lack of radiographs taken at one of the two follow-up periods (either during the first 6 months or after 12 months).

Figure 6 presents the changes in distance D from implant insertion through the follow-up periods. The apical graft height was reduced from  $1.7 \pm 0.85$  mm at implant insertion (D0) to  $1.49 \pm 0.77$  mm during the first 6 months (D6). Further reduction to  $1.11 \pm 0.74$  mm was observed after 12 months (D12).

Using the Wilcoxon Signed Ranks tests with the Bonferroni correction, statistically significant differences were found between baseline (D0) and

(D6) ( $p < 0.0001$ ), between (D6) and (D12) ( $p < 0.002$ ), and between (D0) and (D12) ( $p < 0.001$ ).

Table 2 shows the mean percentage of loss in apical graft height observed between the observation periods.

As illustrated in table 2, the graft lost 27.4% of its apical height after twelve months. Moreover, although not statistically significant, the loss of apical graft height was greater between (D6) and (D12), as compared to that observed between (D0) and (D6).

Using the Pearson product-moment correlation coefficient, a strong, positive correlation was found between distance B (length of implant protruding into the sinus at baseline) and distance C (the post-operative intra-sinus graft height) [ $r = 0.882$ ,  $n = 31$ ,  $p < 0.0001$ ], with high levels of distance B associated with high levels

of distance C. In addition, there was a medium positive correlation between distance C and distance D0 (apical graft height at baseline) [ $r = 0.443$ ,  $n = 31$ ,  $p = 0.013$ ], with high levels of distance C associated with high levels of distance D0. However, no correlation could be found between distance B and distance D0, between distance B and distance D12, or between distance C and distance D12.

Figure 7 shows the radiographic changes observed during the one year observation period. In most cases the new sinus floor is demarcated with well defined boundaries.

### Discussion

The crestal approach for sinus floor elevation offers a less invasive technique when compared to the lateral

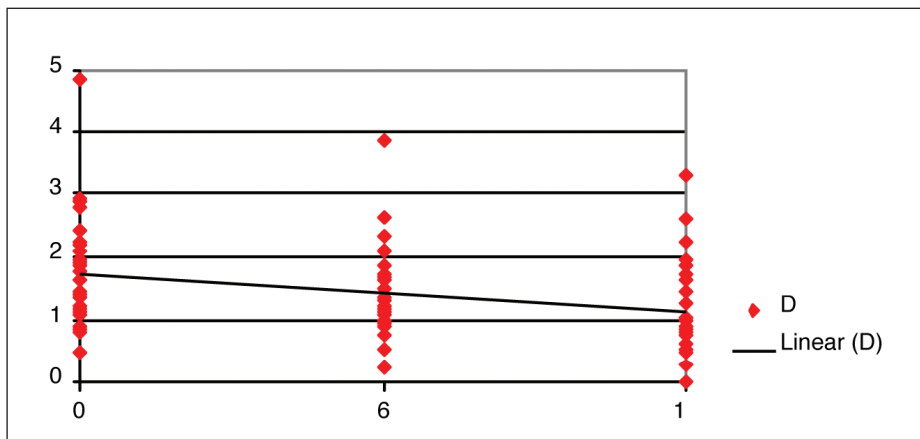


Fig. 6: Changes of distance D in time.

	Between(D0) & (D6)	Between (D6) & (D12)	Between (D0) & (D12)
% loss in apical graft height	13.7%	14.7%	27.4%
The 95% confidence interval	[7.27%-20.1%].	[7.04%-22.32%]	[19.7%-35.1%]

Table 2: Mean percentage of loss in apical graft height observed between the observation periods.

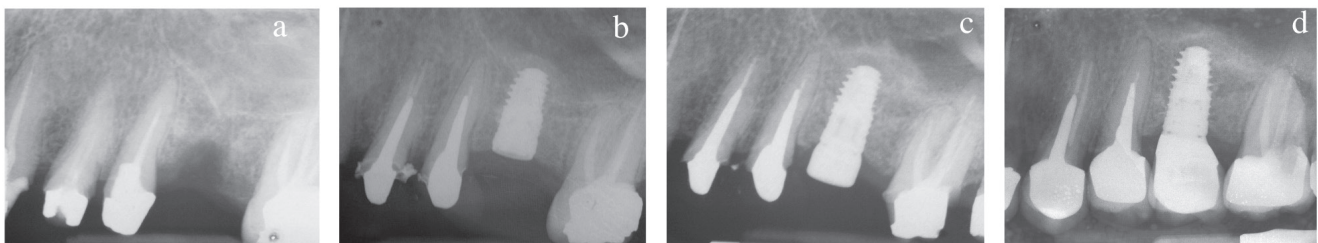


Fig. 7: Consecutive radiographs showing graft consolidation and the formation of new sinus floor. a: pre-operative; b: after surgery; c: at 2nd stage surgery (6 months); d: at twelve months (D0, D6 and D12)..

window approach, to compensate for the vertical inadequacy of the residual bone height in the posterior segments of the maxilla. However, it is not the aim of the present study to address the predictability of this technique. Rather, it describes the changes of the apical graft height within a one year period, after functional loading of the implants for a minimum of 6 months. Consequently, only cases which fulfilled previously described success rates for implants along with adequate clinical and radiographic documentations were included in the study.

Residual bone height is considered the most important factor in determining the success of the osteotome

technique. Few studies evaluated success/survival rates as a function of RBH. Rosen et al. [18], using the bone added osteotome sinus floor elevation technique, reported 96% or higher survival rate when pretreatment bone height was 5 mm or more. These values dropped to 85.7% when pretreatment bone height was 4 mm or less. More recently, Toffler [19] described a similar trend in a clinical report. An overall survival rate of 93.5% was reported for 276 implants. However, when sites with a residual bone height of 4mm or less were only considered, the survival rate dropped to 73.3%. In the present study, the mean RBH was  $6.44 \pm 1.62$  mm which might explain the good per-

formance of implants included in this study.

In a human cadaver study, Reiser et al. [20] reported that the incidence of class II membrane perforations increased whenever the sinus membrane was elevated 6 mm or more using osteotomes. In the present study, the mean value of distance C was  $4.91 \pm 1.52$  mm. But even in sites where the sinus membrane was elevated up to 7.16 mm, periapical radiographs showed a clearly visible dome-shaped area beyond the apex of the implant and no collapse of the grafted area was observed on the consecutive radiographs.

Few *in vitro* studies evaluated stress distribution around implants placed in augmented sinuses. Fanuscu et al. [21] designed composite photoelastic models to simulate conditions before sinus grafting and at various stages of graft maturation. The stress analysis indicated that before placement of the simulated graft, loading on the implant transferred the highest stresses to cortical bone. As the model simulated more advanced stages of graft maturation, proportionately increased stresses developed around the apical portion of the implant and the graft assumed a greater proportion of the load, with concomitant stress reduction in the native bone simulants.

In a three-dimensional finite element analysis, Tepper et al. [22] designed several models which mimicked different sinus graft conditions to evaluate the surgical procedure and the amount of peri-implant packing that would yield the best bony support for dental implants. Clinical conditions were simulated with only 5.3 mm of sub-antral bone height. The results showed that in models with adequately regenerated intra-sinus bone, interfacial stresses were 30-50% lower than in the reference models with no or inadequate (1 mm) packing. Moreover, complete packing around the implant reduced 30-45% of the cortical stresses as compared to no grafting or to a thin peri-implant bone sheath (1 mm). Based on these results, the authors recommended that as much as of the space available for sinus floor elevation should be packed with grafting material up to the apical implant bed. With the osteotome technique the amount of grafting material packed around the implant tip is generally limited. Moreover, maxillary sinus pneumatization is a continuous process that could lead to bone resorption even after sinus floor augmentation. Consequently, in time, the reduction in apical graft volume increases the stress values generated in the bone surrounding the implant, even if the prosthetic loads are the same. This combined with the often poor quality

of bone encountered in the posterior maxilla, and the increased occlusal loads in the posterior segments of the jaws would compromise the bone to implant integration. Hence, the physical stability of the graft is important for the mechanical stability of the implant.

For the conventional sinus floor elevation, few studies investigated the changes in the height and volume of the sinus graft in time. These studies showed that regardless the type of graft, there was a gradual decrease in graft height over the observation periods. In the 1996 sinus floor elevation consensus conference [10], changes in sinus graft height of 9 different graft materials and various graft combinations were evaluated. In the 3-year time frame, the data showed that the least change in graft height was observed for the combination of an autograft (intra-oral bone) and an alloplast (mostly porous Hydroxyapatite) with a mean bone loss of 0.79 mm. The greatest loss in graft height was observed for the freeze-dried demineralized bone (DFDBA), with a mean change of 2.09 mm. In a prospective study, Froum et al. [11] evaluated the stability of the volume of the augmented bone over 2 to 3 years in 13 sinuses grafted with inorganic bovine bone mineral (Osteograft/N®, Ceramed®). While the authors reported minimal changes (1.4%) in graft height in sites grafted with OsteoGraft/N®, in two other cases where the sinuses were grafted with DFDBA the radiographic follow-up demonstrated 15.5% and 16.5% loss in graft height, respectively. On the other hand, Hatano et al. [12] performed a long-term radiographic evaluation of graft height changes for up to 10 years. Maxillary sinuses were augmented with a 2: 1 autogenous bone/xenograft mixture along with simultaneous placement of dental implants. After augmentation, the grafted sinus floor was consistently located above the implant apex. However, the sinus graft height decreased significantly in time and approached the original sinus floor. After 2 to 3 years, the grafted sinus floor was at the same level of or

slightly below the implant apex. These differences in results have been mainly attributed to the use of different grafting materials.

In the study of Bragger et al. [13], sinuses were grafted with a combination of Bio-Oss® and autogenous bone using the osteotome technique. The apical portion of the graft showed a statistically significant loss of more than 50 % of its initial height, dropping from a mean of 1.52 mm at baseline to 0.29 mm at 12 months at mesial aspects. Similar values were reported at the distal aspects.

Space maintenance has been reported to influence the amount of newly formed bone during regeneration. In this regard, one of the drawbacks of using autogenous bone is its fast resorption. It would be advantageous to use a material which resists the air pressure encountered within the sinus, promotes bone formation, and persists for a long period of time. Deproteinized bovine bone has been reported to be biocompatible, osteoconductive, and more importantly to have a very slow resorption rate which grants it long-lasting and space-maintaining characteristics [23, 24]. Still, the apical portion of the graft in the present study did lose around 27.4 % of its initial height at the end of the 12 months observation period which was found to be statistically significant. However, the new sinus floor was still located above the implant apex in all of the evaluated cases, confirming the ability of this material to support the elevated membrane and, hence, reduce the loss in the initially gained height.

In conclusion, within the limitations of this retrospective study it was found that the use of deproteinized bovine bone alone along with the osteotome technique for sinus floor elevation and simultaneous implant placement could not prevent changes in the initially gained intra-sinus graft height. However, the reported results show its benefit in limiting the loss of the augmented height to a minimum.

## References

1. Smiler DG, Johnson PW, Lozada JL, Misch C, Rosenlicht JL, Tatum OH, Wagner JR. Sinus lift grafts and endosseous implants. *Dent Clin North Am* 1986;30: 207-229.
2. Boyne PJ, James RA. Grafting of the maxillary sinus floor with autogenous marrow and bone. *J Oral Surg* 1980;38:613-616.
3. Tatum H. Maxillary and sinus implant reconstructions. *Dent Clin North Am* 1986;30:207-229.
4. Summers RB. The osteotome technique; Part 3. Less invasive methods of elevating the sinus floor. *Compend Contin Educ Dent* 1994;15(6):698-708.
5. Ferrigno N, Laureti M, Fanali S. Dental implants placement in conjunction with osteotome sinus floor elevation: A 12-year life-table analysis from a prospective study on 588 ITI implants. *Clin Oral Impl Res* 2006;17:194-205.
6. Deporter D, Todescan R, Caudry S. Simplifying management of the posterior maxilla using short, porous-surfaced dental implants and simultaneous indirect sinus elevation. *Int J Periodontics Restorative Dent* 2000;20:477-485.
7. Fugazzotto P. Immediate implant placement following a modified trephine/osteotome approach: Success rates of 116 Implants to 4 years in function. *Int J Oral Maxillofac Implants* 2002;17:113-120.
8. Cavicchia F, Bravi F, Petrelli G. Localized augmentation of the maxillary sinus floor through a coronal approach for the placement of implants. *Int J Periodontics Restorative Dent* 2001;21:475-485.
9. Hürzeler MB, Kirsch A, Ackermann KL, Quinones CR. Reconstruction of the severely resorbed maxilla with dental implants in the augmented maxillary sinus: a 5-year clinical investigation. *Int J Oral Maxillofac Implants* 1996;11: 466-475.
10. Jensen OT, Shulman LB, Block MS & Iacone VJ. Report of the sinus consensus conference of 1996. *Int J Oral Maxillofac Implants* 1998;13 (Special Suppl): 11- 32.
11. Froum SJ, Tarnow DP, Wallace SS, Rohrer MD, Cho SC. Sinus floor elevation using anorganic bovine bone matrix (OsteoGraf/N) with and without autogenous bone: A clinical, histologic, radiographic, and histomorphometric analysis-Part 2 of an ongoing prospective study. *Int J Periodontics Restorative Dent* 1998;18:529-543.
12. Hatano N, Shimizu Y, Ooya K. A clinical long-term radiographic evaluation of graft height changes after maxillary sinus floor augmentation with a 2:1 autogenous bone/xenograft mixture and simultaneous placement of dental implants. *Clin Oral Impl Res* 2004;15: 339-345.
13. Brägger U, Gerber C, Joss A, Haenni S, Meier A, Hashorva E, Lang NP. Patterns of tissue remodeling after placement of ITI dental implants using an osteotome technique: a longitudinal radiographic case cohort study. *Clin Oral Impl Res* 2004;15: 158-166.
14. Wetzel AC, Stich H & Caffesse RG. Bone apposition onto oral implants in the sinus area filled with different grafting materials. A histological study in beagle dogs. *Clin Oral Impl Res* 1995;6:155-163.
15. Hämmerle CH, Olah AJ, Schmid J, Flückiger L, Gogolewski S, Winkler JR & Lang NP. The biological effect of natural bone mineral on bone formation on the rabbit skull. *Clin Oral Impl Res* 1997;8: 198-207.
16. Albrektsson T, Zarb G, Worthington P, Eriksson AR. The long-term efficacy of currently used dental implants: A review and proposed criteria of success. *Int J Oral Maxillofac Implants* 1986;1:11-25.
17. Davarpanah M, Martinez H, Tecucianu JF, Hage G, Lazzara R. The modified osteotome technique. *Int J Periodontics Restorative Dent* 2001;21:599-607.
18. Rosen PS, Summers R, Mellado JR et al. The bone added osteotome sinus floor elevation technique: Multicenter retrospective report of consecutively treated patients. *Int J Oral Maxillofac Implants* 1999;14:853-858.
19. Toffler M. Osteotome-mediated sinus floor elevation: A clinical report. *Int J Oral Maxillofac Implants* 2004;19:266-273.
20. Reiser GM, Rabinovitz Z, Bruno J, Damoulis PD, Griffin TJ. Evaluation of maxillary sinus membrane response following elevation with the crestal osteotome technique in human cadavers. *Int J Oral Maxillofac Implants* 2001;16:833-840.
21. Fanuscu MI, Iida K, Caputo AA, Nishimura RD. Load transfer by an implant in a sinus-grafted maxillary model. *Int J Oral Maxillofac Implants* 2003;18:667-674.
22. Tepper G, Haas R, Zechner W, Krach W, Watzek G. Three-dimensional finite element analysis of implant stability in the atrophic posterior maxilla. *Clin Oral Impl Res* 2002;13:657-665.
23. Xu H, Shimizu Y, Asai S, Ooya K. Grafting of deproteinized bone particles inhibits bone resorption after maxillary sinus floor elevation. *Clin Oral Impl Res* 2004;15:126-133.
24. Yildirim M, Spiekermann H, Biesterfeld S & Edelhoff D. Maxillary sinus augmentation using xenogenic bone substitute material Bio-Oss® in combination with venous blood: A histologic and histomorphometric study in humans. *Clin Oral Impl Res* 2000;11: 217-229.