

CONCOMITANT OCCURRENCE OF NEUROFIBROMATOSIS TYPE I AND LOBULAR CAPILLARY HEMANGIOMA IN THE ORAL CAVITY: A CASE REPORT

Rakhi Issrani*

Abstract

Neurofibromatosis type I is one of the most common autosomal dominant inherited disorders associated with deletion, insertion, or mutation in the NF-1 gene. Neurofibromas are the hallmark of the neurofibromatosis type I and usually appear during childhood or adolescence after the emergence of "café au lait" spots. Despite their occurrence in the head and neck region, neural sheath tumors are rarely seen in the oral cavity.

Lobular capillary hemangioma is a histologic variant of pyogenic granuloma which is a common benign vascular lesion of the skin and mucosa. It is neither infective / purulent nor granulomatous as the name might suggest - rather a reactive enlargement that is an inflammatory response to local irritation.

In the present study, we report a rare case of concomitant occurrence of neurofibromatosis type I and lobular capillary hemangioma in a fifteen-year-old Indian female who presented with a gingival overgrowth in her maxillary anterior region. The lesion was excised and histopathological report confirmed the diagnosis. To the best of our knowledge this is the first case in english literature where there was a parallel occurrence of neurofibromatosis type I and lobular capillary hemangioma in the oral cavity.

Keywords: Neurofibromatosis type I – von Recklinghausen’s disease – lobular capillary hemangioma – pyogenic granuloma. IAJD 2013;4(3):119-125.

OCCURRENCE CONCOMITANTE DE NEUROFIBROMATOSE DE TYPE I ET D'HÉMANGIOME CAPILLAIRE LOBULAIRE AU NIVEAU DE LA CAVITÉ BUCCALE : A PROPOS D'UN CAS

Résumé

La neurofibromatose de type I est l'un des troubles autosomiques dominants héréditaires les plus courants, associé à la suppression, insertion ou mutation dans le gène NF- 1.

Les neurofibromes caractérisent la neurofibromatose de type I ; ils apparaissent généralement pendant l'enfance ou l'adolescence après la survenue des tâches « café au lait». Malgré leur occurrence dans la région de la tête et du cou, les tumeurs des gaines nerveuses sont rarement observées dans la cavité buccale.

L'hémangiome capillaire lobulaire est une variante histologique des granulomes pyogènes. C'est une lésion vasculaire bénigne de la peau et des muqueuses. Il n'est ni infectieux / purulent ni granulomateux comme son nom l'indique - plutôt un élargissement qui est une réponse inflammatoire à une irritation locale.

Dans la présente étude, nous rapportons un cas rare de neurofibromatose de type I et d'hémangiome capillaire lobulaire chez une fille de 15 ans qui s'est présentée avec une hypertrophie gingivale au niveau de la région maxillaire antérieure. La lésion a été excisée et le rapport histo-pathologique a confirmé le diagnostic.

Mots-clés: neurofibromatose de type I – maladie de Von Recklinghausen – hémangiome capillaire lobulaire – granulome pyogène.

IAJD 2013;4(3):119-125.

* Ass. Prof.
Oral Medicine, India
dr.rakhi.issrani00@gmail.com

Introduction

The term “neurofibromatosis” refers to a group of genetic disorders that primarily affect the cell growth of neural tissues [1]. Neurofibromatosis is now recognized to consist of two distinct variants that differ from each other genetically, microscopically, and clinically.

Neurofibromatosis type I (NF-I) is an autosomal dominantly inherited disease, associated with the mutation of NF-1 gene, a tumor suppressor gene located on chromosome 17q11.2. It is a common neurocristopathy, with an estimated incidence of 1 in 3,000 live births; almost 50% of NF-I patients have family history of the disease.

Neurofibromatosis type II (NF-II) is a much more uncommon manifestation that probably results from a structural defect in chromosome 22 [2]. The frequency of oral manifestations is debated in the literature. Some authors report a frequency of 4-7% of cases [2], whereas others suggest that these manifestations are present in up to 72% of cases [3].

The neurofibroma associated with NF-I usually runs an indolent course but sometimes can undergo malignant transformation and in such cases can be fatal [1].

Pyogenic granuloma (PG) is a common inflammatory tumor-like growth seen in the oral cavity as a mucosal reaction response to irritation, trauma or hormonal imbalances and is considered to be non-neoplastic in nature [4]. The peak prevalence is in teenagers and young adults, with a female predilection. In the oral cavity, PGs commonly occur on the gingiva owing to the presence of chronic irritation by the calculus or foreign material in the gingival sulcus [5]. Clinically these lesions usually present as single nodule or sessile papule with smooth or lobulated surface and are red, elevated and usually ulcerated. They may also develop rapidly, reach full size and then remain static for a time and later become fibrotic [6].

Histologically, PGs are of two types namely lobular capillary hemangioma (LCH) and non lobular capillary hemangioma (non-LCH). Surgical excision is the most common treatment of these lesions [7].

In the present study, we report a rare case of concomitant occurrence of NF-I and LCH in a fifteen-year-old Indian female who presented with a gingival overgrowth in her maxillary anterior region. To the best of our knowledge this is the first case in English literature where there was a parallel occurrence of NF-I and LCH in the oral cavity.

Case Report

A fifteen-year-old Indian female patient presented with a complaint of a slowly growing painless mass in the upper front region of the jaw since six months.

Clinical history and physical examination findings

The patient was suffering from excessive gingival bleeding during meals for the last six months, accompanied by gingival enlargement in the maxillary anterior region. A short time after the bleeding has started, she discovered, in the same region, a reddish mass that has been increasing in size gradually. Patient gave a history of disturbed mastication and phonation in the last five months; she was suffering from fever during the last 8 days.

On general examination, the patient was poorly built and nourished. No pallor, icterus, cyanosis, clubbing, pedal edema or lymphadenopathy was noticed.

The physical examination revealed flat nose and frontal bossing (Fig. 1). Multiple cutaneous nodules and “*café au lait*” pigmentations of varying sizes were seen distributed on the entire body, extensively involving the neck, chest and back regions; they were present since childhood (Figs. 2a and 2b). A diffuse reddish macular lesion was present on the left arm extending from shoulder to the palm (Fig. 3). The fam-

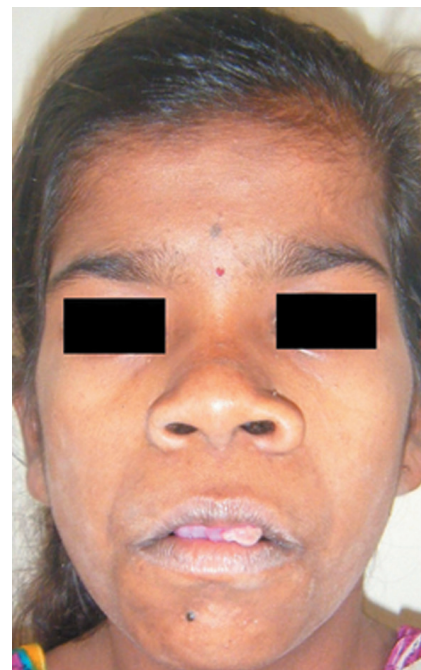

Fig. 1: Extra-oral photograph of the patient revealing flat nose and frontal bossing.

ily history revealed that her father, sister and brother had similar nodules on their bodies.

On comprehensive intraoral examination, a solitary exophytic, non-ulcerated mass measuring approximately 5 × 4 cm in size was observed on the maxillary anterior region, attached to the marginal gingiva, interproximally between the maxillary central incisors and covering their entire crowns. The lesion presented as a lobulated mass extending buccally into the buccal vestibule and palatally till the rugae region (Fig. 4). The growth was sessile, irregular in shape with a smooth surface and normal in color except at the marginal gingiva in relation to the maxillary left central incisor where it appeared erythematous. No surface ulceration or secondary infection was noted. Another sessile irregular mass, measuring about 1 × 0.5 cm was present interdentially in relation to the maxillary right premolars on the palatal gingival surface (Fig. 5).

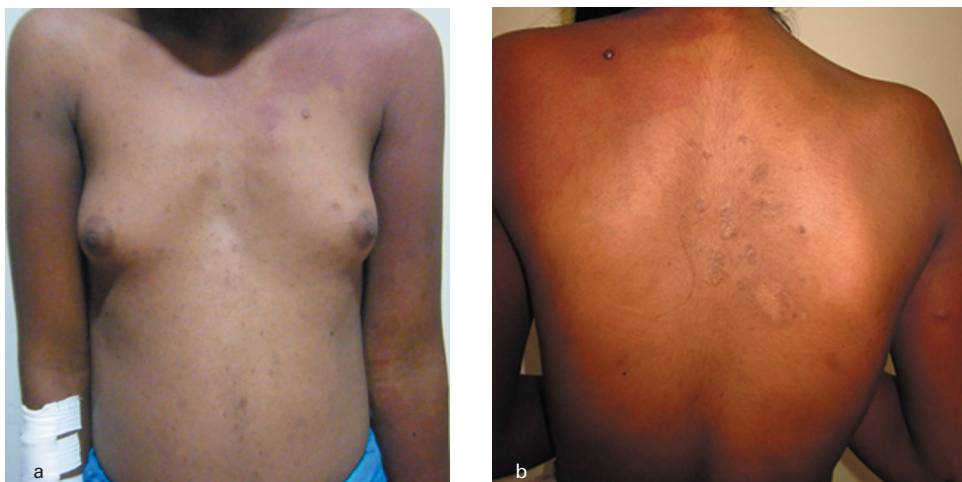

Fig. 2a and 2b: Multiple cutaneous nodules and "café au lait" pigmentations seen on the entire body, extensively involving the neck, chest and back regions.

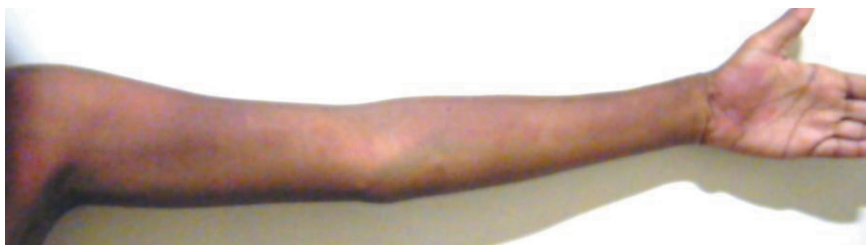

Fig. 3: A diffuse reddish macular lesion was present on the left arm extending from shoulder to the palm.

On palpation, the two masses were soft and oedematous, tender with profuse bleeding on provocation.

Based on the history and clinical examination, a provisional diagnosis of pyogenic granuloma was given. The other pathologic entities included in the differential diagnosis were soft tissue fibroma and peripheral giant cell granuloma.

Among other dental findings, we observed a supernumerary tooth in relation to teeth #12 and 13, bilateral peg laterals, moderate supragingival calculus, bleeding on probing and localized gingival enlargement in mandibular anterior region.

Complete blood examination and urine analysis were advised. The laboratory investigations of blood and urine were within normal limits; this permitted us to rule out any leukemic enlargement, diabetes mellitus and hyperparathyroidism.

The patient was referred for dermatological and ophthalmological opin-

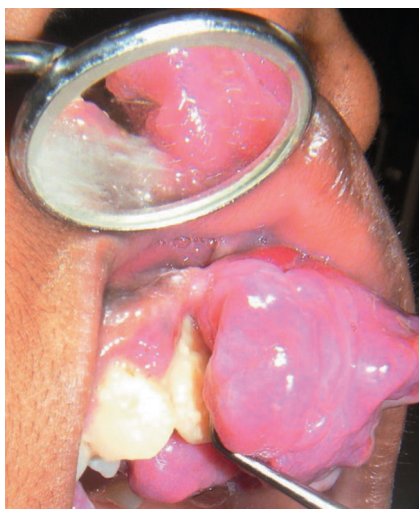

Fig. 4: Preoperative intraoral view showing a sessile and lobulated mass extending into the buccal vestibule and the palate covering almost the entire coronal part of the maxillary incisors.

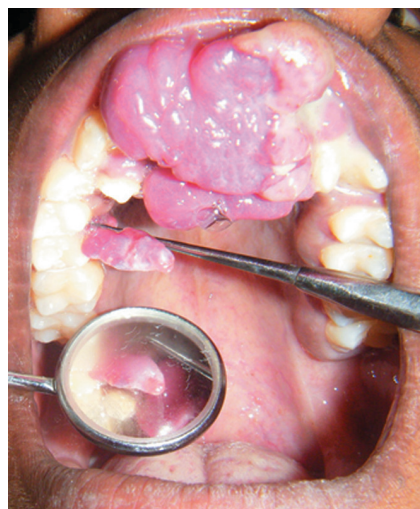


Fig. 5: A sessile irregular mass present interdentally in relation to maxillary right premolars.

ions. Lisch nodules were noted on eye examination by the ophthalmologist.

The patient underwent radiographic examination that included a maxillary occlusal and a panoramic radiograph.

Radiographic findings

The maxillary occlusal radiograph revealed a soft tissue shadow in the maxillary anterior region covering almost the entire coronal part of the maxillary central incisors (Fig. 6). Diastema in the same region could also be appreciated. The panoramic radiograph revealed widening of mandibular canals, enlarged mental foramen, deepening of sigmoid notch and shortening of ramus suggestive of neurofibromatosis (Fig. 7).

Surgical findings

The patient underwent surgical removal of the mass under local anaesthesia; the gingival specimen was sent for histopathological examination. The healing was uneventful (Fig. 8).

Histologic findings

The histopathologic examination revealed stroma comprised of numerous budding blood vessels and endothelial lined blood vessels of varying sizes which appeared to be interconnected. The endothelial cells were round to oval with few showing hyperchromasia and few showed vesicular nuclei. The stroma comprised of loose to dense bundles of collagen fibres with plump to spindle shaped fibroblasts and fibrosis. Patchy distributions of dense inflammatory infiltrate were seen, predominantly consisted of lymphocytes and plasma cells along with neutrophils. Areas of dystrophic calcification were also noted (Fig. 9). Histopathological features were suggestive of lobular capillary hemangioma.

Discussion

Neurofibromatosis is a disorder that includes two distinct variants which differ from each other geneti-

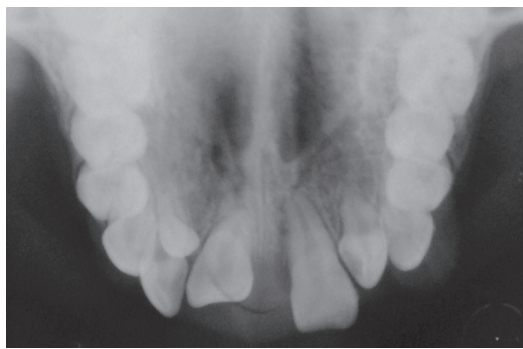


Fig. 6: Maxillary occlusal radiograph revealing a soft tissue shadow in the maxillary anterior region covering almost the entire crowns of the maxillary central incisors.

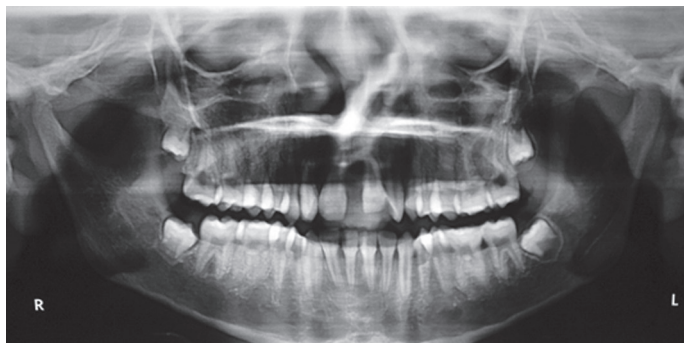

Fig. 7: Panoramic radiograph revealing widening of mandibular canals, enlarged mental foramen, deepening of sigmoid notch and shortening of ramus on the right side.

cally, histologically and clinically and have been designated as NF-I and NF-II. NF-I, often known as von Recklinghausen's disease (VRD) is one of the most common autosomal dominant inherited disorders associated with deletion, insertion, or mutation in the NF-I gene, a tumor suppressor gene located on chromosome 17q11.2 with an incidence of 1 in 3,000.

NF-II, also known as central neurofibromatosis, accounts for an extremely small percentage of the total cases of neurofibromatosis [2]. Despite the advances of molecular biology, the diagnoses of NF-I and NF-II are still based on clinical criteria. The National Institutes of Health

Consensus Development Conference has suggested clinical criteria diagnosis of NF-I and NF-II [8].

Diagnosis of NF-I:

1. Six or more "café au lait" macules with the greatest diameter over 5 mm in pre-pubertal individuals and over 15 mm in greatest diameter in post-pubertal individuals.
2. Two or more neurofibromas of any type or one plexiform neurofibroma.
3. Freckling in the axillary or inguinal regions (Crowe's sign).
4. Optic gliomas.
5. Two or more Lisch nodules (iris hamartomas).

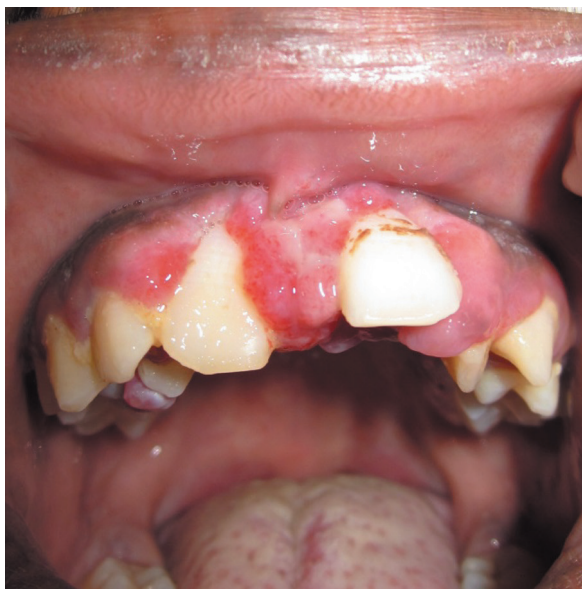

Fig. 8: Treatment outcome after excising the lesion.

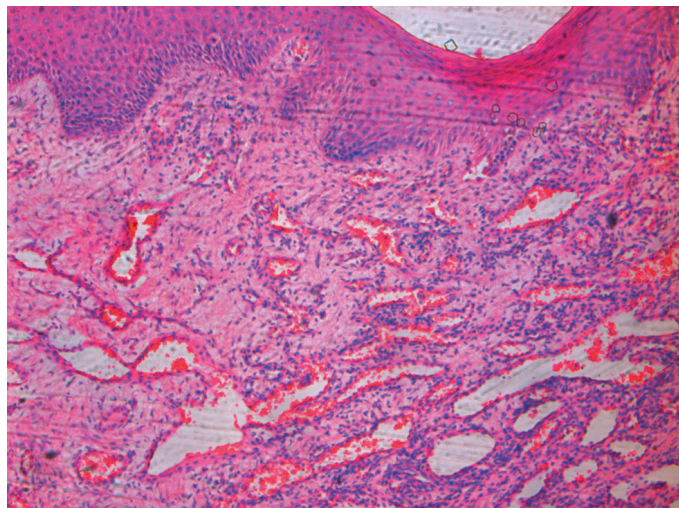


Fig. 9: A histologic slide showing the characteristic features of lobular capillary hemangioma.

6. A distinctive osseous lesion such as sphenoid dysplasia or thinning of long bone cortex with or without pseudoarthrosis.
7. A first-degree relative (parent, sibling, or offspring) with NF-I diagnosis.

All these manifestations may not be present; the diagnosis is established if the patient has two or more of the above-mentioned features.

Diagnosis of NF-II:

1. Bilateral masses of the eighth cranial nerve seen with appropriate imaging techniques (e.g., CT or MRI)
2. One relative in first-degree with NF- II and either:
 - a) Unilateral mass of the eighth cranial nerve, or
 - b) Two of the followings:

- Neurofibroma.
- Meningioma.
- Glioma.
- Schwannoma.
- Juvenile posterior subcapsular lenticular opacity.

The criteria are met by an individual who satisfies condition 1 or 2.

Neurofibromas are the hallmark of the NF-I and usually appear during childhood or adolescence after the emergence of “café au lait” spots. Our patient had multiple neurofibromas of the skin and “café au lait” spots. Neurofibromas occur either as sporadic solitary nodules unrelated to any apparent syndrome or as solitary, multiple or numerous lesions in individuals with NF-I.

Neurofibroma presents most commonly as a cutaneous nodule (localized cutaneous neurofibroma) and less often as a circumscribed mass in a peripheral nerve (localized intraneural neurofibroma) or as a plexiform enlargement of a plexus or major nerve trunk. All ages and both sexes are affected in NF-I [2]. The present case is reported in a fifteen-year-old Indian female.

Despite their occurrence in the head and neck region, neural sheath tumors are rarely seen in the oral cavity

with only 4% to 7% of patients affected by neurofibromatosis displaying oral manifestations.

Oral localized neurofibromas present as discrete nodules of normal color. Oral radiographic findings unique to NF include lengthening, narrowing and rarefaction of coronoid and articular process, deepening of sigmoid notch, enlarged mandibular canal, mandibular foramen and mental foramen. Other findings are shortening of the ramus, notching of the inferior border of the mandible and even asymmetrically developed maxillary sinus [2]. In our case, widening of the mandibular canal, an enlarged mental foramen, deepening of the sigmoid notch and shortening of the ramus were present.

The partial or total surgical removal of tumors can be performed to solve aesthetic and functional problems, but it is preferable to wait till the end of growth to reduce the risk of re-occurrence. To date there is no indication that surgery favours malignant degeneration. NF-I may be considered as a familial cancer predisposition syn-

drome and the patients with NF-I need to be assessed periodically to rule out any malignant change [9]. Fortunately, there were no signs of recurrence or other manifestations of NF-I during the one year follow-up period of our patient.

The most common vascular proliferation of the oral mucosa is the PG. The first case was reported by Hüllihen (1844) [10] and the term “pyogenic granuloma” or “granuloma pyogenicum” was coined by Hartzell (1904) [11]. It is a reactive tumor-like growth of the oral cavity or skin that is considered to be non-neoplastic in nature, resulted from reaction of tissue growth in response to various stimuli such as low grade chronic irritation, trauma, hormonal imbalances or iatrogenic stimulations in dental practice like guided tissue regeneration [4, 12].

Gingival irritation and inflammation that result from poor oral hygiene, dental plaque and calculus, over-hanging restorations, trauma to a primary tooth or aberrant tooth development may be the precipitating factors in many cases especially for extraggingival PGs [13]. It is possible that micro-ulceration caused by these irritants allows the ingress into the gingival connective tissue of low virulent oral microflora.

In the oral cavity pyogenic granulomas show a striking predilection for the gingiva and the interdental papillae, especially in the maxillary anterior region, the facial aspect being the most common site as in our case; less commonly it can occur on the lips, tongue, buccal mucosa, palate [14]. Clinically the lesion is elevated, pedunculated or sessile, with smooth surface, sometimes lobulated and warty surface which is usually hemorrhagic and compressible as in the present case. It may develop as dumb-bell-shaped masses which can commonly show ulcerations covered with yellow fibrinous membrane [12]. The size of the lesion usually ranges between 0.5-2cm and they may grow at an alarming rate reaching that size in just 4-7 days [15]. The colour ranges from deep red, reddish purple to pink depending on its dura-

tion and vascularity of the lesion. The lesion is painless and soft in consistency; although older lesions tend to become more collagenized and firm. Differential diagnosis of PG includes parulis, peripheral giant cell granuloma, peripheral ossifying fibroma, hemangioma, peripheral fibroma, leiomyoma, hemangioendothelioma, hemangiopericytoma, bacillary angiomatosis, Kaposi's sarcoma, metastatic tumor, post extraction granuloma and pregnancy tumor [12].

Depending on its rate of proliferation and vascularity, there are 2 histological variants of pyogenic granuloma called LCH and non-LCH. Clinically, LCH PG occurs more frequently (66.4%) as sessile lesion whereas non-LCH PG occurs as pedunculated (77%). LCH usually presents as a spontaneous, painless, bleeding mass. The lobular area of the LCH PG contained a greater number of blood vessels with small luminal diameter than did the central area of non-LCH PG. In the central area of non-LCH PG a significantly greater number of vessels with perivascular mesenchymal cells non-reactive for alpha-smooth muscle actin and muscle-specific actin was present than in the lobular area of LCH PG [7].

Although PG can be diagnosed clinically with considerable accuracy, radiographic and histopathological investigations help confirming the diagnosis. Radiographs are advised to rule out bony destructions suggestive of malignancy or to identify a foreign body [13].

The treatment of pyogenic granuloma depends on the severity of the symptoms in the lesion. If it is small, painless and free of bleeding, clinical observation and follow-up are advised. If the lesions are huge, surgical excision and removal of causative irritants are among the treatment choice. There is relatively high rate of recurrence (about 15%) after simple excision. Other conventional surgical modalities for the treatment of pyogenic granuloma reported are cryosurgery in the form of either liquid nitrogen spray or a cryoprobe. Nd: YAG, CO₂ and flash

lamp pulsed dye lasers have also been used for the treatment of oral pyogenic granuloma [12, 13, 16].

Conclusion

Occasionally, oral manifestations may provide the opportunity to diagnose NF. A thorough examination and trained eye will provide the opportunity to diagnose NF. Therefore, the oral diagnostician should be made aware of the oral manifestations of the NF which will help in timely diagnosis and treatment of this disorder.

Although PG is a non-neoplastic lesion of the oral cavity, it is important to the dentist because of its associated gingival vascular features and complications in the form of impaired nutrition and oral hygiene, increased accumulation of plaque and microorganisms and increased susceptibility to oral infections, which can affect the systemic health of the individual. Good oral hygiene, maintenance and regular follow-up can prevent recurrence of such lesions.

References

1. Mahija Janardhanan, S Rakesh, RB Vinod Kumar. Intraoral presentation of multiple malignant peripheral nerve sheath tumors associated with neurofibromatosis-1. *J Oral Maxillofac Pathol.* 2011 Jan-Apr;15(1):46-51.
2. Geist JR, Gander DL, Stefanac SJ. Oral manifestations of neurofibromatosis types I and II. *Oral Surg Oral Med Oral Pathol* 1992 Mar;73(3):376-82.
3. Shapiro SD, Abramovitch K, Van Dis ML, Skoczylas LJ, Langlais RP, Jorgenson RJ, et al. Neurofibromatosis: Oral and radiographic manifestations. *Oral Surg Oral Med Oral Pathol* 1984;58:493-98.
4. Greenberg MS, Glick M (2003) *Burkett's Oral Medicine: Diagnosis and Treatment.* (10th ed), BC Decker, Hamilton, Canada.
5. Akyol MU, Yalciner EG, Dogan AI. Pyogenic granuloma (lobular capillary hemangioma) of the tongue. *Int J Pediatr Otorhinolaryngol* 2001;58(3):239-41.
6. Muench MG, Layton S, Wright JM. Pyogenic granuloma associated with a natal tooth: case report. *Pediatr Dent* 1992;14:265-67.
7. Epivatianos A, Antoniadis D, Zaraboukas T, Zairi E, Pouloupoulos A, et al. Pyogenic granuloma of the oral cavity: comparative study of its clinicopathological and immunohistochemical features. *Pathol Int* 2005;55:391-7.
8. Gutmann DH, Aylsworth A, Carey JC, Korf B, Marks J, Pyeritz RE et al. The diagnostic evaluation and multidisciplinary management of neurofibromatosis 1 and neurofibromatosis 2. *JAMA* 1997;278:51-57.
9. Mubeen Khan1, Neera Ohri. Oral manifestations of type I neurofibromatosis in a family. *J Clin Exp Dent* 2011;3(5):e483-6.
10. Hullihen SP. Case of aneurysm by anastomosis of the superior maxilla. *Am J Dent Sc* 1844;4: 160-62.
11. Hartzell ME. Granuloma Pyogenicum. *J Cutan Dis Symp* 1904;22:520-25.
12. Jafarzadeh H, Sanatkhan M, Mohtasham N. Oral pyogenic granuloma: A review. *J Oral Sc* 2006;48(4):167-175.
13. Amirchaghmaghi M, Falaki F, Mohtasham N, Mozafari PM. Extralingival pyogenic granuloma: a case report. *Cases J* 2008;1:371.
14. Ramirez K, Bruce G, Carpenter W. Pyogenic granuloma: case report in a 9-year-old girl. *Gen Dent* 2002;50:280-81.
15. Vilmann A, Vilmann P, Vilmann H. Pyogenic granuloma: evaluation of oral conditions. *Br J Oral Maxillofac Surg.* Oct 1986;24(5):376-82.
16. Sills ES, Zegarelli DJ, Hoschander MM, Strider WE. Clinical diagnosis and management of hormonally responsive oral pregnancy tumor (pyogenic granuloma). *J Reprod Med* 1996;41:467-70.