

PREVALENCE OF HYPODONTIA IN PERMANENT DENTITION IN A SAMPLE OF SUDANESE UNIVERSITY STUDENTS

Amal Abu Affan* | Abeer Serour**

Abstract

The congenital absence of one or more permanent teeth is a common dental anomaly. It can seriously affect a young person, both physically and emotionally, particularly when the missing tooth is located in the anterior region of the maxillary dental arch.

The aim of the present descriptive cross-sectional study was to evaluate the prevalence of hypodontia of the permanent dentition and to determine the most common congenitally missing permanent teeth in a sample of 2401 Sudanese university students.

A total of 100 congenitally missing teeth were observed in 64 students (7 males and 57 females); the overall prevalence of hypodontia in permanent dentition was 2.66% (2.69% in males, 2.66% in females). Hypodontia was more prevalent in the mandible (61%) than in the maxilla (39%) and in the left side of the jaws (55%) than in the right side (45%). The most common congenitally missing permanent tooth was the mandibular lateral incisor (23%), followed by the maxillary lateral incisor (19%), the mandibular 2nd premolar (18%) and the maxillary 2nd premolar (17%).

The present study results give a clue of the magnitude of the problem. However, strong conclusion cannot be drawn since the sample studied is not representative to the whole Sudanese community. Further studies are required with a large sample collected from the different provinces of the Sudan.

Keywords: Hypodontia – congenitally missing tooth – permanent dentition.

PRÉVALENCE DE L'HYPODONTIE EN DENTITION PERMANENTE DANS UN ÉCHANTILLON D'ÉTUDIANTS UNIVERSITAIRES SOUDANAIS

Résumé

L'absence congénitale d'une ou de plusieurs dents permanentes est une anomalie dentaire commune. Elle peut gravement affecter un adolescent, à la fois esthétiquement et émotionnellement, en particulier lorsqu'il s'agit d'une dent antérieure.

Le but de cette étude descriptive transversale était d'évaluer la prévalence de l'hypodontie de la dentition permanente dans un échantillon de 2401 étudiants soudanais et de déterminer les dents les plus incriminées.

Un total de 100 dents congénitalement absentes a été observé chez 64 étudiants (57 femmes et 7 hommes). La prévalence globale de l'hypodontie de la dentition permanente était de 2,66 % (2,69% chez les hommes et 2,66% chez les femmes).

L'hypodontie était plus fréquente à la mandibule (61 %) et dans la partie gauche de la mâchoire (55%). L'incisive mandibulaire latérale (23%) était la dent la plus fréquemment absente, suivie par l'incisive latérale maxillaire (19%), la 2ème prémolaire inférieure (18%) et la 2ème prémolaire maxillaire (17%).

Les résultats de la présente étude donnent une idée de la fréquence de cette anomalie. Cependant, une conclusion ne peut être tirée puisque l'échantillon étudié n'est pas représentatif de l'ensemble de la communauté soudanaise. Des études épidémiologiques avec des échantillons plus larges menées dans les différentes provinces du Soudan sont nécessaires; elles permettront une meilleure appréciation de cette anomalie.

Mots- clés: hypodontie - absence congénitale de dent – dentition permanente.

* Associate Professor
Head Dept of Orthodontic,
Pedodontic and Preventive
dentistry,
University of Khartoum, Sudan
amalabuaffan@yahoo.com

** BDS, MSc in Orthodontics,
Head Dept of Orthodontic clinic,
Military Dental Hospital, Khartoum,
Sudan

Introduction

Congenitally missing teeth is the most common developmental dental anomalies in humans [1]. Many terms were used to describe this phenomenon: oligodontia, anodontia, aplasia of teeth, absence of teeth, agenesis of teeth and lack of teeth; however, hypodontia is the most frequently used. The term hypodontia is used when one to six teeth (excluding the third molars) are missing; oligodontia refers to the situation when more than six teeth (excluding the third molars) are missing. Anodontia denotes the complete absence of teeth. Anodontia and oligodontia are rarely used [2, 3].

Hypodontia can occur in an isolated mode, caused by local factors that can disrupt the normal development of the permanent dentition. These factors include early irradiation of the tooth germ, hormonal and metabolic influences, trauma, and osteomyelitis. Hypodontia can also occur as a symptom of more generalized systemic conditions such as ectodermal dysplasia, cleft lip and palate, Down syndrome, ...[3]. Although tooth agenesis is caused by environmental factors in the majority of cases, hypodontia has a genetic basis. A familial hypodontia is an autosomal dominant inheritance with incomplete penetrance and variable expressivity. An autosomal recessive mode of inheritance is also possible [4-5].

In general, if one or few teeth are missing, the absent tooth will be the most distal tooth of any given type, i.e., lateral incisors, second premolars and third molars. Whereas congenitally missing canine is an unusual condition [2].

The prevalence of hypodontia in the permanent dentition ranged between 4 to 11.3% depending on the investigated populations and the samples 'size [6-24]. It was found to be more frequent among females than males [11-14].

The most commonly missing teeth were the mandibular second premolars [6, 8, 18-21, 23, 24] and the maxillary

lateral incisors [9, 11, 12, 14, 17]. The missing teeth were more often absent on the maxillary arch than on the mandibular arch [9] and on the right side than on the left side within the dental arch [17].

The congenital absence of teeth can seriously affect a young person, both physically and emotionally particularly when the missing tooth is located in the anterior region of the mouth [1]. Early detection of hypodontia may allow a more favorable prognosis and minimal functional, esthetical and psychological complications [25].

The treatment options available for cases with congenitally missing teeth are the maintenance of the primary teeth, orthodontic space closure, space maintenance, restoration with adhesive or fixed denture, tooth transplantation, dental implant or orthodontics space redistribution to facilitate the prosthetic treatment [26].

Patients with congenitally missing teeth present a clinical challenge to the general dental practitioners and the orthodontists alike. Successful management of these patients necessitates a multidisciplinary approach (orthodontics, restorative dentistry, oral surgery) [27- 29].

No study has been yet conducted to assess the prevalence of hypodontia in Sudan. The aim of the present study was to create baseline information by evaluating the prevalence of hypodontia of the permanent dentition in a sample of a Sudanese's university students.

Materials and Methods

A descriptive cross-sectional study was carried out in the medical campus at the University of Khartoum, Sudan, during the period ranging from February 2012 to December 2012. Ethical approval was obtained from the research committee at the Faculty of Dentistry; written consent was obtained from each medical student participating in the study.

The students who are Sudanese and with no history of orthodontic treat-

ment, extractions or previous tooth loss caused by trauma or periodontal problem were selected according to a random stratified sampling technique with probability proportional to size.

The total number of students in the medical campus at the University of Khartoum was obtained from the students' affairs office. The initial screenings for the selected students were carried out in the day light. The permanent teeth were considered to be congenitally missing if they didn't erupt, were not radiographically assessed and were not previously extracted.

All students with missing permanent teeth or retained deciduous teeth were referred to the orthodontic department for further investigations: personal data and history, clinical examination and radiographic investigation.

Orthopantomograms or periapical x-rays were taken for every student by a well-trained technician at the Department of Radiology, Faculty of Dentistry, University of Khartoum, Sudan. The panoramic radiographs were taken using Cranex 3+ Cephalostat (Orion corporation sore-dex™) using extraoral films (Kodak MXG green sensitive). Students were positioned properly using the head-positioning devices and light beam marker positioning guides. The teeth were positioned to lie within the focal trough [30].

Statistical analysis

The statistical package for social sciences (SPSS) computer program -version 15- was used for statistical analysis; chi-square test was used for data analysis. The level of significance was at $p < 0.05$.

Results

2401 medical students (260 males and 2141 females) participated in the present study. Ninety-eight out of 2401 students had unerupted permanent teeth. Radiographic investigations

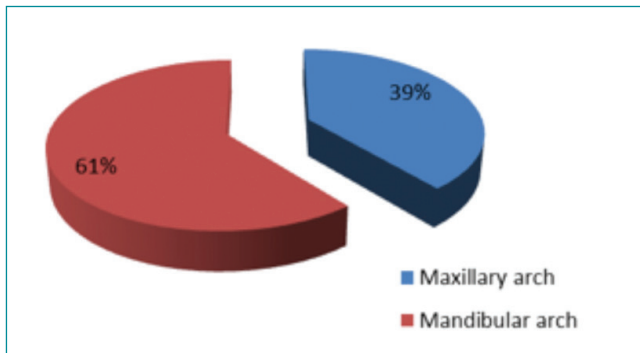


Fig. 1: Distribution of congenitally missing permanent teeth in the maxilla and mandible.

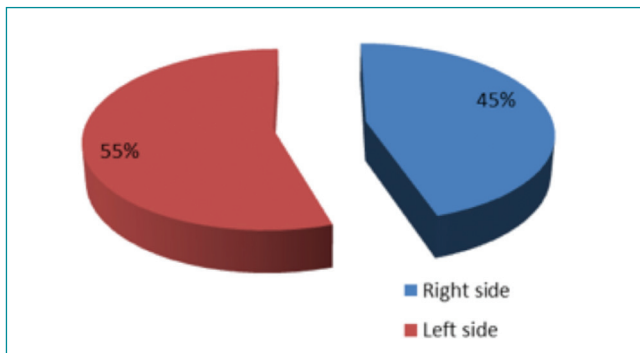


Fig. 2: Distribution of congenitally missing permanent teeth in the left and right sides.

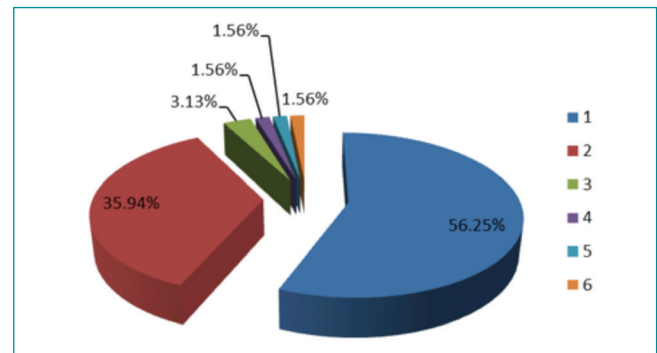


Fig. 3: Percentage of students with hypodontia.

Congenitally missing teeth	Maxillary arch			Mandibular arch		
	Females	Males	Total	Females	Males	Total
Right central incisor	0	0	0	4	1	5
Left central incisor	0	0	0	2	1	3
Right lateral incisor	10	0	10	7	1	8
Left lateral incisor	9	0	9	14	1	15
Left canine	0	0	0	1	0	1
Right 1st premolar	1	0	1	3	0	3
Left 1st premolar	2	0	2	7	0	7
Right 2nd premolar	8	1	9	6	3	9
Left 2nd premolar	8	0	8	5	4	9
Right 1st molar	0	0	0	0	1	1

Table1: Distribution of congenitally missing permanent teeth in the maxillary and mandibular arches.

Authors	Country	Sample size	Prevalence	Most common congenitally missing teeth
González-Allo et al. [6]	Portugal	2888	6.1%	Mandibular 2nd premolar
Mammon [7]	Jordan	3660	8.85%	
Young Ho [8]	Korea	3055 9-30yrs	11.3%	Mandibular 2nd premolar
Vahid-Dastjerdi et al. [9]	Iran	1751	9.1%	Maxillary lateral incisor
Tallón-Walton et al. [10]	Spain	1518	9.48%	
Celikoglu et al. [11]	Turkey	3341	4.6%	Maxillary lateral incisor
Gomes et al. [12]	Brazil	1049	6.3%	Maxillary lateral incisor
Al-Ajwadi [13]	Iraq	389		Upper lateral incisor Mandibular 2nd premolar
Sisman et al. [14]	Turkey	2413	7.54%	Maxillary lateral incisor
Albashaireh & Khader [15]	Jordan	1045	5.5%	Mandibular 2nd premolar
Goren et al. [16]	Israel	226	5.3%	Maxillary lateral incisor
Fekonja [17]	Slovenia	212	11.3%	Maxillary lateral incisor
Polder et al. [18] (Meta-analysis)	-Europe -Australia -North America		Males 4.6% 5.5% 3.2%	Females 6.3% 7.6% 4.0%
Goya et al. [19]	Japan	2072	9.4%	Mandibular 2nd premolar
Ng'ang'a et al. [20]	Kenya	615	6.3%	Mandibular 2nd premolar
Al-Emran [21]	Saudi Arabia	500	4%	Mandibular 2nd premolar
Davis [22]	China	1093	6.9%	Mandibular incisor
Rølling [23]	Denmark	3325	7.8%	Mandibular 2nd premolar
Magnússon [24]	Iceland	1116	6.7%	Mandibular 2nd premolar
Abu Affan & Serour	Sudan	2401	2.66%	Mandibular lateral incisor

Table 2: Prevalence of hypodontia of permanent dentition in previous studies.

were carried out for 85 students; four students dropped out from the study.

The results showed that 64 students (7 males, 57 females) out of 2401 had hypodontia (2.66%). 21 students (0.87%) had impacted permanent teeth. Male to female ratio with hypodontia was 1:8.3 although the incidence of hypodontia was found more or less the same in males (2.69%) and in females (2.66%). No statisti-

cally significant difference was noted between gender ($p > 0.05$).

A total of a one hundred congenitally missing teeth were found among the 64 students; 13 teeth in males and 87 teeth in females. Congenitally missing permanent teeth were more frequent in the mandible (61%) than in the maxilla (39%) (Fig.1). Moreover, hypodontia was more frequent in the left side (55%) than in the right side

(45%) of the maxillary and mandibular arches (Fig. 2).

The majority of the students had one congenitally missing permanent tooth (tooth #36) (56.25%), followed by two congenitally missing permanent teeth (tooth #23) (35.94%). Two students (3%) had three congenitally missing permanent teeth. More than three missing teeth were observed among three students (4.6%). When

the percentage of students with hypodontia was compared to the number of missing permanent teeth, a statistically significant difference was noted, indicating that hypodontia with one or two missing teeth is more common than multiple missing teeth ($p < 0.05$).

The most common congenitally missing permanent tooth was the mandibular lateral incisor (23%), followed by the maxillary lateral incisor (19%), the mandibular second premolar (18%) and the maxillary second premolar (17%) (Table 1).

The results in the present study showed that 74% of the second premolar hypodontia was associated with retention of the deciduous second molar. Also, 5% of retained deciduous incisors were correlated with the absence of their permanent counterpart. When the deciduous canine was retained, the permanent canine was often present and impacted.

Discussion

Although the percentage of dental anomalies has been reported in many countries, there has been no data published among Sudanese population about the prevalence of hypodontia in the permanent dentition. The present study aimed to determine the overall prevalence of hypodontia in a sample of Sudanese medical students at Khartoum University.

The prevalence of hypodontia ranged between 4% and 11.3% [6-24]. However, in the present study, the overall prevalence of hypodontia was found to be 2.66%. The observed discordance can be attributed to the genetic and racial differences as well as to the sample size of the examined group. In the literature, the lowest percentages of hypodontia were reported by Al-Emran [21] in a sample of 500 Saudis male children (4%) and by Celikoglu et al. [11] who examined Turkish orthodontic patients (4.6%).

A high prevalence of hypodontia was found in the mandibular arch compared to the maxillary arch; this was in contrast to the findings of Vahid-

Dastjerdi et al. [9] who obtained a higher prevalence of hypodontia in the maxillary arch among Iranian orthodontic patients.

The prevalence of hypodontia in the left side of the jaw was found to be more frequent than hypodontia in the right side in our study. However, Fekonja [17] reported a higher prevalence on the right side of the jaw among 212 orthodontically treated children. This variation may be attributed to the study sample size and the racial background.

No gender dimorphism in the prevalence of hypodontia was reported among different populations. Although there was a difference in the sample size between males and females in the present study, this prevalence wasn't statistically different. These findings coincide with those of previous studies [6, 7, 9, 12, 15]. However others [11, 13, 18, 19, 22, 23] recorded a high prevalence of hypodontia among females. On the other hand Ng'ang'a et al. reported that in Kenyan population hypodontia was more predominant among males than females [20].

In the present study, the percentage of congenitally missing one or two permanent teeth was reported among 90% of the Sudanese students (56% missing one single tooth and 34% missing two teeth). In Slovenia, comparative results (87.7%) were reported by Fekonja [17] among treated children sample. However, a higher prevalence for two-teeth hypodontia (58.5%) was observed compared to one-tooth hypodontia (29.2%).

None of the participants in the present study showed oligodontia. According to Celikoglu [11], the prevalence of oligodontia in Turkish population was 0.3% and 0.16% among Danish school students [23].

Previous published results revealed that the most common congenitally missing teeth were either the maxillary lateral incisor [12, 14, 16, 17], the mandibular second premolar [15, 19, 20, 23, 24] or the mandibular incisor [20]. In contrast, the present results showed that the most common

congenitally missing tooth was the mandibular lateral incisor, followed by the maxillary lateral incisor and the maxillary and mandibular second premolars. This difference can be related to ethnic and racial differences in the studied populations.

Conclusion

Although this study was carried out in a randomly selected sample of Sudanese university students, the results reflect the importance of the problem.

However, the sample size was small and not representative of the entire Sudanese population. That's why the obtained results cannot be generalized.

Additional studies including larger, representative samples specifying most tribes of Sudanese population are necessary to determine the overall prevalence of hypodontia of permanent dentition among Sudanese population.

References

1. Valle AL, Lorenzoni FC, Martins LM, Valle CVM, Henriques JFC, Almeida ALPF et al. A multidisciplinary approach for the management of hypodontia: Case report. *J Appl Oral Sci* 2011;19:544-48.
2. Proffit W. Fields H, Saver D. *Contemporary Orthodontics* 4th Edition St Louis; Mosby 2007;135-6,467-71.
3. Larmour C, Mossey P, Thind B, Forgie A, Stirrups D. Hypodontia: A retrospective review of prevalence and etiology. Part I. *Quintessence Int* 2005;36(4):263-70.
4. Ahmad W, Brancolini V, ul Faiyaz MF, Lam H, ul Haque S, Haider M, et al. A locus for autosomal recessive hypodontia with associated dental anomalies maps to chromosome 16q12.1. *Am J Hum Genet* 1998;62:987–91.
5. Pirinen S, Kentala A, Nieminen P, Varilo T, Thesleff I, Arte S. Recessively inherited lower incisor hypodontia. *J Med Genet* 2001;38:551–6.
6. González-Allo A, Campoy MD, Moreira J, et al. Tooth agenesis in a Portuguese population. *Int Orthod* 2012 Jun 10(2):198-210.
7. Mamoon M. Dental anomalies in children in North Jordan. *Pakistan Oral & Dental J* 2011;31(2):309-13.
8. Young Ho K. Investigation of hypodontia as clinically related dental anomaly: Prevalence and characteristics. *ISRN Dentistry* 2010;(2011):246135.
9. Vahid-Dastjerdi E, Borzabadi-Farahani A, Mahdian M, Amini N. Non-syndromic hypodontia in an Iranian orthodontic population. *J Oral Sc* 2010;52(3):455-61.
10. Tallón-Walton V, Nieminen P, Arte S, Carvalho-Lobato P, Ustrell-Torrent J, Manzanares-Céspedes C. An epidemiological study of dental agenesis in a primary health area in Spain: Estimated prevalence and associated factors. *Med Oral Patol Oral Cir Bucal* 2010;15(4):e569-74.
11. Celikoglu M, Kazanci F, Miloglu O, Oztek O, Kamak H, Ceylan I. Frequency and characteristics of tooth agenesis among an orthodontic patient population. *Med Oral Patol Oral Cir Bucal* 2010;15:797-801.
12. Gomes RR, Calaça da Fonseca JA, Paula LM, Faber J, Acevedo AC. Prevalence of hypodontia in orthodontic patients in Brasilia, Brazil. *European Journal of Orthodontics* 2009;32(2010):302–6.
13. Al-Ajwadi S. An orthopantomographic study of hypodontia in permanent teeth of Iraqi patients. *MDJ* 2009;6(2):139- 44.
14. Sisman Y, Uysal T, Gelgor IE. Hypodontia. Does the prevalence and distribution pattern differ in orthodontic patients? *European Journal of Dentistry* 2007;1(3):167-73.
15. Albashaireh Z, Khader Y. The prevalence and pattern of hypodontia of the permanent teeth and crown size and shape deformity affecting upper lateral incisors in a sample of Jordanian dental patients. *Community Dent Health* 2006;23(4):239-43.
16. Goren S, Tsoizner R, Dinbar A, Levin L, Brezniak N. Prevalence of congenitally missing teeth in Israeli recruits. *Refuat Hapeh Vehashinayim* 2005;22(2):49-53.
17. Fekonja F. Hypodontia in orthodontically treated children. *Euro J Orthod* 2005;27(5):457-60.
18. Polder BJ, Vant Hof MA, Van der Linden FPGM, Kuijpers-Jagtman J. More women in Europe and Australia have dental agenesis than their counterparts in North America. *Evidence-Based Dentistry* 2005;6(1):22–3.
19. Goya HA, Tanaka S, Maeda T, Akimoto Y. An orthopantomographic study of hypodontia in permanent teeth of Japanese pediatric patients. *J Oral Sc* 2008;50(2):143-50.
20. Ng'ang'a RN, Ng'ang'a PM. Hypodontia of permanent teeth in a Kenyan population. *East African Medical Journal* 2001;78(4):200–203.
21. Al-Emran S. Prevalence of hypodontia and developmental malformation of permanent teeth in Saudi Arabian schoolchildren. *Br J Orthod* 1990;17(2):115-18.
22. Davis P. Hypodontia and hyperdontia of permanent teeth in Hong Kong school children. *Community Dent Oral Epidemiol* 1987;15:218-20.
23. Rolling S. Hypodontia of permanent teeth in Danish schoolchildren. *Scand J Dent Res* 1980;88(5):365-9.
24. Magnusson TE. Prevalence of hypodontia and malformations of permanent teeth in Iceland. *Community Dent Oral Epidemiol* 1977;5:173–8.
25. Popa M, Dinu S, Bratu E. Interceptive treatment in hypodontia. *Jurnalul Pediatruului* 2010;10:43-46.
26. Hobson RS, Carter NE, Gillgrass TJ, Jepson NJ, Meechan JG, Nohl F, Nunn JH. The Interdisciplinary management of hypodontia the relationship between an interdisciplinary team and general dental practitioner. *Br Dent J* 2003;194(9):479-82.
27. Lazzara R et al. Retrospective multicenter analysis of 3i endosseous dental implants placed over a five year period. *Clin Oral Implant Res* 1996;7(1) :76-84.
28. Kirzioğlu Z, Sentut TK, Ozay Ertürk OS, Karayılmaz H. Clinical features of hypodontia and associated dental anomalies: a retrospective study. *Oral Diseases* 2005;11:399–404.
29. Ting-Ling C. Prosthodontic treatment of patients with hypodontia. *Cda. Journal* 2006;34(9):727-33.