

THE RELATIONSHIP BETWEEN UPPER INCISORS INCLINATION AND THE SUPPORTING BONE TISSUE: A CBCT STUDY

Nibras Dayoub* | Rabab Al-Sabbagh**

Abstract

The aims of the study were 1) to evaluate the supporting bone tissue thickness around 68 upper incisors and its relationship with their inclination, and 2) to investigate the impact of gender on these two variables.

Thirty-four patients with no previous orthodontic treatment participated in the study. Cone beam computed tomography (CBCT) scans were taken. Sagittal sections of the roots were made to evaluate the supporting bone at the labial and the lingual aspects and at three different levels: cervical, middle and apical. Angles of the upper central incisors (U1/U2) with the palatal plane (SPP) were also measured.

The palatal apical region had the greatest thickness of bone tissue followed by the palatal middle and the labial apical regions. The lowest thickness was observed on the labial surface, in the apical and in the middle of the root. The thickness of the labial apical region of both upper teeth increased significantly when the angle between the upper central incisors axis and the palatal plane increased (U1: $p = 0.012$ / $r = 0.42$ and U2: $p = 0.005$ / $r = 0.46$). The thickness of the palatal middle of the root regions for both upper central incisors were significantly higher in males than females (U1: $p = 0.005$ / average = 1.2 mm for males; U2: $p = 0.003$ / average = 1.0 mm for males). There was no significant difference in the incisors' inclination between males and females.

The bone tissue thickness in the labial apical region increased when the inclination of the upper central incisors increased. The greatest value of bone tissue amount was in the apical region, whereas the lowest value was in the labial surface in both cervical and middle of the root regions. Males had a higher value than females of bone tissue amount in the palatal middle of the root region at the upper central incisors.

Keywords: Bone tissue - upper central incisors inclination - CBCT.

IAJD 2015;6(3):101-107.

LA RELATION ENTRE L'INCLINAISON DES INCISIVES SUPÉRIEURES ET L'OS DE SUPPORT: UNE ÉTUDE RADIOGRAPHIQUE

Résumé

Cette étude a pour buts d'évaluer 1) l'épaisseur de l'os alvéolaire autour des incisives supérieures et la corrélation entre l'épaisseur osseuse et l'inclinaison des incisives, et 2) l'influence du sexe sur l'épaisseur de l'os et l'inclinaison des incisives.

Trente-quatre patients n'ayant subi aucun traitement orthodontique ont participé à l'étude. Des coupes tomographiques volumétriques à faisceau conique (CBCT) ont été réalisées. Des sections sagittales ont été faites sur les incisives supérieures pour évaluer l'épaisseur osseuse des surfaces labiale et palatine au niveau de 3 régions (cervicale, centrale et apicale) de la racine. Les angles formés par les incisives (U1 /U2) avec le plan palatin ont été encore mesurés.

La plus grande épaisseur d'os alvéolaire a été observée au niveau de la région palatine apicale, suivie par la région palatine centrale et la région labiale apicale. L'os alvéolaire des régions labiale cervicale et centrale de la racine étaient le moins épais.

La corrélation entre l'inclinaison des incisives et l'épaisseur de l'os alvéolaire était proportionnelle au niveau des deux incisives droite et gauche ($r1 = 0.42$; $p = 0.012$ et $r2 = 0.46$; $p = 0.05$, respectivement).

Les hommes avaient un os alvéolaire plus épais que celui des femmes dans la région palatine des 2 incisives supérieures droite ($p=0.05$) et gauche ($p=0.003$), respectivement. La différence d'épaisseur des deux incisives droite et gauche entre hommes et femmes était respectivement $av1 = 1.2\text{mm}$ et $av2 = 1\text{mm}$.

Par contre, aucune différence n'a été observée entre les hommes et les femmes en ce qui concerne l'inclinaison des incisives supérieures.

Mots clés : tissu de soutien – inclination des incisives – CBCT.

IAJD 2015;6(3):101-107.

* Msc, Dpt of Orthodontics,
Faculty of Dentistry, Hama University, Syria
d.nibras@hotmail.com

** Prof., Dpt of Orthodontics,
Faculty of dentistry, Hama University, Syria

Introduction

The orthodontic movement of teeth occurs within the alveolar bone, but this movement is limited by the alveolar bone dimensions [1].

One of the most orthodontic treatment procedures affected by the anatomical limits of the supporting bone is moving the incisors in the sagittal direction [2]. Such movement may lead into exceeding the anatomical limits and thus will result in complications that are so-called iatrogenic effects including loosening of bone or roots resorption [3].

These limits depend on several factors such as the initial morphology of the alveolar bone before starting the treatment, the amount of teeth movement and its direction.

The thickness of the alveolar bone around the teeth determines the amount of movements allowed [4, 5]. In order to achieve a sound anteroposterior orthodontic tooth movement of upper and lower incisors in patients with abnormal sagittal jaw relationship, knowledge of the sagittal width of the upper and lower anterior alveolus is essential.

Also, it has been confirmed that the vertical growth affects the thickness of the supporting bone [6 - 8]. Patients with long face usually have less amount of supporting bones compared with normal or short vertical growth patients, and this in return reduces the allowed movements available for teeth before reaching the anatomical limits. These patients are more likely to have periodontal complications caused by the orthodontic treatment.

Before introducing the computed tomography in the dental use, studies made on traditional radiographs were of limited values because of dental and skeletal superimposition, and thus the assessment of treatment results was restricted.

As a result of curvature and rotation of the patients head while taking the radiography, double edges could be seen in areas that have bilateral structures. In addition, it was hard to

evaluate the accurate position of roots or bone thickness without falling into many mistakes.

With the admission of the cone beam tomodensitometry, it became possible to obtain highly accurate and reliable radiographs for teeth and surrounding bone tissue with minimal radial exposure [9].

Periago et al. [10] noted that linear measurements taken from three-dimensional images are considered clinically accurate and realistic. Also, many studies showed the superiority of CBCT in quantitative assessment of supporting alveolar bone [11, 12].

One of the multiple indications of CBCT is the assessment of the alveolar bone thickness around roots as well as the determination of the initial position of roots regarding the buccal and palatal/ lingual aspects of the maxilla and the mandible.

The aims of the present study were to evaluate the alveolar bone thickness at the buccal and palatal aspects of the maxilla around the upper central incisors and to study the relationship between the bone thickness and the inclination of the upper central incisors.

Materials and methods

The study was conducted at the Orthodontic Department at the dental faculty of the University of Hamah, Syria. Patients who were seeking orthodontic treatment were examined. The inclusion criteria were:

- Age between 16-40 years.
- Skeletal Class I.
- Normal vertical growth.
- No previous orthodontic treatment.
- Existing of both left and right upper central incisors.
- Absence of root resorption.
- Absence of bone pathologies.

Only 34 patients were selected to be part of the sample group (depending on G-Power program, effect size $r = 0.54$). The sample included 20 females (58.80%) and 14 males (41.20%), with a mean age of 20.3 years.

Radiographs were obtained from 3D Scanora tomography from Soredex Finland, with 15 mA, 85 kV, 12 seconds exposure time. The resolution of images was 0.25 Voxel and 13*140 cm field of view. The study was carried out directly on sagittal sections using On Demand 3D program.

In order to include the required skeletal pattern in both sagittal and vertical dimensions, the following measurements were calculated:

Skeletal I, ANB= $2-4^\circ$ [13].

BJORK= $396^\circ \pm 6^\circ$; Y axis= $66^\circ \pm 3^\circ$ [13].

The angle between the axis of the upper central incisors (U1: right, U2: left) and palatal plane SPP was determined (Fig. 1).

(U1,U2) and the palatal plane (SPP) (determined by the anterior nasal spine (ANS) and the posterior nasal spine (PNS)).

In order to measure the bone thicknesses in the most central slice, the long axis of each of the upper incisors (the reference plane) was determined by drawing a line extending from the middle of the incisal edge to the end of the apical root passing by the middle of the root canal (Fig. 2).

From this sagittal section, three points were defined on the reference plane in the cervical (2 mm from the cemento-enamel junction), middle and apical regions of the root.

Then three perpendiculars were drawn from the previous points on the reference plane in order to calculate the bone thickness at these levels (Fig. 3).

Statistical analysis

SPSS version 19 was used to analyze the obtained data. Excel 2010 was used for the completion of the charts.

After 14 days, the examiner repeated the analysis of 17 randomly selected tomographs to estimate the error of measurement by using paired sample student t-test analysis.

To obtain the statistical analysis, first a descriptive analysis was performed to show the mean amount of

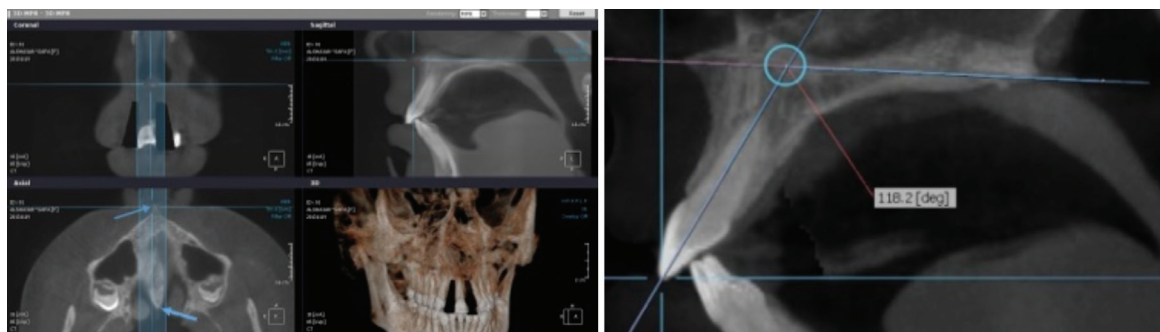


Fig. 1: Measurements of U1,2/SPP determined by the long axis of upper central incisors

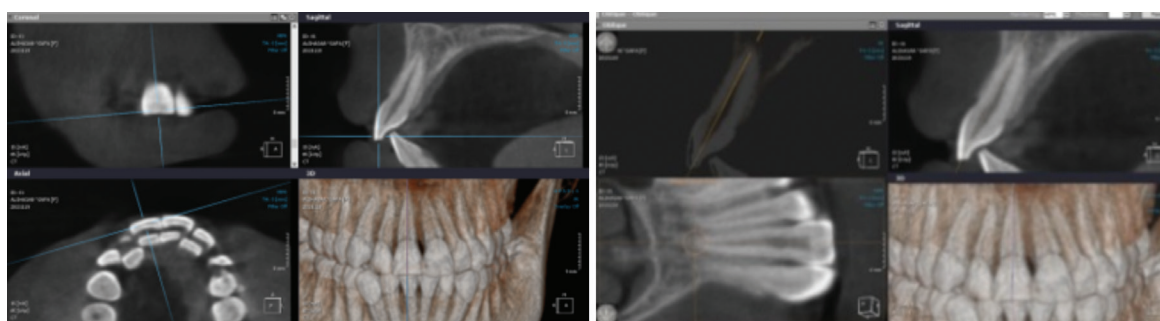


Fig. 2: Sagittal section passing by the long axis of the upper central incisor.

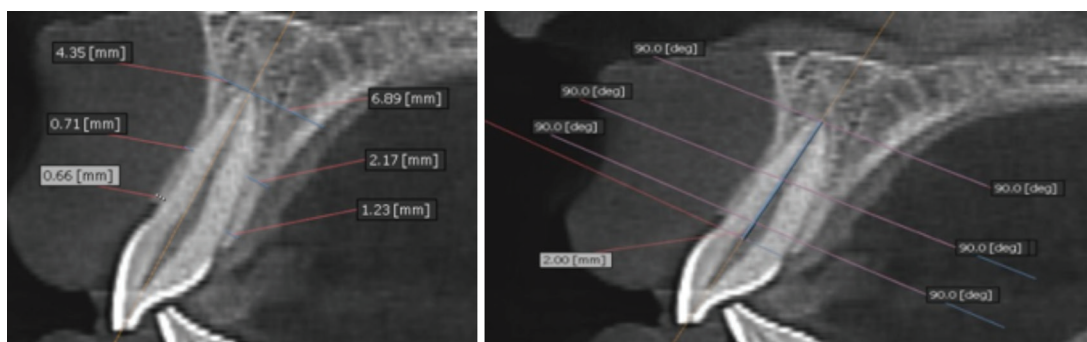


Fig. 3: Buccal and lingual bone tissue amounts around the upper central incisor.

bone tissue in the six studied areas of the upper incisors and of the U1,2/SPP.

To compare bone tissue amounts in the studied areas, a One-Way ANOVA was used, followed by Bonferroni analysis.

To compare measurements of bone tissue thickness and incisors inclination between genders, an independent sample t-test was used.

The Pearson correlation coefficient was calculated to determine the linear association between bone tissue thick-

ness and the upper incisors' inclination. The established level of reliability was 95%.

Results

A paired t-test analysis was used to verify the reliability of the measurements. The statistical analysis showed no significant differences between the first and the second measurements (Table 1).

The table 2 shows the mean and standard deviation of bone tissue thickness in the 3 regions of the root (cervical, middle and apical) on both surfaces (labial and palatal) for both teeth.

The table 3 presents the mean and standard deviation of bone tissue thickness in males and females.

The student t-test showed a significant difference between males and females in palatal/middle region for both upper teeth (mean difference

Variable	Mean difference	t-test	p- value
U1/SPP	0.035	0.945	0.358
U2/SPP	-0.611	-1.059	0.305
U1 / labial / cervical	0.007	0.824	0.421
U2/ labial / cervical	-0.005	-0.516	0.612
U1 / labial / middle	-0.028	-0.915	0.373
U2 / labial / middle	0.026	1.056	0.306
U1 / labial/ apical	-0.022	-0.861	0.40
U2 /labial / apical	-0.025	-1.023	0.321
U1 / palatal /cervical	-0.031	-1.272	0.221
U2 / palatal / cervical	-0.014	-2.005	0.062
U1 /palatal /middle	0.028	1.201	0.247
U2 / palatal / middle	0.002	0.127	0.899
U1 /palatal / apical	-0.008	-0.259	0.798
U2 / palatal / apical	0.573	1.090	0.291

Table 1: Paired t-test analysis to verify the reliability of the study.
 U1: upper right central incisor axis / U2: upper left central incisor axis / SPP: palatal plane.
 Significant difference for p- value > 0.05.

=1.202 for U1; p=0.05 and = 1.029 for U2; p=0.03) (Table 3).

The mean values for incisors' inclination for both teeth (U1 and U2) were 110.253 ± 6.687 for U1 and 110.579 ± 6.855 for U2.

Table 4 shows the mean value of the incisors' inclination for U1 and U2 when considering males and females.

No significant difference in incisors' inclination was found between males and females (Table 4).

The Pearson correlation between U/SPP and the amount of bone tissue illustrated a significant positive linear correlation for the labial apical region in both upper central incisors (U1: p=0.012; U2: p=0.05). The results showed that the higher the U/SPP value, the higher the labial apical bone tissue value for both upper central incisors.

Discussion

According to our knowledge, no studies have been published on the

quantitative relationship between the inclination of the upper central incisors and the surrounding bone tissue thickness. The only scientific paper correlating the alveolar bone thickness to the labial-palatal inclination was published by Nahas et al. [14] who studied thirty Brazilian patients including all vertical growth patterns. Another paper published by Yamada et al. [15] studied the relationship between bone tissue thickness and lower incisors' inclination in untreated patients with skeletal class III.

The present study included 34 adult patients with no previous orthodontic treatment with skeletal Class I and normal growth pattern in the vertical dimension. It is the first scientific paper evaluating bone tissue thickness of the upper central incisors, and investigating its quantitative relation to the incisors inclination.

Regarding bone tissue amounts, statistical results showed that the palatal apical region had the greatest amounts of supporting bone among all

other regions, followed by the palatal middle the and labial apical regions of the root. On the other hand, the labial cervical and labial middle regions had the lowest values of bone thickness among the other regions for both U1/ U2 (Fig. 4).

It seems that the greatest amounts of supporting bone are located in the apical region of the root for both upper central incisors and this is considered as a good indicator of supporting in this region, while the regions that have the least amount of bone tissue were located in the cervical of both upper central incisors.

In the light of these results, it seems that moving the roots of both upper central incisors will be relatively in safe range in the apical region because of the sufficient bone tissue amounts existing in this area whereas there is a high risk in the cervical region especially on the labial side. That's why it is recommended to avoid labial inclination of upper central incisors in patients with Class I skeletal with nor-

Variable	Tooth	Maximum	Minimum	Mean \pm SD
Labial / cervical	U1	1.92	0.00	0.874 \pm 0.442
	U2	1.38	0.00	0.872 \pm 0.376
Labial / middle	U1	1.40	0.30	0.978 \pm 0.269
	U2	1.50	0.40	0.971 \pm 0.285
Labial / apical	U1	5.00	1.40	2.547 \pm 0.970
	U2	4.11	1.50	2.513 \pm 0.816
Palatal / cervical	U1	3.40	0.00	1.211 \pm 0.615
	U2	2.60	0.00	1.218 \pm 0.513
Palatal / middle	U1	6.70	1.20	3.176 \pm 1.250
	U2	5.90	1.70	3.165 \pm 0.998
Palatal / apical	U1	12.90	1.24	7.872 \pm 2.276
	U2	11.80	4.30	8.057 \pm 1.899

Table 2: Mean and standard deviation of bone tissue thickness in all studied regions.

Variable		Females Mean \pm SD	Males Mean \pm SD	Mean difference	P-value
Labial/cervical	U1	0.807 \pm 0.434	0.997 \pm 0.450	0.189	0.237
	U2	0.861 \pm 0.425	0.891 \pm 0.282	0.029	0.831
Labial/middle	U1	0.993 \pm 0.264	0.950 \pm 0.289	-0.043	0.665
	U2	1.017 \pm 0.294	0.887 \pm 0.258	-0.130	0.208
Labial/apical	U1	2.548 \pm 1.002	2.547 \pm 0.952	-0.001	0.998
	U2	2.483 \pm 0.811	2.568 \pm 0.859	0.085	0.777
Palatal/cervical	U1	1.180 \pm 0.733	1.268 \pm 0.324	0.088	0.698
	U2	1.211 \pm 0.618	1.231 \pm 0.245	0.019	0.916
Palatal/middle	U1	2.753 \pm 1.105	3.953 \pm 1.157	1.201	0.005 *
	U2	2.802 \pm 0.799	3.831 \pm 1.011	1.029	0.003 *
Palatal/apical	U1	7.567 \pm 1.729	8.433 \pm 3.049	0.866	0.296
	U2	7.642 \pm 1.788	8.819 \pm 1.931	1.177	0.084

Table 3: Mean and standard deviation of bone tissue thickness in males and females.

* $p < 0.05$.

Tooth	Females Mean (degree) \pm SD	Males Mean (degree) \pm SD	Mean difference	P-value
U1	109.777 \pm 6.945	111.125 \pm 6.387	1.348	0.582
U2	110.214 \pm 6.397	111.250 \pm 7.879	1.021	0.717

Table 4: Mean values of upper incisors' inclination in males and females.

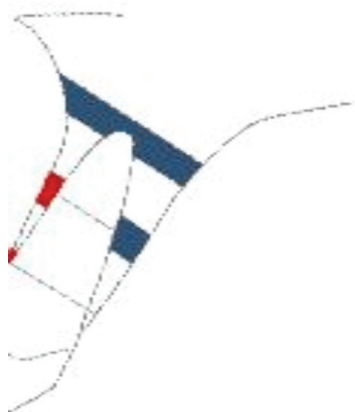


Fig. 4: In blue: Regions with most thickness of bone tissue; In red: Regions with least thickness of bone tissue.




Fig.5: The difference between torque movement and uncontrolled inclination in affecting the position of the root and crown.
a: Uncontrolled inclination; b: Torque movement.

mal vertical growth pattern to avoid the occurrence of bone dehiscence or fenestration.

To avoid this problem, moving the roots of incisors by torque movements (the center of rotation is located in the incisal edge) which affects the roots with maintaining the initial position of the crowns could be much safer than moving the crowns by uncontrolled inclination (center of rotation is located in unknown area between the center of resistance and the root apical) (Fig. 5).

It is worth to mention that Enhos et al. [16] found that bone dehiscence and fenestration have been seen in all three vertical skeletal patterns, but mostly in patients with normal and long vertical growth.

Regarding the correlation, Pearson test showed a significant positive linear correlation between the upper incisors' inclination and the labial apical thickness (pU1-value = 0.012 / pU2-value = 0.005). However, this correlation had a medium coefficient for both teeth ($r_1 = 0.42$ / $r_2 = 0.46$).

In other words, the thickness of the labial apical region increased when the incisors inclination increased.

The results of the present study were in agreement with those of Nahás et al. [14] who documented a relationship between bone tissue amount and upper incisors' inclination.

This study also showed that there are no significant differences in bone thickness between males and females except at the palatal middle of the root region which has a higher value in males for both upper central incisors. Nahás et al. [14] and Dempsey et al. [17] reported that males had greater bone amounts than females. However, Yu et al. [18] didn't report any effect of gender on the bone thickness.

Males have greater bone tissue thickness in the palatal side; this can be attributed to the fact that they have greater biting force than females (190 Newtons for males and 50 Newtons for females) as Osborne & Mao mentioned [19].

The current study also showed that there are no differences between genders in the upper incisors' inclination. Similar result were reported with Yu et al. [18] who was the only one who searched in the effect of genders on upper incisors' inclination.

These results support the suggestion which says that the individual anatomical differences should be taken into account when assessing the iatrogenic effects expected to occur during an orthodontic treatment.

It's very important before starting the orthodontic treatment to pay attention to the anatomical morphology of each patient individually with accurate assessment of the alveolar

bone thickness and the roots position in order to identify the proper biomechanical technique and the allowed tooth movement direction during all treatment stages.

In addition to the foregoing, it could be considered that moving the upper central incisors in the labial direction is a risk factor for bone dehiscence and fenestration occurrence due to the lack of bone tissue amounts in the labial cervical and middle of the root comparing with the other regions surrounding the incisors' root.

Conclusion

From the previous results and within the limitations of the present study, we can conclude:

- The thickness of the supporting bone tissue in the labial apical region for both upper central incisors increases with the incisors inclination.
- The greatest value of bone thickness was in the palatal apical region whereas the least thickness was in the labial cervical and middle of the root.
- Males had a greater amount of bone tissue in the palatal middle of the root than females.
- There is no effect of gender on the upper central incisors inclination.

References

- Lupi JE, Handelman CS, Sadowsky C. Prevalence and severity of apical root resorption and alveolar bone loss in orthodontically treated adults. *Am J Orthod Dentofacial Orthop* 1996;109(1):28-37.
- Fuhrmann, Raw. Three-dimensional evaluation of periodontal remodeling during orthodontic treatment. *Semin orthod* 2002;8(1):17-22.
- Mirabella AD, Artun J. Risk factors for apical root resorption of maxillary anterior teeth in adult orthodontic patients. *Am J Orthod Dentofacial Orthop* 1995;108(1):48-55.
- Edwards JG. A study of the anterior portion of the palate as it relates to orthodontic therapy. *Am J Orthod* 1976;69(3):249-273.
- Horiuchi A, Hotokezaka H, Kobayashi K. Correlation between cortical plate proximity and apical root resorption. *Am J Orthod Dentofacial Orthop* 1998;114:311-318.
- Garcia RM, Claro CAA, Chagas RV, Almeida G. Espessura do processo alveolar da região anterior da maxila e mandíbula em pacientes com discrepância óssea ântero-posterior. *Rev Dent Press Ortodont Ortop Facial* 2005;10(5):137-48.
- Gracco A, Luca L, Bongiorno MC, Siciliani G. Computed tomography evaluation of mandibular incisor bony support in untreated patients. *Am J Orthod Dentofacial Orthop* 2010;138:179-187.
- Tsunori M, Mashita M, Kasay K. Relationship between facial types and tooth and bone characteristics of the mandible obtained by CT scanning. *Angle Orthod* 1998;68:557-62.
- Huang J, Bumann A, Mah J. Three-dimensional radiographic analysis in orthodontics. *J Clin Orthod* 2005;39:421-8.
- Periago DR, Scarfe WC, Moshiri M, Scheetz JP, Silveira AM, Farman AG. Linear accuracy and reliability of cone beam CT derived 3-dimensional images constructed using an orthodontic volumetric rendering program. *Angle Orthod* 2008;78:387-395.
- Maki K, Inou N, Takanishi A, Miller AJ. Computer-assisted simulations in orthodontic diagnosis and the application of a new cone beam x-ray computed tomography. *Orthod Craniofac Res* 2003;6(Suppl1):95-101.
- Fuhrmann RAW, Wehrbein H, Langen HJ, Diedrich PR. Assessment of the dentate alveolar process with high resolution computed tomography. *Dentomaxillofac Radiol* 1995;24:50-54.
- Jacobson A, Jacobson R. Radiographic cephalometry from basics to 3D imaging. 2006. Second edition.
- Nahás-Scocate A, Brandao A, Patel M, Ximenez M, Chilvaqure I, Valle-corotti k. Bone Tissue amount related to incisors' inclination. *Angle Orthod* 2014;84:279-285.
- Yamada C, Kitai N, Kakimoto N, Murakami S, Furukawa S, Takada K. Spatial relationships between the mandibular central incisor and associated alveolar bone in adults with mandibular prognathism. *Angle Orthod* 2007;77:766-772.
- Enhos S, Uysal T, Yagci A, Veli İ, Ucar F I, Ozer T. Dehiscence and fenestration in patients with different vertical growth patterns assessed with cone-beam computed tomography. *The Angle Orthodontist* 2012;82:868-874.
- Dempsey PJ, Townsend GC, Martin NG, Neale MC. Genetic covariance structure of incisor crown size in twins. *J Dent Res* 1995;74:1389-98.
- Yu Q, Pan XG, Ji GP, Shen G. The association between lower Incisal inclination and morphology of the supporting alveolar bone - a Cone-Beam CT study. *Int J Oral Sci.* 2009;4:217-223.
- Osborne JW, Mao J. A thin bite force transducer with three dimensional capabilities. *Arch Oral Biol* 1993;38:139-44.