

STUDY OF THE PREVALENCE AND DISTRIBUTION OF IMPACTED TEETH AND ASSOCIATED PATHOLOGIES USING DIGITAL PANORAMIC IMAGE IN SYRIAN COASTAL AREA

Samira Zraiki* | Fida kaseeh**

Abstract

The aim of this retrospective study was to investigate the prevalence and pattern of impacted teeth and associated pathologies in the Syrian Coastal population

Digital Panoramic radiographs of 2700 patients aged 25 years and above were examined. The radiographs were collected from radiography centers in the Syrian coastal area. The classification of impaction, caries and root resorption of the adjacent teeth and increase in the pericoronal space were determined.

A total of 584 (21.6%) patients presented with at least one impacted tooth. Among the 755 impacted teeth, mandibular third molars were the most common (62.8%), followed by maxillary third molars (29.9%), maxillary canines (4.5%), and other teeth (1.45%). The most common angulation of impaction was the vertical in the mandible and maxilla and the most common level of impaction was level B in the mandible and level C in the maxilla. Pathological conditions associated with impacted third molars were found in 21.1%. Caries was the most commonly seen lesion 9.4% of the distal surfaces of adjacent second molars, root resorption 7.6% and increase in the pericoronal space of the dental follicle of more than 3 mm was seen in 6.1% of impacted third molar.

The prevalence of impacted teeth was high, and there was no predilection for impacted third molars between sexes. Caries, root resorption and pericoronal lesions were seen in relation to the impacted teeth.

Keywords: Impacted - digital panoramic - third molar – pathologies.

IAJD 2018;9(3):101-106.

ÉTUDE DE LA PRÉVALENCE ET DE LA DISTRIBUTION DES DENTS IMPACTÉES ET DES PATHOLOGIES ASSOCIÉES EN UTILISANT UNE IMAGE PANORAMIQUE NUMÉRIQUE DANS LA ZONE DE LA CÔTE SYRIENNE

Résumé

Le but de cette étude rétrospective était d'étudier la prévalence des dents incluses et les pathologies associées dans la population côtière syrienne.

Les radiographies panoramiques numériques de 2700 patients âgés de 25 ans et plus ont été examinées. Les radiographies ont été recueillies dans des centres de radiographie situés dans la zone côtière syrienne. La classification de l'inclusion, les caries, la résorption radiculaire des dents adjacentes et l'augmentation de l'espace péricoronal ont été déterminées.

Au total, 584 patients (21,6%) ont présenté au moins une dent incluse. Parmi les 755 dents incluses, les troisièmes molaires mandibulaires étaient les plus courantes (62,8%), suivies des troisièmes molaires maxillaires (29,9%), des canines maxillaires (4,5%) et des autres dents (1,45%). L'angulation de l'inclusion la plus courante était la verticale à la mandibule et au maxillaire et le niveau d'impaction le plus fréquent était le niveau B à la mandibule et le niveau C au maxillaire. Des conditions pathologiques associées aux troisièmes molaires incluses étaient retrouvées dans 21,1%. La carie était la lésion la plus fréquemment observée: 9,4% des surfaces distales des deuxièmes molaires adjacentes, une résorption radiculaire de 7,6% et une augmentation de l'espace péricoronal du follicule dentaire de plus de 3 mm étaient observées chez 6,1% des troisièmes molaires incluses.

La prévalence des dents incluses était élevée et il n'y avait aucune prédilection pour les troisièmes molaires incluses entre les sexes. Des caries, une résorption radiculaire et des lésions péricoronales ont été observées en relation avec les dents incluses.

Mots-clés: inclusion dentaire – panoramique digitale – dent incluse – troisième molaire .

IAJD 2018;9(3):101-106.

* Ass. Prof.,
Dept. of Oral Medicine,
Faculty of Dentistry, Tishreen University, Lattakia, Syria.

** MSc student,
Dept. of Oral Medicine,
Faculty of Dentistry, Tishreen University, Lattakia, Syria.
fidamohmd2@gmail.com

Introduction

The literature shows that tooth impaction is a frequent phenomenon [1-13]. Dental impaction may be the consequence of local factors. These factors may include mechanical obstruction (by a supernumerary tooth, cyst, or tumor) insufficient space in the dental arch due to skeletal incongruities (micrognathia), or the premature loss of deciduous teeth or a tooth–arch size discrepancy. Systemic factors such as genetic disorders, endocrine deficiencies, and previous irradiation of the jaws are also associated with a failure of tooth eruption [4, 14].

Impaction can be partial in case where the tooth is not completely encased in bone and is exposed in oral environment. Conversely, completely impacted tooth is one which is completely encased in bone and does not communicate with oral cavity [7, 9]. Deciduous teeth impactions are extremely rare, but when they occur, it is mostly seen in second molars [7]. Any permanent tooth can become impacted; however, third molars, maxillary canines, maxillary and mandibular premolars, and maxillary central incisors are the most frequently involved teeth [12, 13]. However, impactions of incisors and multiple impactions have also been reported in the literature [14, 15].

An impacted tooth can result in caries, pulp disease, periapical and periodontal disease, root resorption of the adjacent tooth, and even oral and maxillofacial tumors. Its diagnosis and treatment can be very troublesome to dentists. Its management is also esthetically and functionally important to the patient [16].

However although removal of impacted teeth is the most common oral surgical procedure, many investigators have questioned the necessity of removal for patients who are free of symptoms or associated pathologies. Such comments are based on the view that long-term retention of impacted teeth has little risk of pathological

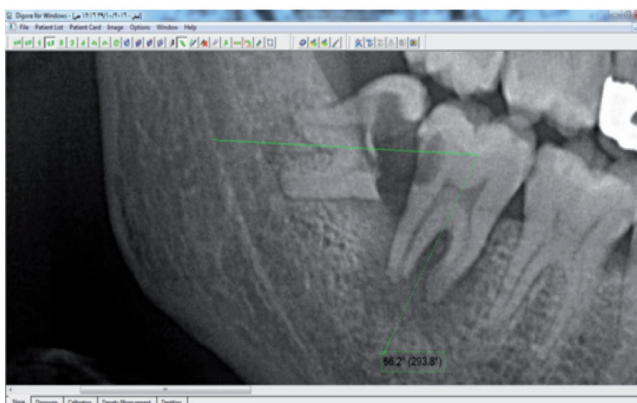


Fig. 1: The measurement of the third molar angulation using Digora software.

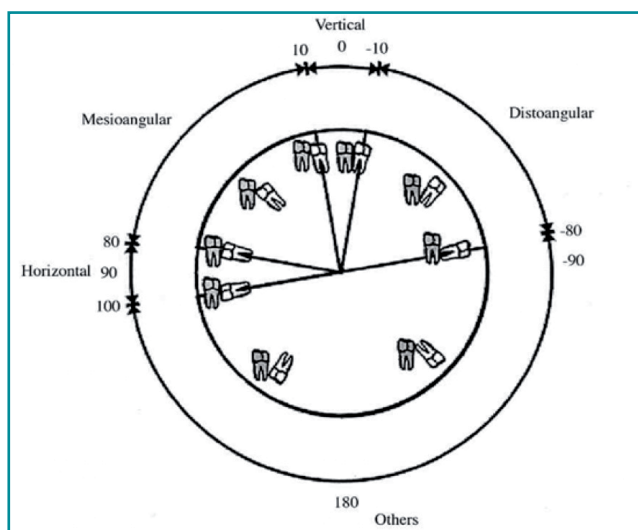


Fig. 2: The Quek classification system.

change in the tooth itself, or of adverse effects on adjacent structures.

There are currently no data on the prevalence of impacted teeth and associated pathologies in the Syrian Coastal area population. The aims of this study were to investigate the prevalence and pattern of impacted wisdom teeth and to report the features of associated pathologies

Materials and methods

This retrospective study was conducted from 2014 to 2016 and reviewed 2700 digital Panoramic x-rays which were collected from radiography centers in the Syrian coast (Latakia and Tartous). All panoramic radiographs were taken with Cranex D (CRANEX D,

Digital Panoramic and Cephalometric X-ray Unit, SOREDEX, FINLAND, version 2010). The minimum age for inclusion in the study was 25 years because the normal third molars finish their erupting at that age.

The patient's gender, number of impacted third molars, angulation of impaction, level of impaction and pathological conditions associated with impacted third molars were displayed by frequency and percentage.

For this study, impaction, and angulation and level of impaction were defined as follows: The tooth was considered impacted when it has completed its root growth and was not up to assumed normal functional position in the occlusal plane. The angulation of impaction of the third

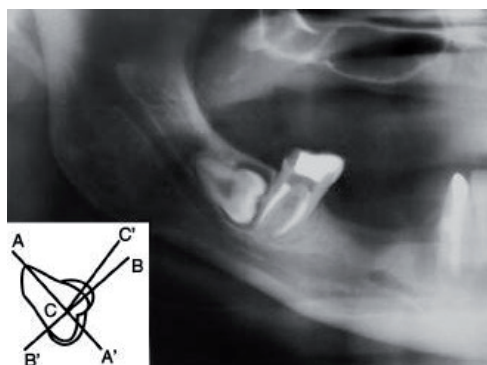


Fig. 3: The method of measurement the pericoronal space by Damante and Fleury.

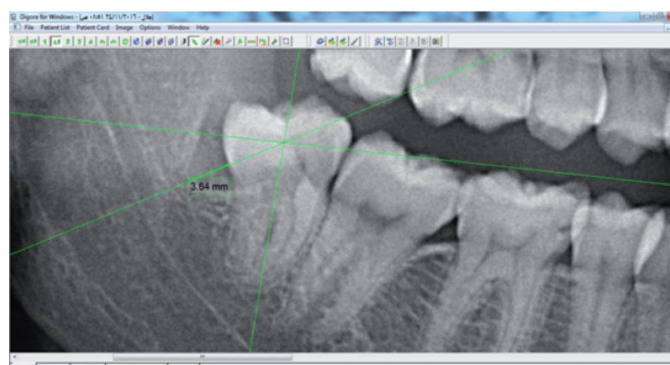


Fig. 4: The measurement of pericoronal space using Digora software.

Tooth type	FDI tooth numbering	Quantity	%
Mandibular third molars	38,48	474	62.8
Maxillary third molars	18,28	226	29.9
Maxillary canines	13,23	34	4.5
Mandibular canines	33,43	5	0.66
Mandibular premolars	34,35,44,45	5	0.66
Maxillary premolars	14,15,24,25	4	0.52
Maxillary central and Lateral incisors	11,12,21,22	4	0.52
Maxillary first and second molars	16,17,26,27	2	0.26
Mandibular first and second molars	36,37,46,47	1	0.13
Mandibular central and lateral incisors	31,32,41,42	0	0.0
Total		755	100

Table 1: Distribution of impacted teeth.

molar was determined by the angle formed between the intersected longitudinal axes of the second and third molars. This angle was measured using tools available in the Digora software (Digora for windows, Soredex, Finland, version 2.5) (Fig. 1).

The angulation of the impacted third molar was recorded using Winter's classification with reference to the angle formed between the intersected longitudinal axes of the second and third molars. The angulation of impaction was measured using Quek classification system (Fig. 2):

- i. Vertical impaction at 10° to -10° ;
- ii. Mesioangular impaction at 11° to 79° ;
- iii. Horizontal impaction at 80° to 100° ;

iv. Distoangular impaction at -11° to -79° ;

v. Others: 111° to -80° ;

vi. Buccolingual impaction.

Uncommon angulations such as mesioinverted, distoinverted and distohorizontal angulations were classified as 'other'. In case where the adjacent second molar was absent, the angle of impaction was recorded as non-applicable [17].

The level of impaction was determined using the Pell and Gregory classification as follows. Level A was recorded if the highest portion of the impacted third molar was on a level with or above the occlusal plane, whereas level B was recorded if the highest portion of the impacted third molar was below the occlusal plane but above the cervical

line of the second molar. Level C was recorded if the highest portion of the impacted third molar was below the cervical line of the second molar [18].

Pathologies associated with impacted teeth included

Caries of the adjacent teeth;

Root resorption of the adjacent tooth

An increase in the pericoronal space of the dental follicle of more than 3 mm around the impacted tooth.

Two perpendicular lines were drawn on the image, one passing through the long axis and the other, through the center of the crown. Starting from the intersection of the two lines, a line was moved to the widest point of the pericoronal space (Fig. 3), where the measurement was carried out [19].

The widest point was chosen because Thoma has described a lateral form of dentigerous cyst [20]. Measurement was conducted using Digora for windows (Fig. 4). The image ratio was 1:1 and there was no need for magnification correction. Two weeks later the same researcher repeated the measurements and evaluation.

Statistical analysis

Pearson's Chi-squared test was used to test the association between different variables. SPSS version 18 software package was used for data entry and analysis.

Results

Digital Panoramic radiographs of 2700 patients aged 25 years and above were examined. A total of 584 (21.6%) patients presented with at least one impacted tooth. The male to female ratio of the study group was (1173:1627), and the ratio for patients with impacted teeth was (241:343). The incidence of impacted teeth did not differ significantly between the sexes ($p > 0.05$).

Of the 755 impacted teeth, mandibular third molars were most commonly encountered (62.8%), followed by maxillary third molars (29.9%), maxillary canine (4.5%), and other teeth (1.45%) (table 1).

A total of 573 (21.2%) patients presented with at least one impacted third molar. There were 143 patients with one impacted third molar, 169 patients with two, 196 with three, and 135 patients with four.

75.7% of impacted mandibular third molars were either vertically or mesially angulated toward second molars while 64.4% of impacted maxillary third molars were either vertically or distally angulated in relation to second molars (Fig. 5).

Most maxillary third molars were Class C (48.9%), whereas in mandibular third molars, Class B (69.3%) was the most prevalent (Fig. 6).

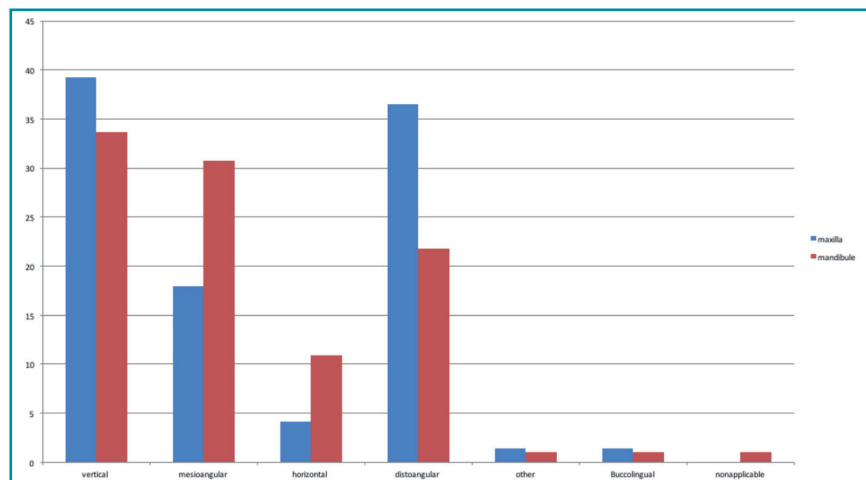


Fig. 5: Angulation of impacted third molars to the longitudinal axis of the second adjacent molar.

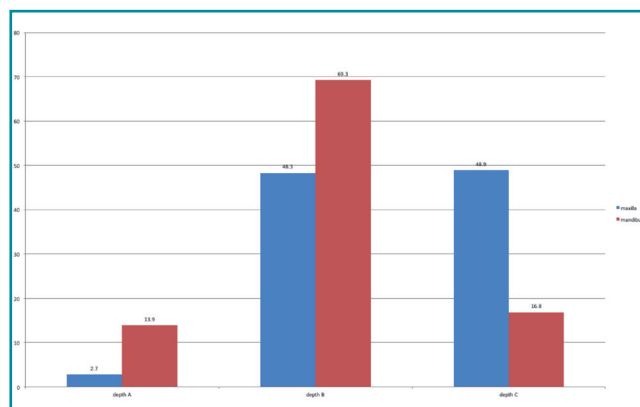


Fig. 6: The impaction depth of the third molar to the occlusal surface of the adjacent second molar.

Among the total of 700 third molars examined, 148 (21.1%) showed radiographically associated pathologic lesions. Caries were the most commonly seen lesion, accounting for 9.4% of the distal surfaces of adjacent second molars. Approximately 7.6% of second molars adjacent to impacted third molars had root resorption on the distal surface. Cyst formation (an increase in the pericoronal space of the dental follicle of more than 3 mm) was seen in 6.1% of impacted third molar. Pathologies were detected radiographically in 47 (15.9%) maxillary third molars and 115 (28.5%) mandibular third molars (Table 2).

Discussion

The panoramic radiograph, which provides information about all the teeth in both arches and the surrounding structures, is often the initial radiograph for the evaluation of impacted teeth. Unlike some previous studies that have sampled patients across a range of ages, this study investigated patients aged 25 years and above. The prevalence of impacted teeth in the study population was 21.6%, which was lower than that observed by Singh and Chakrabarty 33.6% [21] and more than the results reported by Chu et al. (28.3%) [4]. These differences may be attributed to racial factors and dif-

Pathologic condition	Maxilla		Mandible		Total in both jaws		p
	No.	%	No.	%	No.	%	
Caries in the second molars	24	8.1	42	10.4	66	9.4	0.306
Root resorption*	15	5.1	38	9.4	53	7.6	*0.032
Increase in the pericoronal space**	8	2.7	35	8.7	43	6.1	**0.006
Total	47	15.9	115	28.5	162	23.1	

Table 2: Distribution of pathologies associated with third molars.

* $p < 0.05$, ** $p < 0.01$.

ferences in the methodology of the study.

There was no statistically significant difference between the sexes ($p > 0.05$), a result that is consistent with that of the studies carried out by Fradi et al., and Singh and Chakrabarty [22, 21]. The observed pattern of impacted tooth type is similar to previous reports, with the most common impaction being that of the third molars, then the upper canines, and others [1-3].

The prevalence of impacted third molar in the study population was 21.2%, which was lower than those observed by Hattab et al. in a study conducted on Jordanian students (33%) [5], Al-Anqudi et al. (45.3%) on Omani population [23] and Chu et al. (27.8% of the Hong Kong Chinese population) [4].

On the other hand, studies by Celikoglu et al. [24] and Stanley et al. [25] reported lower frequencies of impacted third molars among Iranian (15.65%) and American (15.1%) populations.

In the current study, the most common number of impacted third molars per patient was two (29.49%), which is in agreement with the findings of Quek et al. [17] and Al-Anqudi et al. [23], but not with the results of the study of Hassan who reported that one was the most common number of impacted third molars [26]. In contrast, Ma'aaita reported that 40% of Jordanian patients had all four third molars [27].

Most impacted mandibular third molars were either vertically or mesially angulated while most impac-

ted maxillary third molars were either vertically or distally angulated. These results are similar to those reported by Haider and Shalhoub and Mehdizadeh et al. [6, 28], and differ from studies published by Quek et al. [17] and Patil [29] which found that mesioangular impaction was the most common type of third molar impaction. However Jung and Cho [30] had found that horizontal impaction was the most common type. This difference could be due to the fact that a different method of classifying angulation was used in these studies.

An analysis of the level of impaction showed that level B (69.3%) was the most common level of impaction in mandibular third molars, whereas in maxillary third molars, Class C (48.9%) was more frequent. These results are in agreement with the results of Mehdizadeh et al. [28] and Jung and Cho [30].

Pathological changes associated with impacted third molars were found in 21.1% in the current study which is higher than the 10% reported by Polat et al. in a Turkish population [31]. Prevalence of caries in second molars (9.4%) seen in the present study is more than the corresponding figures of 5.3%, reported by Patil [29] and 7.9% reported by Al-Khateeb and Bataineh [32]. In the present study, there were 7.9% of root resorption, a result similar to the 8% reported by Nitzan et al. [33]. Kahl et al. [34] reported that 8% of upper second molars and 9.5% of lower second molars had signs of root resorption. Conversely, Sewerin and Von Wowern did not find any resorption caused by impacted third molars

[35]. Stanley et al. stated that it is difficult to determine radiologically whether coronal radiolucency adjacent to an impacted third molar is due to caries or root resorption [25]. It is believed that intact tooth cementum should normally be able to withstand 'pressure' from neighboring impacted teeth.

The increase of the pericoronal space of the dental follicle of more than 3 mm around the impacted tooth was observed in 6.1% of the cases. Patil [29] showed that radiolucency in excess of 4 mm around the impacted tooth was prevalent in 3.6% of the impacted third molars [29]. Chu et al. [4] showed that 6.7% of patients aged > 50 years showed cystic changes more as compared to the younger age group.

Conclusion

The present study showed that the prevalence of impacted teeth was high among the screened population and there was no predilection for impacted third molars between sexes. The order of impacted tooth types was identical to previous reports. The most common angulation of third molar was the vertical in the mandible as well as in the maxilla. The most common level of impaction in mandible was level B and level C in maxilla. Caries, root resorption and pericoronal lesions were observed in relation to the impacted teeth. Further studies are needed to assess the pattern of tooth impaction in other regions of Syria.

References

- Lehtinen A, Oksala E. An orthopantomographic study of prevalence of impacted teeth. *Int J Oral Surg* 1972;3:117-20.
- Ahlqvist M, Grondahl HG. Prevalence of impacted teeth and associated pathology in middle-aged and older Swedish women. *Community Dent Oral Epidemiol* 1991;19:116-9.
- Brown LH, Berkman S, Cohen D, Kaplan AL, Rosenberg M. A radiological study of the frequency and distribution of impacted teeth. *J Dent Assoc S Afr* 1982;37:627-30.
- Chu F, Li T, Lui, V, Newsome P, Chow R, Cheung L. Prevalence of impacted teeth and associated pathologies-a radiographic study of the Hong Kong Chinese population. *Hong Kong Med J* 2003;9:158-163.
- Hattab FN, Alhaja ES. Radiographic evaluation of mandibular third molar eruption space. *Oral Surg Oral Med Oral Pathol Oral Radiol Endod* 1999 Sep;88(3):285-91.
- Haidar Z, Shalhoup SY. The incidence of impacted wisdom teeth in a Saudi community. *Int J Oral Maxillofac Surg*. 1986;15:569-71.
- Joshi M, Kasat V. Variations in impacted mandibular permanent molars: report of three rare cases. *Contemp Clin Dent* 2011;2:124-126.
- Gunduz K, Acikgoz A, Egrioglu E. Radiologic investigation of prevalence, associated pathologies and dental anomalies of non-third molar impacted teeth in Turkish oral patients. *Chin J Dent Res* 2011;14:141-146.
- Indira A, Kumar M, David MP, Rajsekar VM, Shashikala H. Correlation of pericoronitis and the status of eruption of mandibular third molar: A clinic-radiographic study. *J Indian Aca Oral Med Radiol* 2013; 25:0-0.
- Patil S. Prevalence and type of pathological conditions associated with unerupted and retained third molars in the Western Indian population. *Journal of Cranio-Maxillary Diseases* 2013;2:10-15.
- Adaki SR1, Yashodadevi BK, Sujatha S, Santana N, Rakesh N, Adaki R.. Incidence of cystic changes in impacted lower third molar. *Indian J Dent Res* 2013;24:183-187.
- Yavus MS, Aras MH, Buyukkurt MC, Tozoglu S. Impacted mandibular canines. *J Contemp Dent Pract* 2007;7:078-085.
- Bedoya MM, Park JH. A review of the diagnosis and management of impacted maxillary canines. *J Am Dent Assoc* 2009;140:1485-93.
- Duarte, BG, Assis D, Ribeiro –Junior P, Concales ES. Does the relationship between retained mandibular third molar and mandibular angle fracture exists? An assessment of three possible causes. *Craniofac Trauma Reconstr* 2012;5:127-136.
- Msagati F, Simon EN, Owibingire S. Pattern of occurrence and treatment of impacted teeth at the Muhimbili National Hospital, Dar es Salaam, Tanzania. *BMC Oral Health* 2013;13:1-6.
- Akarslan ZZ, Kocabay C. Assessment of the associated symptoms, pathologies, positions and angulations of bilateral occurring mandibular third molars: is there any similarity? *Oral Surg Oral Med Oral Pathol Oral Radiol Endod* 2009;108:e26-32
- Quek SL, Tay CK, Tay KH, Toh SL, Lim KC. Pattern of third molar impaction in a Singapore Chinese population: a retrospective radiographic survey. *Int J Oral Maxillofac Surg* 2003;32:548-52.
- Pell GJ, Gregory GT. Impacted mandibular third molars: Classification and Impacted mandibular third molars: Classification and modified technique for removal. *Dent Dig* 1933;39:330-8.
- Damante JH, Fleury RN. A contribution to the diagnosis of the small dentigerous cyst or the paradental cyst. *Pesqui Odontol Bras* 2001;15:238-46
- Thoma KH. The circumferential dentigerous cyst. *Oral Surg* 1964;18:368-371.
- Singh M; Chakrabarty A. Prevalence of Impacted Teeth: Study of 500 Patients. *International Journal of Science and Research* 2016;5(11).
- Fardi A, Kondylidou A, Bashour Z, Parisis N, Tsirlis A. Incidence of impacted and supernumerary teeth-a radiographic study in a North Greek population. *Med Oral Patol Oral Cir Bucal* 2011;16(1):e56-61.
- Al- Anqudi S, Al-Sudairy S, Al-Hosni A, Al-Maniri A. Prevalence and Pattern of Third Molar Impaction Retrospective study of radiographs in Oman. *SQU Medical Journal*, August 2014;14(3).
- Celikoglu M, Kama H, Oktay H. Investigation of transmigrated and impacted maxillary and mandibular canine teeth in an orthodontic patient population. *J Oral Maxillofac Surg* 2010;68:1001-1006.
- Stanley HR, Alattar M, Collet WK et al. Pathological sequel of "neglected" impacted third molars. *JOral Pat hol*;1988;17:113-117.
- Hassan AH. Pattern of third molar impaction in a Saudi population. *Clin Cosmet Investig Dent* 2010;2:109-113.
- Ma'aitha JK. Impacted third molars and associated pathology in Jordanian patients. *Saudi Dent J* 2000;12:16-19.
- Mehdizadeh M, Haghanifar S, Seyedmajidi M, Bijani A, Soufizadeh R. Radiographic Evaluation of Impacted Third Molars and Their Complications in a Group of Iranian Population, *Journal of Research and Practice in Dentistry* 2014;2014.
- Patil S. Prevalence and type of pathological conditions associated with unerupted and retained third molars in the Western Indian population. *Journal of Cranio-Maxillary Diseases* 2013;2:10-15.
- Jung YH, Cho BH. Prevalence of missing and impacted third molars in adults aged 25 years and above. *Imaging Sci Dent* 2013; 43: 219-25.
- Polat HB, Özan F, Kara I, Özdimir H, Ay S. Prevalence of commonly found pathoses associated with mandibular impacted third molars based on panoramic radiographs in Turkish population. *Oral Surg Oral Med Oral Pathol Oral Radiol Endod* 2008;105:e41-e47.
- Al- Khateeb TH, Bataineh AB. Pathology associated with impacted mandibular third molars in a group of Jordanians". *J Oral Maxillofac Surg*, 2006;4,(11):1598-602.
- Nitzan D, Karan T, Marmar Y. Does an impacted tooth cause root resorption of the adjacent one? *Oral Surg Oral Med Oral Pathol* 1981;51:221.
- Kahl S, Gerlak L, Kilgersr D. A long-term, follow-up, radiographic evaluation of asymptomatic impacted third molars in orthodontically treated patients. *Int J Oral Maxillofac Surg* 1994;23:279-285.
- Sewerin I, Von Wowern A. radiographic four-year follow up study of asymptomatic mandibular third molars. *Int Dent*. 1990;40:24.