

CLINICAL EFFICIENCY OF POLYMER BURS IN CARIES REMOVAL IN PRIMARY MOLARS AND RELEVANT PAIN PERCEPTION: A RANDOMIZED CONTROLLED TRIAL

Rima Maarouf* | Sherine Badr** | Hala Ragab***

Abstract

With the current cascade of minimally invasive restorative dentistry, developing new caries removal techniques is progressing towards a more biological and conservative approach. As such, polymer bur has emerged as a self-limiting selective tool for caries removal.

The aim of the present study was to assess the efficacy of polymer burs in comparison to hand excavators in caries removal in primary molars, and to assess the pain experienced by children while applying each method.

Thirty carious primary molars fulfilling the inclusion criteria were selected in four- to nine-year-old children. Fifteen teeth were allocated to each of the two subgroups: Group I (control group) and group II (test group) in which carious dentine was removed with a sharp excavator or polymer bur, respectively.

Efficiency of caries removal was numerically scored 0, 1, 2, 3, 4 and 5 using caries detector dye. Patient perception of the treatment procedure was measured using the "Wong-Baker Faces Pain Rating Scale". Mann-Whitney U tests were conducted to analyze the differences in caries removal and pain indicator with an alpha level of 0.05 as a decision point for statistical significance.

The statistical analysis showed that using a polymer bur was less efficient in complete caries removal in primary molars and inflicted higher pain scores compared to hand excavator method.

In conclusion, polymer bur did not improve the efficiency of caries removal nor inflicted less pain compared to hand excavators in primary molars.

Keywords: Caries - polymer bur - hand excavator – pain - efficiency.

IAJD 2018;9(1):9-14.

EFFICACITÉ CLINIQUE DES FRAISES EN POLYMÈRE DANS L'ÉXCISION DES CARIES AU NIVEAU DES MOLAIRES TEMPORAIRES ET LA PERCEPTION DE LA DOULEUR: UN ESSAI CONTRÔLÉ RANDOMISÉ

Résumé

Avec la tendance actuelle à choisir des traitements peu invasifs en dentisterie restauratrice, de nouvelles techniques d'excision de la carie ont été développées, plus biologiques et conservatrices. En tant que tel, la fraise en polymère est apparue comme un outil sélectif auto-limitant pour l'élimination des caries.

Le but de la présente étude était d'évaluer l'efficacité des fraises en polymère par rapport aux excavateurs manuels dans l'excision des caries au niveau des molaires de lait, et d'évaluer la douleur ressentie par les enfants lors de l'application de chaque méthode. Trente molaires de lait cariées répondant aux critères d'inclusion ont été sélectionnées chez des enfants de quatre à neuf ans. Quinze dents ont été attribuées à chacun des deux groupes: groupe I (groupe témoin) dans lequel la dentine cariée a été enlevée avec un excavateur tranchant et groupe II (groupe test) dans lequel la dentine cariée a été enlevée enlevée à l'aide d'une fraise fraise en polymère. L'efficacité de l'élimination des caries a été notée en utilisant un colorant détecteur de caries. La perception de la douleur ressentie par les patients durant le traitement a été mesurée en utilisant «l'échelle d'évaluation de la douleur de Wong-Baker Faces».

L'analyse statistique a montré que l'utilisation d'une fraise en polymère était moins efficace pour l'élimination complète des caries dans les molaires de lait et infligeait des scores de douleur plus élevés.

En conclusion, la fraise en polymère n'a pas amélioré l'efficacité de l'élimination des caries ni infligé moins de douleur par rapport aux excavateurs manuels au niveau des molaires de lait.

Mots-clés: caries dentaires - excavateur manuel – douleur – fraise en polymère.

IAJD 2018;9(1):9-14.

* Dpt of Pediatric Dentistry,
Faculty of Dentistry,
Beirut Arab University, Beirut, Lebanon
dr.rima.maarouf@gmail.com

** Dpt of Pediatric Dentistry,
Faculty of Dentistry,
Beirut Arab University, Beirut, Lebanon
Dpt of Pediatric Dentistry,
Faculty of Oral and Dental Medicine,
Cairo University, Giza, Egypt

** Dpt of Restorative Sciences,
Faculty of Dentistry,
Beirut Arab University, Beirut, Lebanon,
Dpt of Restorative Dentistry,
Misr University for Science
and Technology, Egypt

Introduction

One of the major goals of conservative dentistry is to develop method for removal of caries infected dentin while preserving caries affected dentin, thus, preventing disease progression and unnecessary tooth destruction and pain [1, 2]. Literature validation of the existence of two layers of carious dentine has made caries removal with minimal patient discomfort plausible. The superficial grossly denatured caries-infected dentine layer is a poor substrate for adhesive restorative materials; also, the underlying remineralizable layer of caries-affected dentine is highly impermeable to dentinal fluid transudate that may stimulate the underlying A-nerve fibers and cause pain and sensitivity during and after the procedure, respectively [3, 4].

Traditionally, diamond and tungsten carbide burs used for caries removal tend to remove infected as well as affected dentin as bulk because they are not selective in caries removal. In addition, total removal of all present caries may not be necessary to control progression of the lesion, provided that the cavity is adequately sealed from the oral environment [5]. Another drawback to conventional caries removal and cavity preparation using metal burs is the deleterious thermal and pressure effects on the pulp, which lowers the regenerative potential of the pulp-dentin complex. It is also crucial to highlight the amount of pain and discomfort inflicted on the patient by such aggressive methods, which is of great concern in the pediatric population in particular [6].

As such, alternative techniques for caries removal have been introduced as polymer burs and described as dentin safe. In 2000, Boston described a polymer bur as a tool that only removes softened and infected dentin but not the affected dentin. This minimally invasive excavation has the advantage of fewer dentinal tubules being cut; thereby, less pain sensations being triggered compared to using conventional burs.

The polymer bur looks like a tungsten carbide bur but its cutting edges are not spiral-like but shovel-like straight. It is constructed from a medical-grade polyether-ketone-ketone (PEKK) with a Knoop Hardness (KH) of 50- harder than caries infected dentin (KH 0–30) but softer than healthy dentin (KH 70–90). Utilized exclusively at low speed (500 - 800 rpm), the bur quickly dulls and vibrates when it encounters the more highly calcified caries-affected dentin [7, 8].

A systematic review conducted by Falk Schwendicke et al. in 2015 concluded that polymer burs were by far the least investigated method for caries removal *in vitro* as well as *in vivo*. It also concluded that there was insufficient data concerning their efficiency in caries removal to formulate definitive recommendations concerning their use [9]. Another systematic review conducted by Oliveira et al. in 2016 came out with clear recommendations urging clinicians to further investigate the clinical efficiency of polymer burs, the pain encountered and discomfort caused by such treatment modality [10].

Due to the previously mentioned advantages of the polymer burs, and based on the recommendations of the latest systematic reviews, the purpose of this study was to assess the clinical efficiency of polymer burs in caries removal in primary molars and children's pain perception while using each method.

Materials and methods

This randomized controlled clinical trial was conducted at the Specialty Dental Clinics in the Faculty of Dentistry at Beirut Arab University, Beirut, Lebanon. Thirty teeth fulfilling the inclusion criteria were selected.

Pre-operative examination was done to insure proper case selection, including medical history taking, clinical examination, digital photographs and radiographic examination. Children having at least one decayed primary molar, who were free from any

systematic disease and scored as definitely positive or positive on Frankl Behaviour Rating Scale, were chosen to participate in this study. For a decayed primary molar to be included in this study, it should be vital, asymptomatic, with distinct dentine involvement of medium or soft consistency according to probe inspection, and with at least half of the root length present as seen on peri-apical radiograph. Teeth with pathological processes, other than dental caries, developmental anomalies that could affect treatment, cracks or existing restorations in the carious regions were excluded from the study. Carious teeth with clinical or radiographic signs and symptoms of pulpal involvement as history of spontaneous throbbing pain, sensitivity to percussion, gingival redness, swelling or fistula were also excluded.

Ethical approval was attained from the International Review Board (IRB) at Beirut Arab University, prior to the initiation of the study (IRB pre-approval code: 2016H-0045D-M-0179). Full detailed treatment description, benefits and possible hazards were explained to the parents/guardians of the participating children and written informed consents were signed prior to participation of each patient in the study. Each included tooth was randomly assigned by a blinded withdrawal to one of the two groups as follows:

Group I: Control group (n=15): Carious dentine was removed using sharp hand excavator.

Group II: Test Group (n=15): Carious dentine was removed using the polymer bur (SmartPrep, SS White Burs, Inc., Lakewood, NJ, USA) mounted on a low speed handpiece (500–800 revolutions per minute) as recommended by the manufacturer without water spray. Caries removal proceeded until the polymer bur becomes dull after repeated contact with healthy dentin. There was no limit in the number of burs needed for each carious lesion [11].

Caries were removed without local anesthesia, unless requested by the patient and with partial isolation only

as recommended by the manufacturer [8]. Finally, the completion of caries removal was judged by the clinical criterion that a sharp explorer did not stick to dentine, and did not give a tug-back sensation [12]. The efficiency of caries removal by both methods was assessed by applying "Caries Detector" dye (Ultradent product inc. USA) onto each carious lesion for 10 seconds. The efficiency of caries removal was numerically scored 0, 1, 2, 3, 4 and 5 as shown in table 1 [13]. Two examiners, who did not participate in the clinical procedure and were unaware of the caries removal method used, evaluated the efficiency of caries removal in this study. The examiners used the Kappa index ($K=0.901$) to determine inter-examiner reliability.

Patient perception of the treatment procedure (pain and discomfort) was later measured using the "Wong-Baker Faces Pain Rating Scale". Each participating child was asked to rate the discomfort and pain he/she felt by selecting one of the faces that resembled his/her feelings at the time of the treatment the most [14] (Fig. 1).

After recording efficiency of caries removal, caries detector dye was applied repeatedly to the cavity and caries removal done until the residual dentine was no longer stainable. Teeth were then cleaned and cavities restored with light-cured resin composite (shade A2; 3M ESPE, St. Paul, MN, USA).

Statistical analysis

Statistical analysis was conducted to evaluate the caries removal using polymer bur and hand excavators' methods in primary molars. Descriptive statistics including mean, standard deviation, minimum and maximum values were computed. Kolmogorov Smirnov normality tests were considered to evaluate the normality of the data distributions. Mann-Whitney U tests were conducted to analyze the differences in caries removal and pain indicator. Spearman's correlation coefficients were used to

Caries detector Dye score	Stained cavity surface
0	Caries removed completely
1	Caries present in base of cavity
2	Caries present in base and/or one wall
3	Caries present in base and/or two wall
4	Caries present in base and/or more than two wall
5	Caries present in base, walls and margins of cavity

Table 1: Caries removal efficiency scoring system.

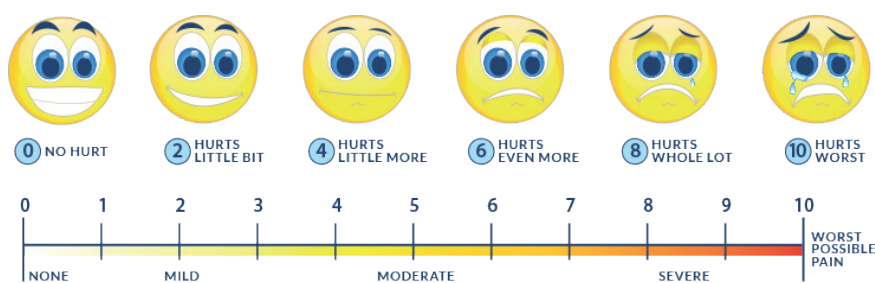


Fig. 1: Wong-Baker Faces Pain Rating Scale.

check the relationship between the two variables. All statistical analysis was conducted using SPSS v.17 (BM Corp; Armonk, NY). Charts were created using Microsoft Excel 2013. An alpha level of 0.05 was used as a decision point for statistical significance.

Results

The total thirteen patients in this study comprised five males (38.5%) and eight females (61.5%) with ages ranging from four to nine years old. The total sample of thirty teeth comprised eleven first primary molars (36.7%) and nineteen-second primary molars (63.3%) as shown in table 2. Carious lesions treated in this study were distributed between two class I (6.7%) and twenty-eight class II cavities (93.3%).

Concerning the efficiency of caries removal evaluated by using caries

detector dye, the results of this study showed significantly higher scores for caries detector dye for the polymer bur group compared to hand excavator group (p -value=0.016) (Table 3).

Pain scores using Wong-Baker Faces Pain Rating Scale were significantly higher for the polymer bur group compared to the hand excavator group (p -value=0.023) (Table 3).

Neither hand excavator group (p -value = 0.574) nor polymer bur group (p -value = 0.577) had significant relationship between the caries detector dye scores and Wong Baker Faces Pain Rating Scale according to Spearman's correlation coefficients.

Discussion

Preserving healthy tooth structure has become of paramount value with the evolution of minimally invasive

Caries removal method	N			Percent		
	First deciduous molar	Second deciduous molar	Total	First deciduous molar	Second deciduous molar	Total
Polymer bur	3	12	15	20.0	80.0	100
Hand excavation	8	7	15	53.3	46.7	100
All deciduous molars	11	19	30	36.7	63.3	100

Table 2: Deciduous molars distribution according to tooth type and caries removal method.

Studied variable	N	Caries removal method	Mean rank	P-value
Caries detector Dye Score	15	Hand excavator	11.97	0.016*
		Polymer bur	19.03	
Wong-Baker Faces Pain Rating Scale	15	Hand excavator	12.07	0.023*
		Polymer bur	18.93	

Table 3: Mann-Whitney tests results for caries detector dye score and Wong- Baker Faces Pain Rating Scale. * $p < 0.05$: significant differences.

restorative dentistry. The development of caries removal techniques in restorative dentistry is progressing towards a more biological and conservative direction. On the contrary, the traditional approach is not fundamentally conservative because it often results in cavity preparation that extends beyond the infected carious dentin layer into the non-infected remineralizable inner carious dentin or normal dentin [15]. Henceforth, the concept of self-limiting painless caries removal has become a field of great interest for dental clinicians and researchers especially in pediatric dentistry. As such, polymer bur has emerged as a relatively new bur in the dental market claiming that it is the ultimate bur for selective caries removal.

Allen et al. in 2005 stated that when dentin cutting is limited to the superficial layer of infected dentin, sparing the odontoblast reaction zone, caries removal could be completed without the need for local anesthesia. In addition, and in accordance to the manufacturer's instructions, polymer bur does not necessitate complete isolation. As such, treatment was initiated in this study without local anesthesia and without rubber dam to avoid any possible discomfort associated with clamp placement or injection that might jeopardize patient's cooperation and perception of the treatment [8].

The micro-hardness of carious dentin has been well studied and correlated with the pathology, providing a rational basis for developing a new

selective mechanical tool for caries excavation [16]. The hardness of sound dentin ranges from 70 to 90 KHN and carious dentin having hardness of zero to 30 KHN. The hardness of Smartprep polymer bur is 50 KHN, thus it is made to remove only the carious layers of the dentin, and wear off when contacting healthy dentin [7, 8]. In the present study, the tactile criterion was adopted to terminate caries excavation since it has always been the most widely used clinical criterion to evaluate complete caries removal [17]. Differences in the hardness, toughness, and resiliency of carious versus non-carious dentin would at least partially determine the relative efficiency with which these tissues could be removed by any new mechanical means of caries excavation.

Caries detector dyes have been developed to aid the diagnosis and removal of dental caries, by differentiating between infected, irreversibly deteriorated outer carious dentin and uninfected, but reversibly denatured inner carious dentin [18, 19]. Caries detector dye was used to detect the efficiency of each method in caries removal by selectively staining the loosened collagen matrices that have been irreversibly denatured. It has been shown that dyes dispensed in higher molecular weight carriers exhibited reduced diffusion properties in porous tissues; thus preventing over-staining and excessive removal of caries-affected or sound dentin [20].

The results of this study indicated that polymer bur has shown significant lower efficiency in dentin caries removal than hand excavation in primary molars. The reason for under-preparation of carious cavities by polymer burs could be due to the self-limiting nature of the bur where its cutting flutes would wear away rather than cut into healthy dentine. This means that whenever the bur encounters a healthy dentin frontier, it would dull becoming an inefficient cutting tool that needs to be replaced by a new one. This means once the operator detects macroscopically abraded flutes indicating that the bur has encountered healthy dentine, he/she must replace the bur before proceeding with caries removal. This renders using polymer burs in clinical practice utterly inconvenient specifically for the pediatric population. Checking the burs' cutting flutes repeatedly and frequent replacement of the bur during the treatment procedure not only increases treatment duration but also jeopardizes patient tolerance threshold and compliance, which is in reality the primary challenge for delivering pediatric dental services. On the contrary, hand excavator tends to remove softened carious dentin with more sensitive tactile feedback than burs rendering this method more efficient and more self-limiting of the two [21]. These results are coherent with those of the study

conducted by Celiberti et al. in 2006 who assessed caries removal effectiveness of four different dentin excavation methods. The study revealed that polymer bur and Er:Yag laser left the largest amount of decayed dentine in comparison to hand excavator and chemo-mechanical techniques [22]. In addition, Banerjee et al. in 2003 compared caries excavation techniques using decalcified dentin auto-fluorescence to determine caries removal to an adequate depth and concluded that hand excavation was the most reliable method to prevent over-preparation of the cavity dentin [23]. On the other hand, an assessment of bacterial count reduction following caries removal by three different techniques conducted by Zakirulla et al. in 2011 demonstrated divergent results concluding that polymer bur exhibited greater efficiency in caries removal than hand excavators [24]. Nevertheless, this paper has some limitations primarily denoted by the lack of random allocation of selected teeth, and the lack of standardization of the investigator for the polymer bur use. Not to forget that in the mentioned study, one polymer bur was exclusively allocated to each tooth in the polymer bur group; this would highly alter the results because of the self-limiting self-abrading nature of this bur. Finally yet importantly, outcomes might have also been affected by the operators' variability in excavation technique with the spoon excavator for microbial sampling and lack of standardization.

Because pain is a difficult subjective parameter to quantify, patient perception of the treatment procedure was assessed using the "Wong-Baker Faces Pain Rating Scale" comprehensible and suitable for the age group selected for this study [14]. As such, patients in the "hand-excavator" group experienced significantly less pain compared to those in the polymer bur group. It appears that the absence of the drill in the hand excavator group induced a great preliminary psychological relief as a head start for the treatment. The mild discomfort in the

hand excavator group was probably caused by the unpleasant sensation of scraping the decay, while the great pain and discomfort in the polymer bur group was majorly caused by vibration, noise, overheating, and excessive pressure. These findings are further emphasized by similar results of studies conducted by Pandit et al. in 2007 [25] and Kochhar et al. in 2011 [26].

Conclusion

Within the limitations of this study, it can be concluded that:

- Using polymer burs could not remove the efficiency of dentine caries removal in primary molars when compared to conventional hand excavators.
- Using polymer burs could not minimize pain perception in children when compared to conventional hand excavators method.

Hand excavation of carious lesions remains until current-date the "gold standards" for dentin caries removal.

Recommendations

Based upon our findings, this self-limiting technique of caries removal should undergo some modifications to enhance its selective cutting efficiency.

Polymer bur shall be compared to different minimal invasive caries removal methods, which might reveal a wider range of results.

Further studies on how different caries removal techniques might influence the adhesive bond strength to residual dentine in the prepared cavities are needed.

References

1. Featherstone J. The science and practice of caries prevention. *J Am Dent Assoc* 2000; 131:887-899.
2. Lee K, Son H, Yoshiyama M, Tay F, Carvalho R, Pashley D. Sealing properties of a self-etching primer system to normal caries-affected and caries-infected dentin. *Am J Dent* 2003;16:68A-72A.
3. McComb D. Systematic review of conservative operative caries management strategies. *J Dent Educ* 2001;65:1154-1161.
4. Kidd E. How 'clean' must a cavity be before restoration? *Caries Res* 2004;38:305-313.
5. Whitworth C, Martin M, Gallagher M, Worthington H. A comparison of decontamination methods used for dental burs. *Br Dent J* 2004;197:635-40.
6. Stanley H, Swedlow H. Biological effects of various cutting methods in cavity preparation: The part pressure plays in pulpal response. *J Am Dent Assoc* 1960;61: 450-56.
7. Daniel W and Boston D. New device for selective dentin caries removal. *Quintessence International, Indian edition* 2004;3, 40-47.
8. Allen KL, Salgado T, Janal M, Thompson V. Removing carious dentin using a polymer instrument without anesthesia versus a carbide bur with anesthesia. *J Am Dent Assoc* 2005;136:643-651.
9. Schwendicke F, Paris S, Tu Y. Effects of using different criteria for caries removal: A systematic review and network meta-analysis. *Journal of Dentistry* 2005;43:1-15.
10. Oliveira D, Barreiros D, Silva L, Silva R, Nelson-Filho P, Kuchler E. The effect of polymer burs on microbiological reduction of carious dentin in primary teeth: a systematic review. *Dentistry* 2016;16:1:a001.
11. Isik E, Olmez A, Akca G, Sultan N. A microbiological assessment of polymer and conventional carbide burs in caries removal. *J Pediatr Dent* 2010;32:316-23.
12. Wahba W, Sharaf A, Bakery N, Nagui D. Evaluation of polymer bur for carious dentin removal in primary teeth. *Alexandria Dental Journal* 2015;20:107-112.
13. Soni H, Sharma A, Sood P. A comparative clinical study of various methods of caries removal in children. *Eur Arch Paediatr Dent* 2015;16:19-26.
14. Garra G, Singer A, Taira B, Chohan J, Cardoz H, Chisena E, Thode H Jr. Validation of the Wong-Baker FACES Pain Rating Scale in pediatric emergency department patients. *Acad Emerg Med* 2010;17(1):50-4.
15. Roberson T, Heymann H, Swift E, Sturdevants C. *Sturdevant's art and science of operative dentistry* 2002. 4th Edition, Mosby, St. Louis.
16. Banerjee A, Sherriff M, Kidd E, Watson T. A confocal microscopic study relating the autofluorescence of carious dentine to its microhardness. *Br Dent J* 1999;187:206-210.
17. Rahimtoola S, van Amerongen E, Maher R, Groen H. Pain related to different ways of minimal intervention in the treatment of small caries lesions. *ASDC J Dent Child* 2000;67(2):123-7, 83.
18. Ansari G, Beeley J, Reid J, Foye R. Caries detector dyes - an in vitro assessment of some new compounds. *J Oral Rehabil* 1999;26:453-458.
19. Hosoya Y, Taguchi T, Tay F. Evaluation of a new caries detecting dye for primary and permanent carious dentin. *J of Dent* 2007;35:137-143.
20. Housseiny A, Jamjoum H. The effect of caries detector dyes and a cavity cleansing agent on composite resin bonding to enamel and dentine. *J Clin Pediatr Dent* 2000;25(1):57-60.
21. Banerjee A, Watson T, Kidd E. Dentine caries excavation: a review of current clinical techniques. *Br Dent J* 2000; 188(9): 476-477.
22. Celiberti P, Francescut P, Lussi A. Performance of four dentine excavation methods in primary teeth. *Caries Res* 2006;40(2):117-23.
23. Banerjee A, Kidd E, Watson T. In vitro validation of carious dentin removed using different excavation criteria. *Am J Dent* 2003;16:228-230.
24. Zakirulla M, Uloopi K, Subba Reddy V. In vivo comparison of reduction in bacterial count after caries excavation with 3 different techniques. *J Den Child* 2011;78(1):31-35.
25. Pandit I, Srivastava N, Gugnani N, Gupta M, Verma L. Various methods of caries removal in children: a comparative clinical study. *J Indian Soc Pedod Prev Dent.* 2007;25(2):93-6.
26. Kochhar G, Srivastava N, Pandit I, Gugnani N, Gupta M. An evaluation of different caries removal techniques in primary teeth: a comparative clinical study. *J Clin Pediatr Dent* 2011;36(1):5-9.