

DIGITAL ASSESSMENT OF SOFT AND HARD TISSUE ALTERATIONS AFTER ANTERIOR MAXILLARY TOOTH EXTRACTION

Robin Jalkh^{1*} | Stephanie Mrad² | Emile Chrabieh² | Joseph Bassil²

Objectives: This study aimed to assess dimensional alterations in soft and hard tissues 12 weeks post-extraction using novel computerized methods. Secondary objectives included exploring potential correlations between soft tissue changes and underlying bone variations, as well as investigating relationships between soft and hard tissue alterations and various contributing factors.

Methods: For all patients, preoperative and postoperative CBCT scans and intra-oral scans were obtained. Soft and hard tissue dimensions before extraction and at 12 weeks post-extraction were measured using 3D-slicer software. Both DICOM and STL files were superimposed, and measurements were taken at 2mm and 4mm from the facial crestal level.

Results: At twelve weeks, soft tissue thickness increased by 73.5% at 2mm and 51.2% at 4mm from the facial crestal bone. In contrast, there was a 42.5% and 33% bone resorption at 2mm and 4mm, respectively. Furthermore, the study found that smokers had a higher rate of soft tissue thickening and hard tissue resorption compared to non-smokers. The female group exhibited greater soft tissue thickening and bone resorption than the male group. Finally, the central incisor showed the highest bone loss rate, followed by the canine and the lateral incisor.

Conclusions: Three months following tooth extraction, a physiological thickening of the facial soft tissue occurs concurrently with significant bone loss beneath it.

Clinical Significance: This article's novel digital assessment methods for evaluating soft and hard tissue alterations offer the potential to optimize treatment planning, enhancing patient outcomes and minimizing complications. By providing a comprehensive understanding of post-extraction tissue changes, it empowers clinicians to tailor treatments for individual patients, improving predictability and personalized care.

Keywords: digital, tooth extraction, bone remodeling, soft tissue, hard tissue, wound healing.

Corresponding author:

Robin Jalkh, e-mail: eljalkhrobin@gmail.com

Conflicts of interest:

The authors declare no conflicts of interest.

1. Department of periodontics, Faculty of Dental Medicine, Saint Joseph University of Beirut, Beirut, Lebanon

2. Department of Oral Surgery and Implantology, Faculty of Dental Medicine, Saint Joseph University of Beirut, Beirut, Lebanon

ÉVALUATION NUMÉRIQUE DES ALTÉRATIONS DES TISSUS MOUS ET DURS APRÈS L'EXTRACTION DES DENTS MAXILLAIRES ANTÉRIEURES

Objectifs: Cette étude vise à évaluer les modifications dimensionnelles des tissus mous et durs 12 semaines après l'extraction à l'aide de nouvelles méthodes informatisées. Les objectifs secondaires comprenaient l'exploration des corrélations potentielles entre les changements des tissus mous et les variations osseuses sous-jacentes, ainsi que l'investigation des relations entre les altérations des tissus mous et durs et divers facteurs contributifs.

Méthodes: Pour tous les patients, des scanners CBCT préopératoires et postopératoires ainsi que des scans intra-oraux ont été réalisés. Les dimensions des tissus mous et durs avant l'extraction et à 12 semaines après l'extraction ont été mesurées à l'aide du logiciel 3D-slicer. Les fichiers DICOM et STL ont été superposés, et les mesures ont été prises à 2 mm et 4 mm de la crête faciale.

Résultats: À douze semaines, l'épaisseur des tissus mous a augmenté de 73,5 % à 2 mm et de 51,2 % à 4 mm de la crête osseuse faciale. En revanche, il y a eu une résorption osseuse de 42,5 % et 33 % à 2 mm et 4 mm, respectivement. De plus, l'étude a révélé que les fumeurs présentaient un taux plus élevé d'épaississement des tissus mous et de résorption osseuse par rapport aux non-fumeurs. Le groupe féminin a montré un épaississement plus important des tissus mous et une résorption osseuse plus importante que le groupe masculin. Enfin, l'incisive centrale a montré le taux de perte osseuse le plus élevé, suivi par la canine et l'incisive latérale.

Conclusions: Trois mois après l'extraction d'une dent, un épaississement physiologique des tissus mous faciaux se produit simultanément à une perte osseuse significative en dessous.

Signification Clinique: Les nouvelles méthodes d'évaluation numérique des modifications des tissus mous et durs post-extraction offrent le potentiel d'optimiser la planification du traitement, améliorant les résultats des patients et réduisant les complications. En fournissant une compréhension complète des changements tissulaires post-extraction, cela permet aux cliniciens d'adapter les traitements aux patients individuels, améliorant la prévisibilité et les soins personnalisés.

Mots-clés: extraction dentaire, remodelage osseux, tissu mou, tissu dur, cicatrisation des plaies.

Introduction

After tooth extraction, alveolar ridge dimensions undergo dynamic physiological remodeling processes [1]. This significant socket can impact subsequent implant placement and prosthetic restoration at the concerned site [2]. Extensive research has indicated that bone resorption is particularly pronounced within the first year after extraction, with noticeable changes becoming apparent during the initial three months [3, 4]. Notably, studies have reported an average vertical reduction of 1.2 mm and a mean horizontal decrease of 3.8 mm in the alveolar socket within the first six months post-extraction [5, 6].

Wound healing is a complex process that requires interactive coordination among various tissues and cells, involving precisely regulated spatial and temporal expression [7]. Following tooth extraction, the alveolar socket undergoes changes in both bone and soft tissue morphologies [8]. While various studies have primarily focused on bone biology to understand dimensional changes following extraction [9], other research examines both hard and soft tissue alterations, revealing a typical physiological response after tooth removal [10]. These studies observed a significant reduction in the volume of the remaining alveolar bone, ranging between 40 to 60% [11], as well as in the keratinized mucosa and the soft tissue thickness [11-14]. Furthermore, it has been demonstrated that the recovery of soft tissues is partly influenced by that of the underlying bone tissue, despite similar healing patterns observed in oral wounds [10]. However, establishing a definitive correlation between soft and hard tissue alterations after tooth extraction remains a challenge due to insufficient evidence [15].

Soft tissue plays a crucial role in achieving successful esthetic outcomes around implants in the anterior maxilla [16]. It creates a vital biological seal, preserving a healthy

surrounding environment and preventing peri-implantitis [17]. Therefore, the quality and quantity of peri-implant soft tissues contribute to the long-term survival of implants [18]. Despite the growing body of evidence, the precise interplay between soft and hard tissues in overall alveolar ridge alterations remains unclear. While alveolar ridge preservation has received significant attention [19-21], the impact of soft tissue alterations after extraction and its relationship with underlying bone dimensions have not been thoroughly studied in clinical research [12]. Recent advancements in digitalization and optical scanning have enabled the assessment of the volume and contour of soft tissue surrounding teeth and implants. These techniques hold the potential to enhance our understanding of dynamic occurring in soft and hard tissues during the healing period [22, 24].

The primary objective of this study is to use novel digital methods to assess the dimensional alterations of soft and hard tissues twelve weeks after extraction. The secondary objectives include correlating changes in facial soft tissues with underlying bone dimensions and comparing soft and hard tissue alterations among smokers and non-smokers subjects, male and female subjects, and different types of anterior maxillary teeth (incisors, laterals, and canines).

Materials and Methods

Study sample

This study involved the examination of thirty-eight adult teeth sourced from fifteen patients necessitating simple extractions within the anterior maxillary region (From Canine to Canine). Nine teeth were excluded from the analysis due to buccal bone fracture during extraction. The study included 13 central incisors, 10 lateral incisors, and 6 canines. Subjects in this study were classified as male/female and smokers/non-smokers. Patients

classified within the smokers group exhibited heavy smoking habits, defined as consuming 25 or more cigarettes per day.

Inclusion criteria:

- Age above 18 years
- Teeth located in the anterior maxillary region (canine to canine)
- No simultaneous immediate implant placement

Exclusion criteria:

- Systemic diseases that could affect bone and soft tissue healing.
- Buccal bone fracture during extraction
- Pregnancy
- Individuals with a history of intravenous bisphosphonates.

This prospective clinical trial received approval from the ethical committee of Saint-Joseph University of Beirut. All subjects carefully read and signed a written informed consent to take part of the study.

Surgical Procedure:

Prior to the extraction, all subjects took a CBCT scan (using ORTHOPHOS SL 3D, Dentsply, Sirona, Sweden) and a digital impression (3shape, TRIOS). Patients were then instructed to rinse for one minute with a 0.12% Chlorhexidine solution. After local anesthesia (Mepivacaine 1/200000), atraumatic tooth extraction was performed. Analgesic medication (1g paracetamol every 8 hours in case of pain) and a mouthwash with 0.12% Chlorhexidine (twice daily for 1 week) were prescribed to each subject. Twelve weeks later, the concerned patients took another CBCT scan and digital impression.

Comparison of hard tissue dimensions before and 12 weeks post-extraction

To visualize hard tissue dimensions, the two DICOM files (right before extraction and twelve weeks later) were aligned and superimposed using "3D slicer" software [15]. Accurate alignment was achieved by selecting three fixed bone referenc-

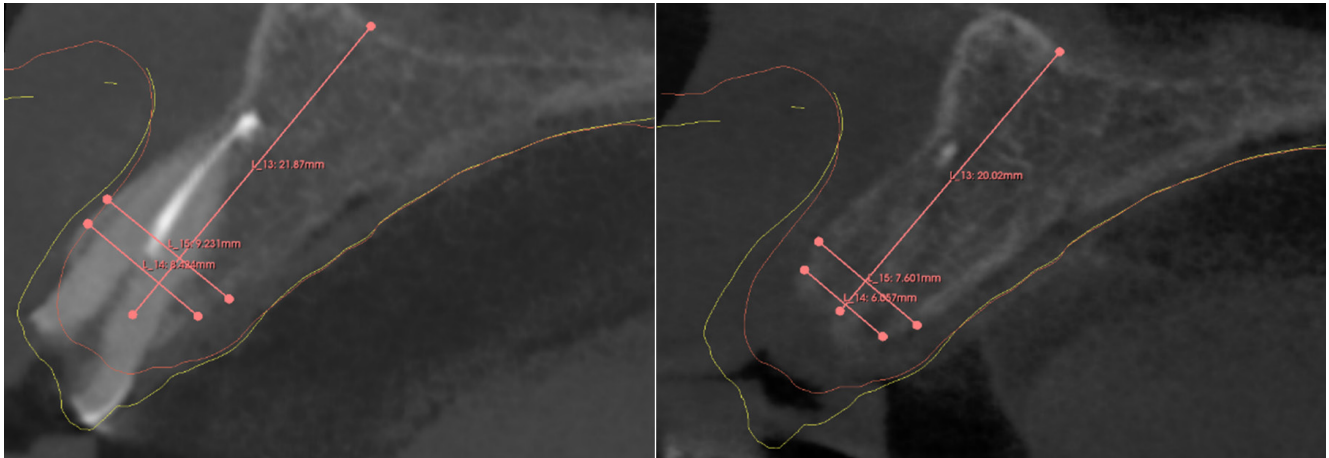


Figure 1. Bone dimensions measurements of the pre and postoperative CBCTs using 3d slicer software

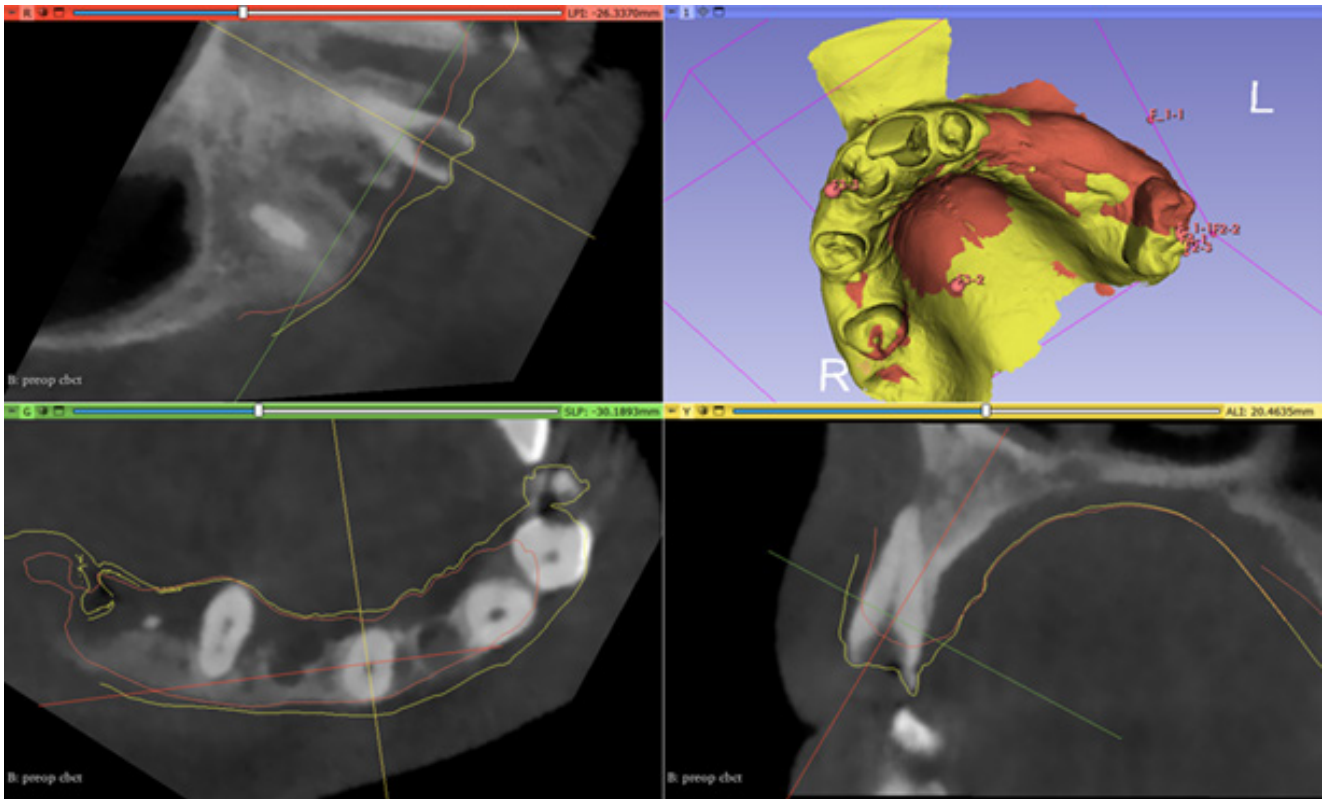


Figure 2: Image showing the 3d superimposition and alignment of the two DICOMS on the preoperative Cone beam CT scan . The white line represents the preoperative soft tissue limits while the red line represents the postoperative soft tissue limits.

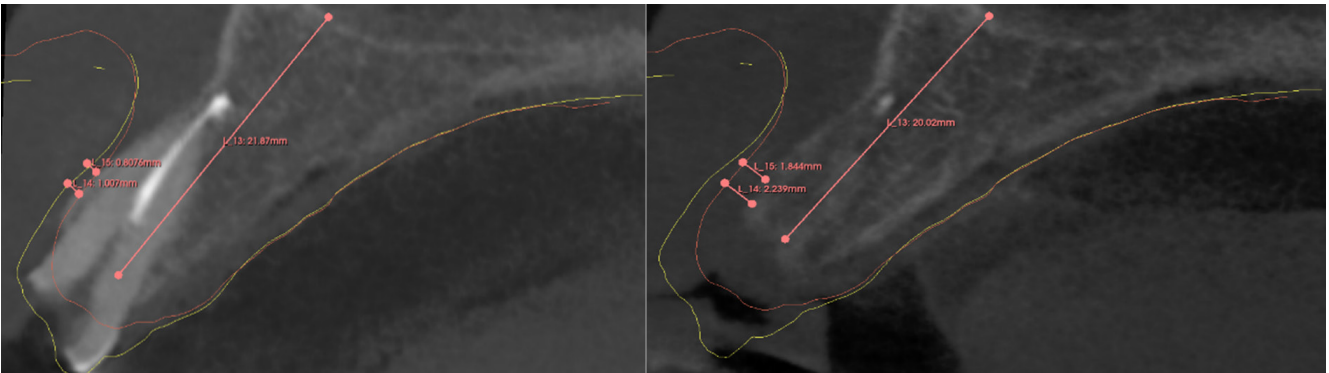


Figure 3. Facial soft tissue thickness measurements of the pre and postoperative CBCTs using 3D slicer

es points: the anterior and posterior nasal spine and the medial plate of the pterygoid process. Bone thickness was concurrently measured at 2mm and 4mm distances from the preoperative facial bone crest, and bone height was measured from the facial bone crest to basal bone borderline (Figure 1). The hard tissue measurements are expressed as dimensions (Thickness x height). For reference, the preoperative hard tissue dimensions at 2mm from the facial bone crest are denoted as **B2** (W2 x H), and **B4** (W4 x H) at 4mm. Similarly, the postoperative hard tissue dimensions are denoted as **B2'** (W2' x H') and **B4'** (W4' x H') respectively. Top of Form

Comparison of facial soft tissue thickness before and 12 weeks post-extraction

The Standard Tessellation Language (STL) data sets taken immediately before and 12 weeks after extraction were registered. These data sets were segmented using 3shape dental imaging software (TRIOS, Dental Desktop, Ortho System and Dental System) and then transferred to Medit link (Medit) software for superimposition and alignment. The software automatically handled scan alignment for patients with remaining upper arch teeth. For patients without remaining teeth, fixed anatomical landmarks such as the hard palate were manually selected for proper alignment. Once the alignment process was completed, the aligned STLs data sets were exported to 3D slicer and aligned with the patient's Cone Beam CT scan using anatomic landmarks. This resulted in superimposition and alignment of the pre and postoperative DICOM scans and STL data sets (Figure 2).

The thickness of facial soft tissue was measured simultaneously at 2mm and 4mm from the preoperative facial bone crest (Figure 3). For reference, the preoperative soft tissue thickness at 2mm from the facial bone crest was denoted as **A2**, and **A4** at 4mm. Similarly, the postoper-

ative soft tissue facial thickness was labeled as **A2'** and **A4'** respectively.

Statistical analysis

The test and analysis/ graphs conducted in this study were generated using the scientific modules in python such as plotly, NumPy and SciPy. All tests were performed under a marginal error of 5% (i.e., the corresponding p-value for each test should be: p-value \leq 0.05), and are distributed as follows:

- The Kolmogorov-Smirnov's test was performed to identify the data's distribution.

- The Wilcoxon signed rank was applied to highlight the significant difference between the measurements before and after the surgery.

In addition, a descriptive statistic was established during this study.

Results

The study included 15 subjects, comprising 7 males and 8 females. The average age of the subjects was 56 years old. Among them, 6 individuals were identified as smokers. A total of 29 teeth were extracted and analyzed within this study, in-

Table 1. Table showing the descriptive statistic of pre and postoperative soft tissue thickness at 2 and 4 mm from the reference line

	N	Minimum	Maximum	Mean
A2	29	0.56	2.8	1.32
A4	29	0.55	3	1.66
A2'	29	0.73	4.73	2.29
A4'	29	1.16	4.97	2.51

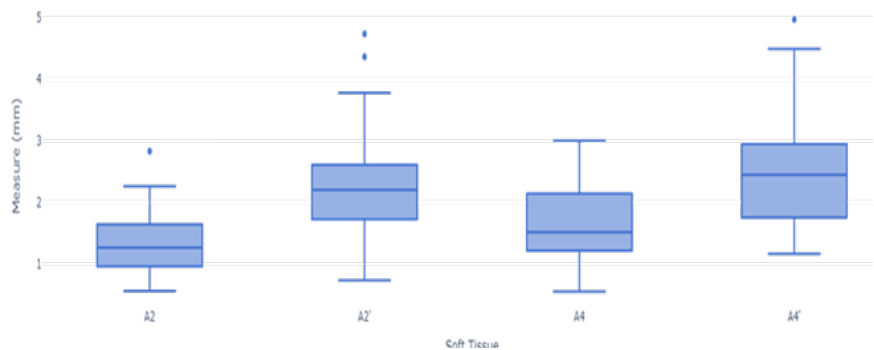


Figure 4. Graph showing the thickness representation of the soft tissue at 2 and 4mm from the reference line

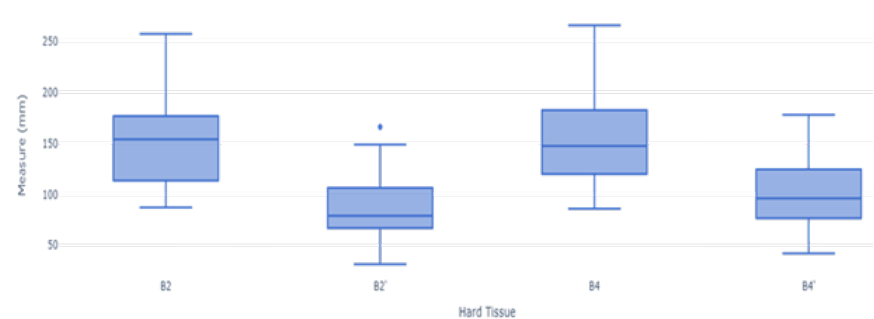


Figure 5. Graph showing the dimensional representation of the hard tissue at 2 and 4mm from the reference line.

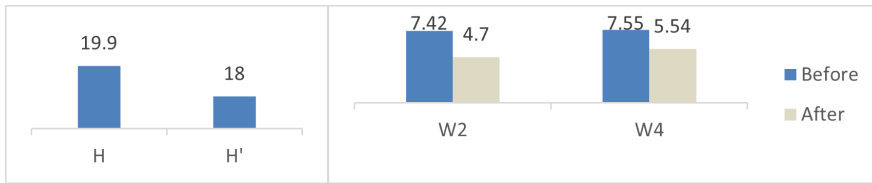


Figure 6. Graphs showing hard tissue's height and width before and after 12 weeks of the extraction

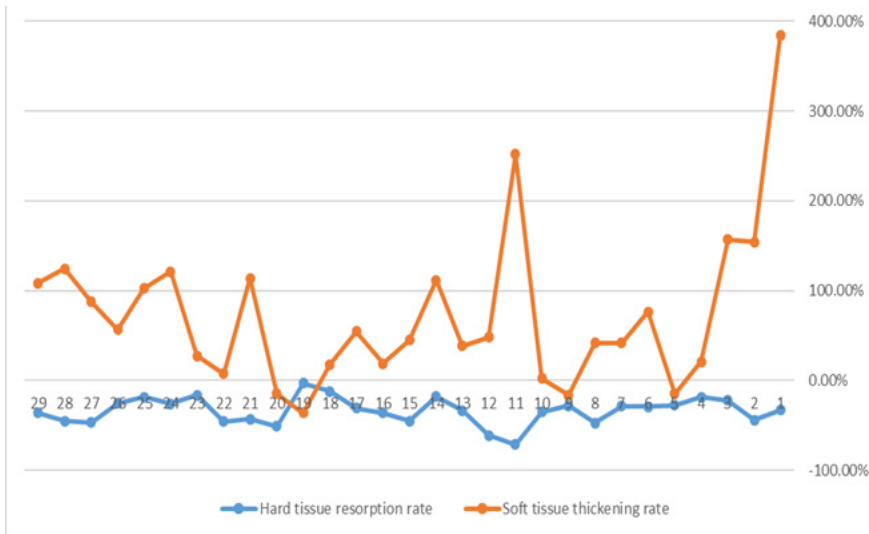


Figure 7. Graph representing the percentage of increase and resorption of the soft tissue thickness and hard tissue dimensions, respectively (At 4mm from the reference line)

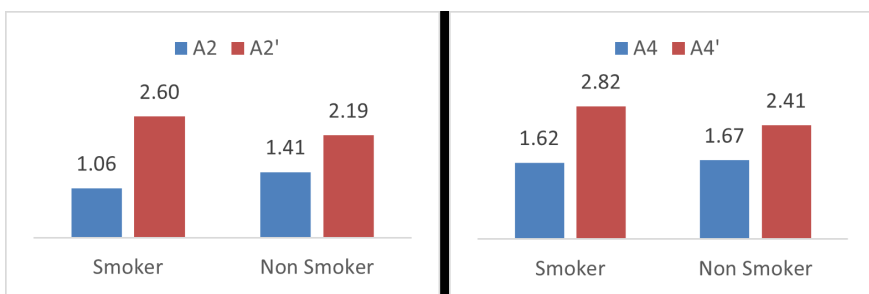


Figure 8. Chart showing the soft tissue mean's alteration between smoker and non-smoker groups at 2 mm and 4 mm

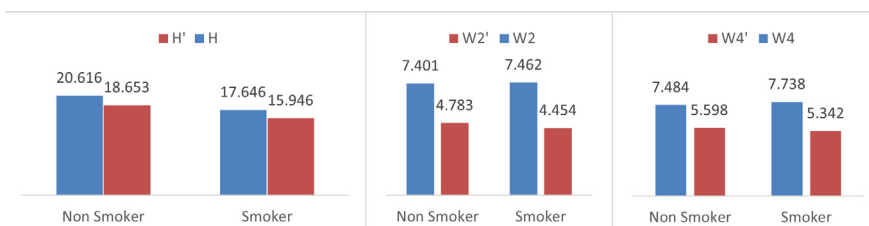


Figure 9. Charts showing the hard tissue mean's height and width alteration between smoker and non-smoker groups at 2 mm and 4 mm

cluding 13 central incisors, 10 lateral incisors, and 6 canines.

Facial soft tissue thickness alterations

After twelve weeks following extraction, facial soft tissue thickness exhibited a mean increase of 73.5% at 2mm, with thickness ranging from 2.26 mm for A2 to 4mm for A2' (Table1). However, at the 4 mm level, there was a 51.2% increase, with thickness varying from 2.45 mm for A4 to 3.81 mm for A4' (Figure 4).

Hard tissue dimension alterations

Twelve weeks post-extraction, hard tissue dimensions displayed a mean resorption rate of 42.5% at 2mm (Width loss = 2.42 mm / Height loss = 1.9 mm), with dimension ranges of 169 mm for B2 to 134 mm for B2' (Figure 5). At 4 mm from the reference line, a 33%-dimensional resorption was observed (Width loss = 2.01 mm / Height loss = 1.9mm). For B4 and B4', the dimension ranges shifted from 179 mm to 135 mm, and the median from 147 mm to 96 mm (Figures 5 and 6).

Facial soft tissue relation with the underlying bone dimension

After analyzing each parameter individually, a correlation was identified between the increased percentage of the soft tissue thickness and the decreased percentage of the hard tissue dimensions. Although soft and hard tissue alterations vary among patients, it is evident that a higher resorption rate does not necessarily result in greater facial soft tissue thickening (Figure 7).

At 2 mm from reference line, soft tissue mean alteration (thickening) for the smoker group was 1.54 mm (A2'-A2 = 2.60-1.06). In contrast, for the non-smoker group, soft tissue alteration was 0.79 mm (2.19-1.41). Consequently, it can be concluded that soft tissue thickening was more significant in the smoker group. Similarly, at 4 mm from the reference line, soft tissue mean alteration for the smoker group was 1.2 mm

(A2'-A2 = 2.82-1.62). Meanwhile, for the non-smoker group, soft tissue alteration was 0.74 mm (2.41-1.67). Thus, the same conclusion can be drawn for measurements at 4 mm (Figure 8).

The dimensional resorption of hard tissue for the group of smokers was found to be 3.008 mm in width and 1.7 mm in height at 2 mm from the reference line. In contrast, the non-smoker group displayed a hard tissue resorption of 2.619 mm in width and 1.96 mm in height. Consequently, it can be inferred that the dimensional resorption of hard tissue was greater in the smoker group than the non-smoker group (Figure 9).

Soft and hard tissues alterations between male/female subjects

In this study, soft tissue alterations at 2 mm and 4 mm were 0.82 mm and 1.09 mm for males and 0.54 mm and 1.1 mm for females, respectively (Figure 10). Females exhibited more significant soft tissue thickening after twelve weeks. Additionally, hard tissue dimensional resorption at 2 mm was 2.527 mm (width) and 1.897 mm (height) for males, and 2.863 mm (width) and 1.901 mm (height) for females. At 4 mm, hard tissue alteration was 1.868 mm for males and 2.125 mm for females (Figure 11). This highlights gender-related differences, with females experiencing greater soft tissue thickening and alveolar bone resorption.

Soft and hard tissues alterations between the different teeth (incisors, lateral, canine)

At 2 mm, soft tissue alterations were 1.04 mm, 1.1 mm, and 0.6 mm for central incisor, lateral incisor, and canine, respectively. At 4 mm, these alterations were 0.85 mm, 0.96 mm, and 0.69 mm, respectively (Figure 12). The lateral incisor showed the highest soft tissue thickness increase, followed by the central incisor, while the canine exhibited the least thickening.

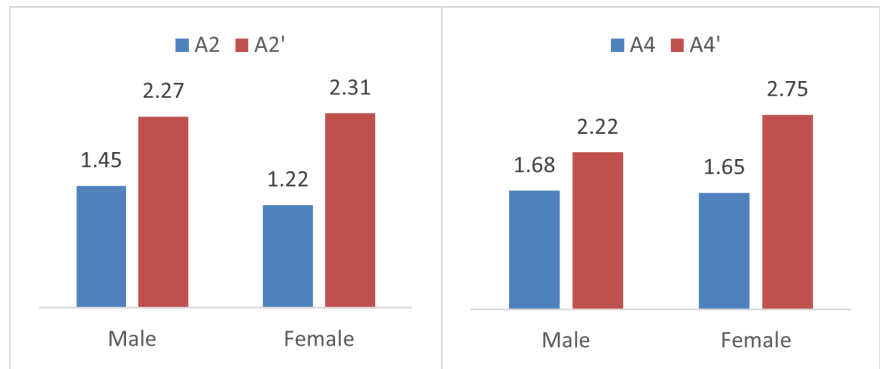


Figure 10. Chart showing the soft tissue mean's alteration between male and female groups at 2 mm and 4 mm

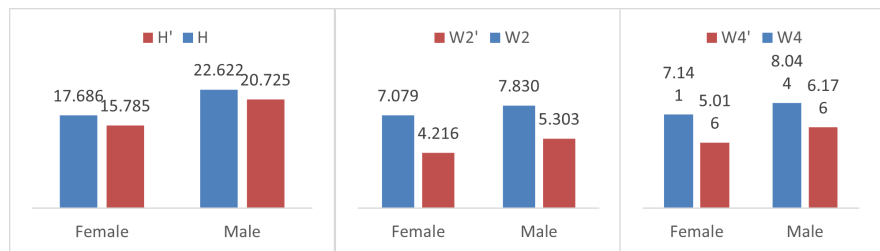


Figure 11. Chart showing the hard tissue mean's height and width alteration between male and female groups at 2 mm and 4 mm

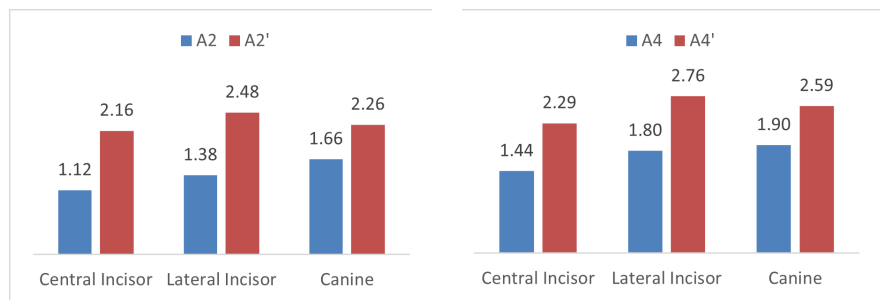


Figure 12. Chart showing the soft tissue mean's alteration between the different teeth at 2 mm and 4 mm

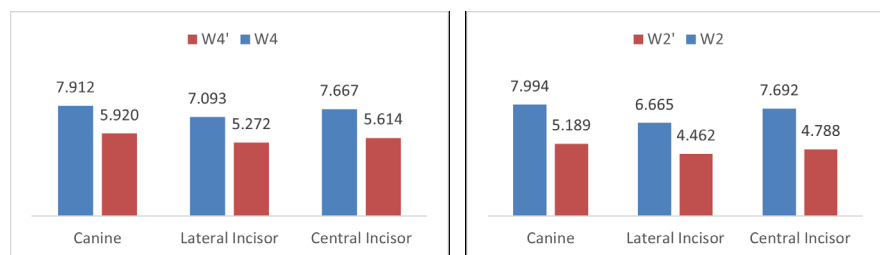


Figure 13. Chart showing the hard tissue mean's width alteration between the different teeth at 2 mm and 4 mm

For hard tissue measurements at 2 mm, width resorption was 2.905 mm, 2.203 mm, and 2.805 mm for central incisor, lateral incisor, and canine, respectively. At 4 mm, width alterations were 2.053 mm, 1.821 mm, and 1.992 mm, respectively

(Figure 13). The central incisor experienced the most significant hard tissue resorption, the canine was second with less resorption, and the lateral incisor showed the least dimensional resorption.

Discussion

The present study assessed changes in hard tissue dimensions and soft tissue thickness in the anterior maxilla twelve weeks following tooth extraction. These parameters were analyzed individually, and subsequently, a correlation between them was explored through analytic comparison. Furthermore, these alterations were examined and compared within distinct groups, including smokers and non-smokers, males and females, and among different teeth (incisors, laterals, and canines).

The results of the current study align with pre-clinical findings related to post-extraction bone resorption [3, 6, 15, 26]. Approximately two-thirds of the affected hard and soft tissues exhibit some degree of resorption within the initial three months following extraction [27, 28]. Research from various studies indicates that the majority of bone loss occurs during the initial six months, with subsequent resorption rate of 0.5 to 1% per year [24]. Covani et al. conducted research that confirmed minimal ridge width variations at 6 months and 1.3 years after extraction [29]. Additionally, the dimensional ridge reduction values from their study are consistent with those of the current study, showing 42.5% bone reduction at 3 months.

In this prospective study, average bone resorption at 2mm exceeded that at 4mm (42.5% > 33%). These findings are consistent with Araujo and Lindhe's studies [5][30], which also demonstrated that alveolar ridge resorption was more pronounced at the coronal aspect of the healing extraction socket and less evident in the middle section.

Regarding the thickness of buccal soft tissue, a 73.5% increase at 2mm from the preoperative facial bone crest and a 51.2% increase at 4mm were observed. These findings diverge significantly from a similar study by V. Chappuis in 2015 [12],

where the percentage of soft tissue thickening was notably higher at 685.7% after 8 weeks of extraction in cases of thin bone phenotype. To address the unexpected high result, substantial increase was due to the total loss of the buccal bone, and in some instances, buccal bone fracture [31]. These factors caused the soft tissue to fill the entire void created by the missing bone volume, resulting in a high percentage of thickening (From 0,7 mm to 5,3 mm).

Additionally, the present study employed a different methodology for measuring soft tissue thickness compared to the other study. V. Chappuis et al. measurements were based on a horizontal reference line connecting the facial and palatal bone wall for standardized measurements. However, this approach can lead to inaccuracies as both buccal and palatal margins undergo resorption during the healing period, causing the reference line's position to vary between pre and post-extraction CBCTs.

To enhance accuracy, the current study utilized superimposition and alignment of the two CBCTs and STLs [32, 33]. This allowed establishing a fixed horizontal reference line from the preoperative facial bone crest, and measurements of facial soft tissue thickness were taken at two and four mm from this reference line in both pre- and post-extraction scenarios. While the results differed with V. Chappuis's study, a comparable percentage increase in soft tissue thickness was noted in Farmer and Darby's study [13]. They observe a minor elevation in soft tissue thickness, ranging from 0.09 to 0.30 mm (approx. 12 to 45%), six to eight weeks after the extraction of a single tooth in the esthetic area.

An important finding in this study was the higher percentage of soft tissue thickening observed in the smoker group in comparison to the non-smoker group. These results seem to contradict the outcomes of numerous studies that have highlighted the detrimental effects of smoking on soft tissue healing [34,

35]. However, this discrepancy can be attributed to the fact that the smoker group exhibited higher underlying bone resorption, which, in turn, triggered more extensive soft tissue remodeling in order to fill the bone gap. To gain a more precise understanding of smoking's impact on soft tissue healing, it is recommended to conduct a study exclusively focused on soft-tissue surgery. This approach would effectively eliminate the potential influence of bone resorption on the assessment of soft tissue healing outcomes.

Another significant outcome of this study is the observation that the female group exhibited a higher percentage of both bone resorption and soft tissue thickening compared to the male group. It is noteworthy to mention that the study's subjects ranged in age from a minimum of 57 and a maximum of 83, classifying them as either older adults or geriatric individuals. These findings align with those of many studies [36, 37], indicating that postmenopausal female subjects tend to experience a higher rate of bone resorption during wound healing when compared to male subjects.

Finally, an intriguing finding in this clinical trial is that central incisors exhibited the highest degree of hard tissue resorption, with canines ranking second and showing less resorption, while lateral incisors displayed the least resorption. Interestingly, there is a scarcity of studies directly comparing the variations in bone resorption among anterior teeth, making it an appealing area for further investigation with a larger sample size. One plausible explanation of the study's results is that the extraction of central incisors can lead to a heightened risk of tissue collapse due to the large size of the extraction socket and the relatively thin bone in the surrounding area. This, in turn, can result in a more prominent depression in the gum tissue and a reduction in the height of the adjacent bone. A similar concept can be applied to lateral incisors and canines.

While superimposition software has become a valuable tool in dentistry, it comes with several limitations that should be considered. One of the primary constraints of superimposition software lies in the accuracy of the registration process. Furthermore, it's important to note that superimposition software can solely analyze the structures visible within the CBCT scans or STL files,

meaning it may not detect changes in soft tissues or alterations occurring in areas outside the scope of the DICOM or STLs. Another limitation pertains to potential measurement errors. Manual measurements are susceptible to human error, encompassing variances in interpretation, discrepancies in the placement of measurement points, and variations in the measurement

tools employed. These errors can lead to inaccurate or inconsistent measurements, ultimately affecting the precision and reliability of the analysis. Lastly, the relatively small sample size can introduce a higher likelihood of random error, which means that the results may not be fully representative on the broader population.

References

1. Udeabor SE, Heselich A, Al-Maawi S, Alqahtani AF, Sader R, Ghanaati S. Current Knowledge on the Healing of the Extraction Socket: A Narrative Review. *Bioengineering (Basel)*. 2023 Sep 29;10(10):1145. doi: 10.3390/bioengineering10101145. PMID: 37892875; PMCID: PMC10604628.
2. Padmasree S, Liji B, Sasikala C, Ajitha SK, Ranukumari A, Shakila R. Delayed and Immediately Loaded Implants Placed in Fresh Extraction Socket - A Clinical and Radiological Study. *J Pharm Bioallied Sci*. 2023 Jul;15(Suppl 1):S471-S476. doi: 10.4103/jpbs.jpbs_550_22. Epub 2023 Jul 5. PMID: 37654397; PMCID: PMC10466519.
3. Saumya J K , Anand N . Changes in Alveolar Bone Dimension after Extraction Sockets and Methods of Ridge Preservation. *Journal of Research in Medical and Dental Science*. 2022; 10(11):191-4.
4. Buser D, Martin W, Belser UC. Optimizing esthetics for implant restorations in the anterior maxilla: anatomic and surgical considerations. *Int J Oral Maxillofac Implants*. 2004;19 Suppl:43–61.
5. Araújo MG, Lindhe J. Dimensional ridge alterations following tooth extraction. An experimental study in the dog. *J Clin Periodontol*. 2005 Feb;32(2):212–8.
6. Tan WL, Wong TLT, Wong MCM, Lang NP. A systematic review of postextraction alveolar hard and soft tissue dimensional changes in humans. *Clin Oral Implants Res*. 2012 Feb;23 Suppl 5:1–21.
7. Masaki C, Nakamoto T, Mukaibo T, Kondo Y, Hosokawa R. Strategies for alveolar ridge reconstruction and preservation for implant therapy. *J Prosthodont Res*. 2015;Oct 59(4):220–8.
8. Naenni N. Regeneration von verlorenem Knochen und verlorenem Zahnfleisch [Influencing Hard and Soft Tissue Changes Following Tooth Extraction]. *Praxis (Bern 1994)*. 2022;111(3):163-167. German. doi: 10.1024/1661-8157/a003798. PMID: 35232257.
9. Gurtner GC, Werner S, Barrandon Y, Longaker MT. Wound repair and regeneration. *Nature*. 2008 May 15;453(7193):314–21.
10. Chappuis V, Engel O, Shahim K, Reyes M, Katsaros C, Buser D. Soft Tissue Alterations in Esthetic Postextraction Sites: A 3-Dimensional Analysis. *J Dent Res*. 2015; Sep1(94)(9_suppl):187S-193S.
11. Pippi R. Post-Surgical Clinical Monitoring of Soft Tissue Wound Healing in Periodontal and Implant Surgery. *Int J Med Sci*. 2017;14(8):721–8.
12. Chappuis V, Engel O, Shahim K, Reyes M, Katsaros C, Buser D. Soft tissue alterations in esthetic postextraction sites: a 3-dimensional analysis. *J Dent Res*. 2015;94:187S-93S
13. Farmer M, Darby I. Ridge dimensional changes following single-tooth extraction in the aesthetic zone. *Clin Oral Implants Res*. 2014; Feb 25(2):272-7.
14. Schropp L, Kostopoulos L, Wenzel A, Isidor F. Clinical and radiographic performance of delayed-immediate single-tooth implant placement associated with peri-implant bone defects. A 2-year prospective, controlled, randomized follow-up report. *J Clin Periodontol*. 2005; May 32(5):480–7.
15. Chappuis, V., Araújo, M.G. and Buser, D. (2017), Clinical relevance of dimensional bone and soft tissue alterations post-extraction in esthetic sites. *Periodontol*. 2000;73:73-83.
16. Cho SC, Froum SJ, Kamer AR, Loomer PM, Romanos G, Demiralp B. Implants in the Anterior Maxilla: Aesthetic Challenges. *Int J Dent*. 2015; 2015:152420. doi: 10.1155/2015/152420. Epub 2015 Jun 11. PMID: 26170836; PMCID: PMC4480940.
17. Ricardo Palacios-Bañuelos, María José Zilleruelo-Pozo, Ludovica Oreglia, Lory Abrahamian, Alvaro Blasi, Prosthetic and soft tissue considerations around anterior maxillary implants. *Dentistry Review*. 2024; 4(2): 100089,ISSN 2772-5596,
18. Darby I, Chen ST, Buser D. Ridge preservation techniques for implant therapy. *Int J Oral Maxillofac Implants*. 2009;24 Suppl:260–71.
19. Quisiguiña Salem C, Ruiz Delgado E, Crespo Reinos PA, Robalino JJ. Alveolar ridge preservation: A review of concepts and controversies. *Natl J Maxillofac Surg*. 2023 May-Aug;14(2):167-176. doi: 10.4103/njms.njms_224_22. Epub 2023 Jul 13. PMID: 37661984; PMCID: PMC10474543.
20. Kalsi, A., Kalsi, J. & Bassi, S. Alveolar ridge preservation: why, when and how. *Br Dent J*. 2019; 227:264–274. DOI: <https://doi.org/10.1038/s41415-019-0647-2>
21. Mardas N, Macbeth N, Donos N, Jung RE, Zuercher AN. Is alveolar ridge preservation an overtreatment? *Periodontol 2000*. 2023; Oct 93(1):289-308. doi: 10.1111/prd.12508. Epub 2023 Aug 25. PMID: 37622682.
22. Thoma D, Mühlemann S, Jung R. Critical soft-tissue dimensions with dental implants and treatment concepts. *Periodontol 2000*. 2014; Oct 1;66.

23. X. J. Chen, L. Xu, H. X. Wang, F. Wang, Q. Wang, and R. Kikinis, Development of a surgical navigation system based on 3D slicer for intraoperative implant placement surgery. *Medical Engineering & Physics*. 2017; 41:81–89.
24. Lin HK, Pan YH, Salamanca E, Lin YT, Chang WJ. Prevention of Bone Resorption by HA/ β -TCP + Collagen Composite after Tooth Extraction: A Case Series. *Int J Environ Res Public Health*. 2019; Dec 16(23):461-6.
25. Getúlio Batista de Oliveira, Iêda Margarida Cruzeiro Rebello, Kátia Montanha Andrade, Nara Santos Araujo, Jean Nunes dos Santos, Patricia Ramos Cury. Evaluation of alveolar process resorption after tooth extraction using the socket shield technique without immediate installation of implants: a randomised controlled clinical trial, *British Journal of Oral and Maxillofacial Surgery*. 2021; 59(10):1227-32, ISSN 0266-4356.
26. Weijden, Fridus & Dell'Acqua, Federico & Slot, Dagmar. (2009). Alveolar bone dimensional changes of post-extraction sockets in humans: A systematic review. *Journal of clinical periodontology*. 2009; 36:48-58. Doi 10.1111/j.1600-051X.2009.01482.x
27. Pagni G, Pellegrini G, Giannobile WV, Rasperini G. Postextraction alveolar ridge preservation: biological basis and treatments. *Int J Dent*. 2012;151030. doi: 10.1155/2012/151030. Epub 2012 Jun 12. PMID: 22737169; PMCID: PMC3378971.
28. Covani U, Ricci M, Bozzolo G, Mangano F, Zini A, Barone A. Analysis of the pattern of the alveolar ridge remodelling following single tooth extraction. *Clin Oral Implants Res*. 2011; Aug 22(8):820-5. doi: 10.1111/j.1600-0501.2010.02060.x. Epub 2010 Dec 29. PMID: 21198897.
29. Araújo MG, Dias DR, Matarazzo F. Anatomical characteristics of the alveolar process and basal bone that have an effect on socket healing. *Periodontol* 2000. 2023; 93: 277-88. doi:10.1111/prd.12506
30. Mehta H, Shah S. Management of Buccal Gap and Resorption of Buccal Plate in Immediate Implant Placement: A Clinical Case Report. *J Int Oral Health*. 2015;7(Suppl 1):72-5. PMID: 26225110; PMCID: PMC4516068.
31. Falih MY, Majeed MA. Trueness and Precision of Eight Intraoral Scanners with Different Finishing Line Designs: A Comparative In Vitro Study. *Eur J Dent*. 2023; Oct 17(4):1056-1064. doi: 10.1055/s-0042-1757568. Epub 2022 Dec 13. PMID: 36513335; PMCID: PMC10756783.
32. Katsarov, S. (2020), Contemporary assessment of the accuracy of merging DICOM and STL files for the purpose of guided implant placement. *Clin Oral Impl Res*. 2020; 31:282-282.
33. McDaniel JC, Browning KK. Smoking, Chronic Wound Healing, and Implications for Evidence-Based Practice. *J Wound Ostomy Cont Nurs Off Publ Wound Ostomy Cont Nurses Soc WOCN*. 2014; 41(5):415-E2.
34. Silverstein P. Smoking and wound healing. *Am J Med*. 1992 Jul 15;93(1):S22–4.
35. Horng HC, Chang WH, Yeh CC, Huang BS, Chang CP, Chen YJ, Tsui KH, Wang PH. Estrogen Effects on Wound Healing. *Int J Mol Sci*. 2017 Nov 3;18(11):2325. doi: 10.3390/ijms18112325. PMID: 29099810; PMCID: PMC5713294.
36. Melissa Calvin, Oestrogens and wound healing, *Maturitas*. 2000;34(3):195-210, ISSN 0378-5122.
37. Taguchi, A., Kamimura, M., Nakamura, Y. et al. Delayed wound healing after tooth extraction and self-reported kyphosis in Japanese men and women. *Sci Rep*. 2016;6:36309 .